

ANTINEOPLASTIC EFFECT OF NICLOSAMIDE ON EXPERIMENTALLY INDUCED COLORECTAL CANCER IN RATS

SAMAR S. KHALAF¹; SARY K.H. ABD-ELGHAFAR^{1,2} AND MARWA F. ALI¹

¹ Department of Pathology and Clinical Pathology, Faculty of Vet. Med., Assiut University, Assiut, Egypt.

² Department of Pathology and Clinical Pathology, School of Vet. Med., Badr University in Assiut, Assiut, Egypt

Received: 15 April 2024; **Accepted:** 30 May 2024

ABSTRACT

An essential research tool for studying colorectal cancer (CRC) is the use of 1, 2-dimethylhydrazine (DMH) as an animal model of colorectal carcinogenesis. Niclosamide (Nic), an oral anthelmintic drug, has been identified as a possible anticancer agent. The purpose of this research was to determine the potential antineoplastic effect of Nic on induced colorectal carcinogenesis. Five groups from thirty-five albino rats were created. Group I was given a vehicle for four weeks. Group II was administered Nic I/P at a dose of 20 mg/kg b.w. daily for four weeks. Group III was administered DMH S/C at a dose of 20 mg/kg b.w. twice weekly for four weeks. Group IV received DMH in the same manner as Group III, and following a week from the last DMH injection, they were given daily doses of 20 mg/kg b.w. of Nic I/P until the experiment concluded. Group V received for four weeks both DMH S/C at a dose of 20 mg/kg b.w. twice weekly and Nic I/P at a dose of 20 mg/kg b.w. daily. Upon completion of the experiment, which lasted 12 weeks, rats were sacrificed for sampling. Colons of rats in all groups were collected for aberrant crypt foci (ACF) counting using 0.2% methylene blue. Then tissue specimens were taken for histopathological examination. According to the topographical features of colon preneoplastic lesions, we found that group III had more ACF count and crypt multiplicity, whereas groups IV and V had a significantly lower number. Microscopically, rats receiving DMH exhibited moderate to severe dysplastic changes. These changes were significantly decreased in both Nic-treated groups, however, Group V showed the best improvement. These results indicated the obvious protective effect of Nic against ACF progression.

Keywords: Colorectal carcinogenesis; DMH; Niclosamide; ACF; histopathological changes.

INTRODUCTION

Rectal and colon cancers are anatomically similar, thus in many epidemiological studies they are referred to as

Corresponding author: Samar S. Khalaf

E-mail address: samar_soliman@vet.aun.edu.eg

Present address: Department of Pathology and Clinical Pathology, Faculty of Vet. Med., Assiut University

colorectal cancer (CRC) (Thyne, 2020). CRC is a malignant tumour originating from the mucosal-lining colonic epithelial cells. It is the second-most lethal and third-most prevalent type of cancer globally (Miller *et al.*, 2016). Even though colon cancer mortality has decreased recently, the disease's incidence is still increasing (Siegel *et al.*, 2014; Zahid and Young 2016). Numerous risk factors have been linked to CRC

development, including inflammatory bowel illness, first-degree relatives' history of colorectal polyps or colorectal cancer, advancing age, certain hereditary syndromes (familial adenomatous polyposis) "FAP" and Lynch syndrome (Hereditary non-polyposis colorectal cancer) "HNPCC" and environmental risk factors such as a rise in body mass index (obesity), and dietary habits (low-fiber and high fat-diet) (Johnson *et al.*, 2013; Norat *et al.*, 2014). Over the past decades, numerous murine models of colon carcinogenesis have been developed. The most commonly utilized model of chemically induced colon carcinogenesis is the 1,2-dimethylhydrazine (DMH) model. The electrophilic methyl diazonium ion produced by the metabolism of this carcinogen eventually leads to the creation of carbonium ion, which methylates DNA and other biomolecules of colon epithelial cells (Hussein *et al.*, 2013), hence causing procarcinogenic events brought on by mutations, inflammation and tumour promotion (Siddique *et al.*, 2017; Senedese *et al.*, 2019). It is believed that aberrant crypt foci (ACF), which are preneoplastic lesions, are biomarkers of colon carcinogenesis that identify the early stages of the disease before tumours develop. Their existence can therefore be utilized as the primary endpoint in short-term studies when investigating pharmacological or dietary approaches for colon cancer prevention (Strimbu & Tavel, 2010). Under a microscope at low magnification, they can be distinguished from neighboring crypts by their larger size, somewhat elevated from the surrounding normal mucosa, oval-shaped slit-like opening, and stained darker due to thicker epithelium (Chiou *et al.*, 2010). Histologically, ACF are known as colorectal intraepithelial lesions (Boivin *et al.*, 2003; Tanaka, 2009). The Repurposing Drugs in Oncology (ReDO) project has identified a variety of antiparasitic medications as high-potential agents (Hu *et al.*, 2013). Niclosamide (Nic) is one of these medications, as reported by Wang *et al.* (2009). Niclosamide (Arend *et al.*, 2016) which has several systematic chemical names

such as (5-chloro-N-(2-chloro-4-nitrophenyl)-2-hydroxybenzamide) is an oral anthelmintic drug that has been approved by the United States Food and Drug Administration (US FDA) for treating most tapeworm infections in human and livestock for approximately 50 years (Andrews *et al.*, 1982; Al-Hadiya 2005). Niclosamide has been identified as a possible anticancer agent that targets molecular pathways involved in carcinogenesis, progression and metastasis of CRC in both *in vivo* and *in vitro* models (Li *et al.*, 2014; Satoh *et al.*, 2016), including the Wnt/ β -catenin (Londono-Joshi *et al.*, 2014), mTORC1 (Baldi *et al.*, 2009; Wieland *et al.*, 2013), Stat3 (You *et al.*, 2014; Arend *et al.*, 2016), NF- κ B (Jin *et al.*, 2010; Wieland *et al.*, 2013), and Notch signaling pathways (Wang *et al.*, 2009; Wieland *et al.*, 2013). Many cancer cells have either mutations, overexpression or constitutive activation of the signaling molecules involved in these pathways (Li *et al.*, 2014).

Therefore, our study was conducted to confirm and evaluate the anticancer effect of Nic on colon carcinogenesis in a DMH-induced colon cancer animal model and to demonstrate Nic as a viable therapeutic option for colon cancer in clinical trials.

MATERIALS AND METHODS:

Materials:

Chemicals:

- 1, 2-dimethylhydrazine (DMH), Niclosamide (5-chloro-N-(2-chloro-4-nitrophenyl)-2-hydroxybenzamide), Dimethyl sulfoxide (DMSO), and polyethylene glycol 400 (PEG 400) were purchased from Sigma Chemical Company (St Louis, MO, USA).
- Immediately before usage, DMH was dissolved in a 0.9% NaCl solution, and 1 mM NaOH was used to adjust the pH to 6.5 (Sugihara *et al.*, 2017).
- Niclosamide was prepared weekly in 40% (v/v) polyethylene glycol 400 containing 5% (v/v) DMSO (Yang *et al.*, 2016).

Animals:

Male albino rats ($n= 35$) aged 6–8 weeks with body weights of 130 ± 20 gm were purchased from the Animal House of the Faculty of Veterinary Medicine at Assiut University. Healthy circumstances were maintained for them in metal cages, with a temperature of $22^{\circ}\text{C} \pm 2^{\circ}\text{C}$ and a humidity of $50\% \pm 5\%$. They had unrestricted access to food and water and were kept in a cycle of natural light and darkness. The animals were cared for and treated in accordance with the ethical standards for experimental animals as set forth by the Animal House of Assiut University. This study has been approved by the ethical committee of the Faculty of Veterinary Medicine, Assiut University, Assiut, Egypt, according to the OLE standards for the use of animals in research under No. 06/2024/0155.

Methods:

Induction of colon carcinogenesis:

The rats were administrated 20 mg of DMH per kg of body weight (Okda *et al.*, 2014). Just prior to usage, DMH was weighed and dissolved in 0.9% NaCl. Each rat was given 0.5 ml of the dissolved DMH (El-Deek *et al.*, 2022). DMH was subcutaneously injected twice weekly for four weeks (Okda *et al.*, 2014).

Experimental Design:

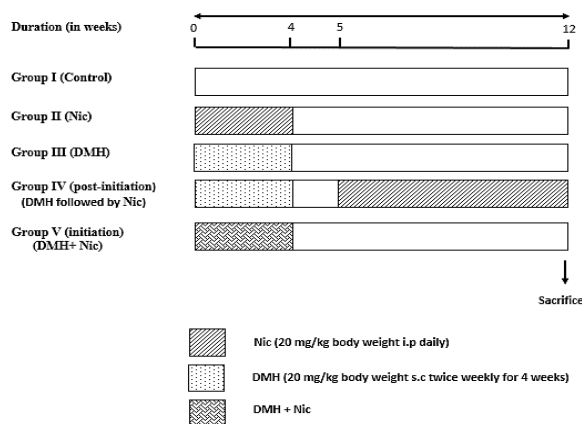
Rats in each group were weighed once a week in order to determine the dosage of Nic and DMH. The following design was used to randomly divide the rats into five groups:

- **Group I (Control)** ($n=7$): Rats were

subcutaneously injected with 0.5 ml of 0.9% NaCl (the DMH vehicle) twice weekly for four weeks.

- **Group II (Nic group)** ($n=7$): Rats received intraperitoneal injections of Nic at a dose of 20 mg/kg b.w. per day for the first 4 weeks of the experiment (Osada *et al.*, 2011; Moskaleva *et al.*, 2015; Sugihara *et al.*, 2017; Luo *et al.*, 2019).
- **Group III (DMH group)** ($n=7$): Rats were subcutaneously injected with DMH at a dose of 20 mg/kg b.w. twice weekly for the first 4 weeks, and then rats were kept without any treatment until the end of the experiment.
- **Group IV (post-initiation) (DMH followed by Nic group)** ($n=7$): Rats were subcutaneously injected with DMH at a dose of 20 mg/kg b.w. twice weekly for the first 4 weeks. After 1 week of the last DMH injection, they were given daily doses of 20 mg/kg b.w. of Nic intraperitoneally until the end of the experiment.
- **Group V (initiation) (DMH + Nic group)** ($n=7$): Rats were subcutaneously injected with DMH at a dose of 20 mg/kg b.w. twice weekly in conjunction with intraperitoneal injections of Nic at a dose of 20 mg/kg b.w. daily for the first 4 weeks. They were then left without any treatment until the end of the experiment.

At the end of the study after 12 weeks, rats were sacrificed for sampling.



Determination of aberrant crypt foci (ACF) in whole mount colon:

Immediately after the rats were sacrificed, the colons were extracted, flushed with cold saline (0.9 % NaCl) to eliminate any fecal contents, and opened along the longitudinal median from the anus to the caecum. Following the excision of the cecum, the remaining colon was divided into three segments, each measuring eight centimeters. These segments were named the proximal colon, which was located next to the cecum; the middle colon; and the distal colon, which was located next to the rectum. Since the middle and distal colons contained the majority of the AFC (Rodrigues *et al.*, 2002; Perše & Cerar, 2011), they were divided into small sections and fixed flat in Styrofoam using 10% buffered formalin, leaving the mucosal surface exposed for 24 hours. Following fixation, colon segments were washed and stained for 15 to 30 minutes at room temperature using a 0.2 % methylene blue solution in PBS (Verma & Shukla, 2013). Then, they were placed on a glass slide with the luminal side facing up and examined under a light microscope at 4 and 10 × magnifications (Ochiai *et al.*, 2005; Sugihara *et al.*, 2017). The elliptical-shaped opening, darker staining, larger size and slight elevation from the surrounding normal mucosa allowed ACF to be distinguished from neighboring crypts (Rodrigues *et al.*, 2002; Chiou *et al.*, 2010).

Scoring of ACF:

Each rat in each of the experimental groups had their total number of ACFs and ACs calculated (Bird 1998), and each

rat's crypt multiplicity (AC/ACF), which indicated how many crypts were in each focus, was then recorded (Balaji *et al.*, 2015).

Histopathological examination:

Following ACF recording, the 10% buffered formalin-fixed colon segments were processed and sectioned perpendicular to the muscularis mucosa at a thickness of 4-6 µm to visualize the entire length of the crypts, and stained with hematoxylin and eosin (H&E) according to conventional procedures (Bancroft & Gamble, 2008; Suvarna *et al.*, 2018). The slides were inspected using a light microscope at 100 and 400x magnification to determine the type of ACF through histological examination (Verma & Shukla, 2013; Muthu *et al.*, 2016). In accordance with Siu *et al.*, (1997), the material was also examined for the existence of dysplasia and its degree

Histopathological scoring:

Six random fields (400x magnification) were examined in seven rats from each group to score all the microscopic lesions of the H & E-stained colon sections using a semi-quantitative scale from 0 to 3 based on the following histological criteria described in previous reports (Thorup, 1997; Paulsen *et al.*, 2005; Lu *et al.*, 2008):

The histopathological scores (0 = no lesions / normal crypts), (1 = hyperplastic or non-dysplastic crypts), (2 = mild to moderate dysplastic crypts) and (3= moderate to severe dysplastic crypts) were shown in Table 1.

Table 1 : The histopathological scores of aberrant crypts.

Crypts	Score	Description
For normal crypts:	0	It indicates the normal colon histology, which is identified by tightly packed, straight tubular crypts that reach down to the muscularis mucosa and contain plenty of goblet cells.
For hyperplastic or non-dysplastic crypts:	1	It can be identified by slightly dilated crypts and hypercellularity of slender, normal, uniform epithelium with enlarged nuclei, or by being sometimes crowded without stratification (Hamilton <i>et al.</i> , 2000; Day <i>et al.</i> , 2003; Cho <i>et al.</i> , 2008). Otherwise, goblet cells appear normal with small, basally oriented nuclei and apical mucus localization.
For Mild to moderate dysplastic crypts	2	It is identified by slightly basophilic, enlarged and elongated crypts with increased crypt height. Cells exhibiting hypercellularity have dark, elongated (cigar-shaped) nuclei and focal nuclear stratification (between 1 and 1.5 nuclear heights) while maintaining their polarity. The cytoplasm of cells is less abundant than normal and contains less mucus. The mucus is extracellular in the crypt lumen or enclosed in tiny vacuoles (slightly fewer goblet cells).
For Moderate to severe dysplastic crypts	3	It is indicated by strongly basophilic crypts and increased crypt height. Elongated cells that exhibit hypercellularity and a lot of basophilic cytoplasm. Goblet cells are either significantly reduced or completely lost, resulting in very scant or absent intracellular mucus. Nuclear polarity is often lost. Larger rounded, or oval vesiculated nuclei, occasionally with noticeable nucleoli. In some areas, there is extensive nuclear stratification, which consists of two or more layers with numerous mitoses. There are a few nuclei that seem to be pleomorphic. Increased nuclear-to-cytoplasmic ratios and nuclear hyperchromasia are seen, and they extend to the mucosal surface (Hamilton <i>et al.</i> , 2000; Day <i>et al.</i> , 2003; Cho <i>et al.</i> , 2008).

Since the crypts inspected in each field had different degrees of dysplasia; the crypt with the highest degree of dysplasia was used to determine the score.

Statistical analysis:

Statistical analyses were performed using the Statistical Package for Social Science program SPSS (version 16) software. The data are displayed as the mean \pm SE. One-way analysis of variance (one-way ANOVA) was used to compare the data among the different experimental groups, and Turkey's multiple comparison method was then used to compare the means of the different groups. The Prism program, version 5.01 (Graph Pad Prism), was used to create the graphs, and the statistical

significance level of acceptance was $P < 0.05$.

RESULTS

Effect of Nic and DMH on ACF formation and crypt multiplicity:

The effect of Nic and DMH on the ACF occurrence, total number of ACFs, and crypt multiplicity (AC/ACF) were shown in Table 2 and Graph 1. The colonic tissue sections stained with Methylene blue showed the highest incidence of aberrant colonic crypt formation with unique morphology in the DMH group (349 ± 36) compared with colorectal tissue of the normal control group and Nic group (0 ± 0 , $p < 0.001$). Niclosamide-administered rats after DMH treatment (group IV) exhibited a significant

decrease in the total number of ACF/rat (36 ± 15.8) when compared to rats treated with DMH (group III) (349 ± 36 , $p < 0.001$). While the total number of ACF/rat significantly decreased in rats administered Nic with DMH treatment (group V) (17.6 ± 10 , $p < 0.01$) when compared with Nic-administered rats after DMH treatment (group IV). The number of ACs was significantly reduced in group IV (276.6 ± 48.8) as compared to the DMH group (1684.6 ± 128 , $p < 0.001$), but increased significantly when compared to group V (45.7 ± 11.6 , $p < 0.05$). The number of AC/ACF (multiplicity) was 3.2 ± 0.1 in both groups IV and V, which was significantly lower as compared to that of 5 ± 0.5 in DMH (group III, $p < 0.001$). Group V showed a more significant reduction in both ACF and ACs (17.6 ± 10 , 45.7 ± 11.6), respectively, as compared with DMH followed by the Nic group (group IV) (36 ± 15.8 , 276.6 ± 48.8 , $p < 0.01$).

Representative photographs showing a topographical view of ACF are also illustrated in Figs. 1 and 2. There was no incidence of ACF observed in the control and Nic treated group (Fig. 1 A–B), while the incidence of ACF as well as crypt multiplicity was 100 % in the DMH-treated group compared with rats in the control group. These lesions were characterized by larger, denser crypts with thick epithelial lining, slightly elevated and had slit-shaped openings (Fig. 2 A–B). Administration of Nic after DMH treatment showed a significant decrease in the number of ACF and their multiplicity as compared to the DMH-treated group (Fig. 2 C–D). A more pronounced effect on ACF reduction and crypt multiplicity was observed in the Nic-administrated rats with DMH (Fig. 2 E–F).

Histopathological findings:

The difference among groups is illustrated in Table 3 and Graph 2. There was a significant decrease in the degree of dysplasia in both Nic-treated groups (group IV and V) as compared to the DMH group ($p < 0.001$). The degree of dysplasia increased in group IV compared to group V ($p < 0.05$).

Rats in both the control and Nic groups showed no signs of abnormalities with normal mucosal and submucosal layers (Fig. 3 A–B). On the other hand, DMH-treated rats exhibited moderate to severe dysplastic changes in the crypt epithelium. The dysplastic crypts were associated with lymphoid follicles in 90% of sections. Crypts with mild to moderate dysplasia were found in 2 rats out of 7. Dysplastic changes were indicated by hypercellularity and focal stratification of vesicular nuclei, with numerous mitotic figures limited to the lower half of the crypts and some apoptotic cells (Fig. 4A). Crypts with double-branched glands were also observed, which were lined with epithelium characterized by rounded to elongated hyperchromatic nuclei with depleted mucin that was contained in small vacuoles or located extracellularly in the crypt lumen (Fig. 4B). Five rats out of 7 showed severe dysplasia. Two of them showed serrated adenoma that was characterized by dilated and serrated crypts (saw-tooth structure) and intact muscularis mucosa (Fig. 4C). These crypts had large, hyperchromatic, elongated nuclei (displaying a pencillate pattern) arranged along the basement membrane in a stratified manner. There was loss of polarity, high nuclear/cytoplasmic ratio, increased basophilia of the cytoplasm, and the goblet cells were completely absent (Fig. 4D).

The administration of Nic after DMH (group IV) showed a significant decrease in the degree of dysplasia, which was mild to moderate. This was observed in 2 rats out of 7 and was characterized by slight dilatation of crypts with basally oriented elongated hyperchromatic nuclei and mild mucin depletion present in small vacuoles. There were numerous mitoses that may extend to the upper half of the crypts (Fig. 5 A– B). Hyperplastic crypts were observed in 5 rats out of 7 in the same group. In group V, where Nic was administered along with DMH treatment, the dysplastic changes were rarely observed as compared to groups III and IV, and the degree was mild to moderate, which was found in one rat out of 7. The

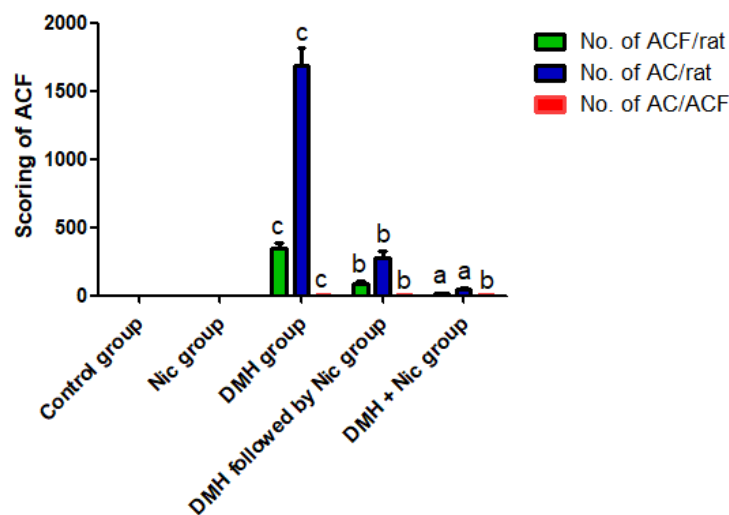
hyperplastic lesions were found in 3 rats out of 7. The remaining rats (3/7) exhibited more or less normal colonic mucosal crypts with goblet cells filled with mucin and basally

oriented vesicular uniform ovoid nuclei with no crowding despite their presence above lymphoid aggregates (Fig. 5 C- D).

Table 2: Effect of Nic and DMH on ACF formation, AC count and crypt multiplicity

Groups	No. of rats	No. of ACF/rat	No. of AC/rat	NO. of AC/ACF
Control group	7	0 ± 0 ^a	0 ± 0 ^a	0 ± 0 ^a
Nic group	7	0 ± 0 ^a	0 ± 0 ^a	0 ± 0 ^a
DMH group	7	349 ± 36 ^c	1684.6 ± 128 ^c	5 ± 0.5 ^c
DMH followed by Nic group	7	36 ± 15.8 ^b	276.6 ± 48.8 ^b	3.2 ± 0.1 ^b
DMH + Nic group	7	17.6 ± 10 ^a	45.7 ± 11.6 ^a	3.2 ± 0.1 ^b

Abbreviations: Nic = niclosamide, DMH =1, 2-dimethylhydrazine, ACF = aberrant crypt foci, AC = aberrant crypt, AC/ACF = crypt multiplicity. Data is presented as means ± SE of 7 rats in each group. Groups not sharing a common superscript letter (a–c) differ significantly.



Graph 1. Abbreviations: Nic = niclosamide, DMH =1, 2-dimethylhydrazine, ACF = aberrant crypt foci, AC = aberrant crypt, AC/ACF = crypt multiplicity. Data is presented as means ± SE of 7 rats in each group. Groups not sharing a common superscript letter (a–c) differ significantly.

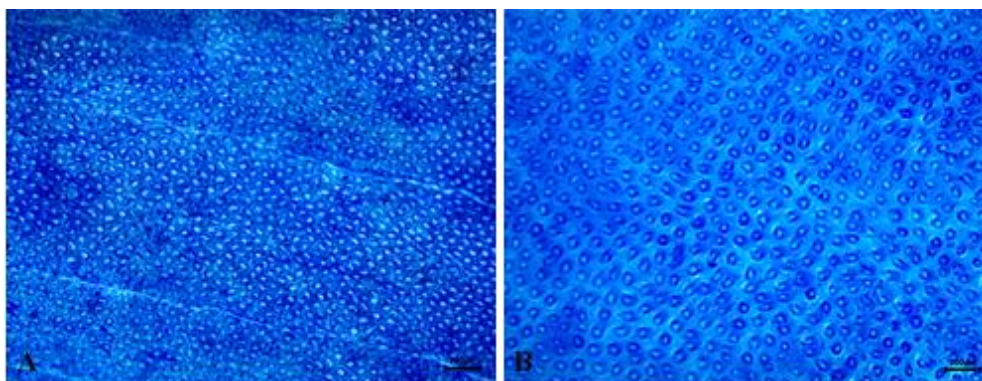


Figure 1: Topographic view of the colon after mucosal staining with methylene blue showing normal crypts of control group (A) and Nic alone (B) treated animals (Bar=200).

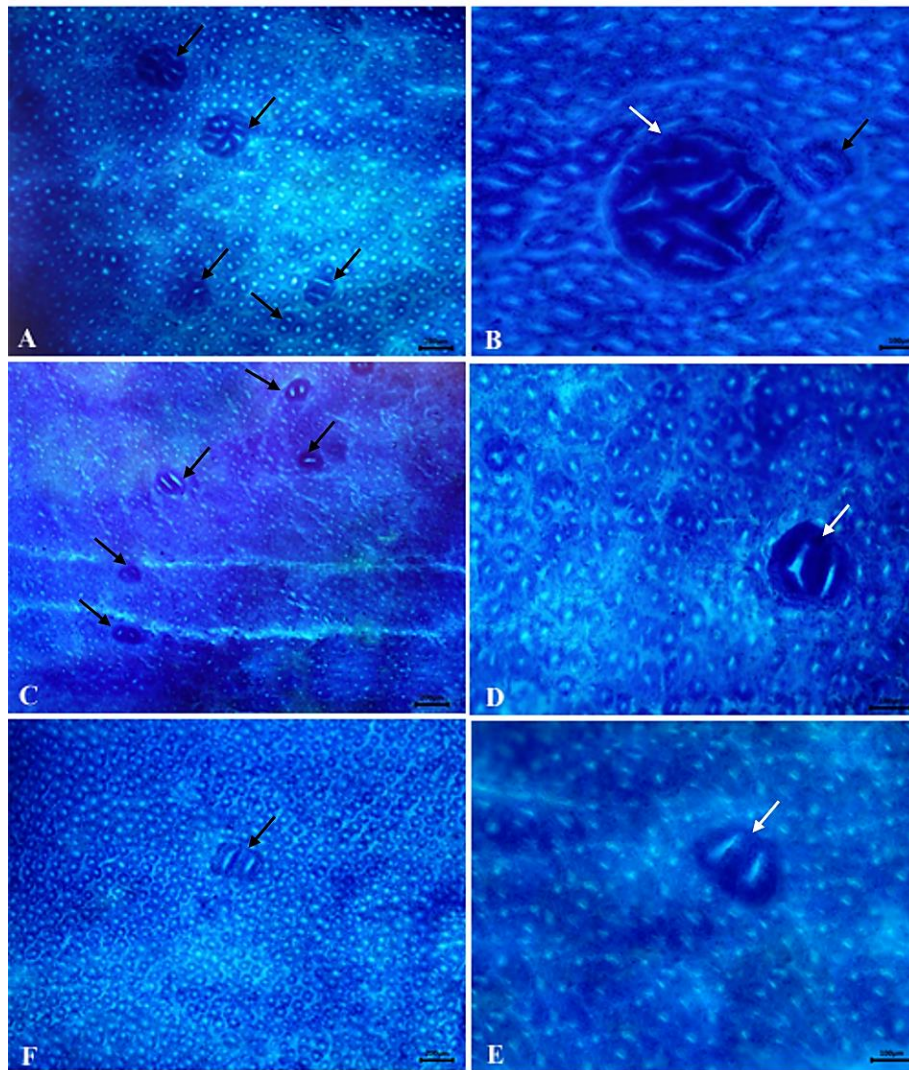
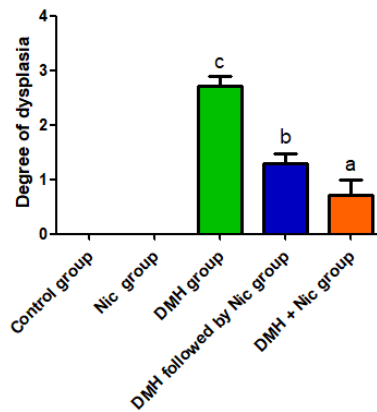


Figure 2: Topographic view of the colons of DMH- administrated rats (A-B), DMH followed by Nic treated rats (C-D) and DMH + Nic treated rats (E-F). A: low power field showing five ACF with crypt multiplicity ranging from 2–8 AC/focus (black arrows) (bar=200). B: high power field showing a large focus with 9 AC/focus (white arrow) and a small focus with 2 AC/focus (black arrow) (bar= 100). The lesion was slightly elevated, darkly stained, and had larger crypts with slit-shaped openings. C: low power field showing five small foci with low crypt multiplicity (1-2 AC/focus) (black arrows) (bar=200). D: high power field showing a small focus with 2 AC/focus (white arrow) (bar=100). F: low power field showing single doublet ACF (black arrows) (bar=200). E: high power field showing a small focus with 2 AC/focus (white arrow) (bar=100).

Table 3: The degree of dysplasia in different groups.

Groups	No. of rats	Degree of dysplasia
Control group	7	0 ± 0 ^a
Nic group	7	0 ± 0 ^a
DMH group	7	2.7 ± 0.2 ^c
DMH followed by Nic group	7	1.3 ± 0.2 ^b
DMH + Nic group	7	0.7 ± 0.3 ^b

Abbreviations: Nic = niclosamide, DMH=1, 2-dimethylhydrazine. All values displayed are mean ± SE. The groups that don't have the same superscript are significantly different.



Graph 2: Abbreviations: Nic = niclosamide, DMH = 1, 2-dimethylhydrazine. All values displayed are mean ± SE. The groups that don't have the same superscript are significantly different.

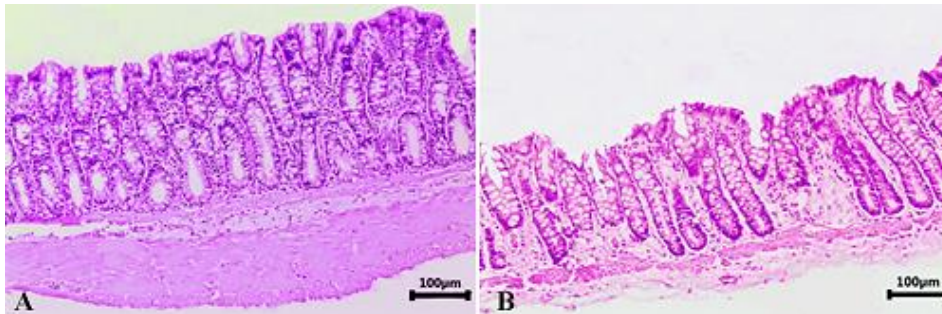


Figure 3: The colon histology of untreated control rats (A) and rats that were given niclosamide (B) exhibiting straight, closely spaced, typical tubular crypts that extend to the muscularis mucosa and are rich in goblet cells (bar=100).

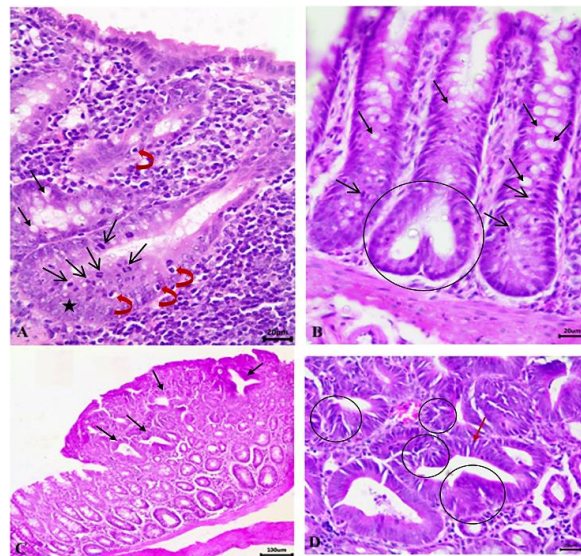


Figure 4: The colonic mucosa of DMH administrated rats shows mild to moderate dysplastic aberrant crypts (A-B). (A) The crypts show numerous mitoses limited to the lower half of the crypts (open black arrows) with slight mucin depletion (black arrows), apoptotic cells (curved red arrows) and focal stratification of vesicular nuclei (asterisk). (B) Some crypts have double-branching glands (crypt fission) (circle) (bar=20). (C) Traditional serrated adenoma with dilated and serrated crypts [saw-tooth structure] (black arrows) and intact Muscularis mucosa (bar=100). (D) A high-power view of dilated and serrated crypts with elongated hyperchromatic nuclei (displaying a pencillate pattern) (red arrow). The crypts show severe mucin depletion and stratification of nuclei (circles) (bar=20).

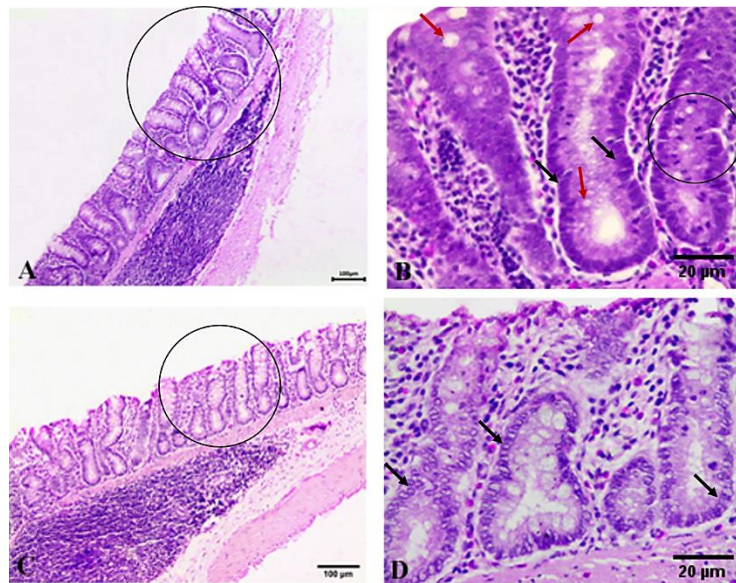


Figure 5: Histopathology of colons of DMH followed by Nic treated group (A, B) and DMH + Nic treated group (C, D). (A) Enlarged crypts above lymphoid follicles with a mild to moderate degree of dysplasia have slight mucin depletion and slight dilatation (circle) (bar=100). (B) high-power view showing basally oriented elongated hyperchromatic nuclei (black arrows), numerous mitoses may extend to the upper half of crypts (circle), and mucin is contained in small vacuoles (red arrows) (bar =20). (C) More or less normal crypts (circle) above lymphoid follicles with goblet cells filled with mucin (bar=100). (D) A high-power view shows basally oriented vesicular uniform ovoid nuclei (black arrows) with no crowding (bar=20).

DISCUSSION

One of the most serious illnesses and a major global cause of cancer-related mortality is colorectal cancer (Hossain *et al.*, 2022). Carcinogenesis is a multistep process, beginning with initiation followed by promotion and progression (Karthikkumar *et al.*, 2015). Since human colon cancer is caused by a complex interplay of genetic and epigenetic events, DMH was utilized as a carcinogen in this study, which mimics the pathology of colon cancer in humans and does not only rely on extrapolating findings from *in vitro* models (Femia *et al.*, 2010; Balaji *et al.*, 2014). DMH-induced colon cancer develops through a sequence of pathological changes, from detached microscopic ACF mucosal lesions to malignant tumours (Muthu *et al.*, 2016).

Aberrant crypt foci (ACF) are heterogeneous group of preneoplastic lesions of the adenoma-carcinoma sequence. They are identified in whole mounts of colon stained with methylene blue by abnormally shaped

clusters of colonic crypts that begin as a single, bigger crypt with a thicker epithelial lining than typical crypts and then expand into larger clusters (Fayazfar *et al.*, 2021). Numerous researchers have employed ACF as an early biomarker of colon carcinogenesis to assess the efficacy of different chemopreventive agents in a short-term model (Balaji *et al.*, 2015; Rehman *et al.*, 2018). According to Hirose *et al.* (2003), their emergence in rats with induced colon cancer indicates the initiation of colorectal carcinogenesis, and an increase in their number and crypt multiplicity correlates with the promotion and progression of carcinogenesis. Furthermore, their numbers and the multiplicities (crowding of crypts) are more indicative of malignant transformation and directly correspond with the risk of colon cancer, as in high-risk human cases (Wargovich *et al.*, 2010). According to early research, ACF-inhibiting agents may also enhance the anticarcinogenicity in CRC models induced by carcinogens (Muthu *et al.*, 2013). Hence, Nic was tested to find its anti-cancer efficacy at morphological and

histopathological levels, which have previously shown anti-colon cancer activity *in vitro* and in xenograft tumour cells *in vivo* (Li *et al.*, 2014; Satoh *et al.*, 2016; Kang *et al.*, 2021).

Niclosamide (Arend *et al.*, 2016) is an oral anthelmintic drug that has been approved by the US FDA for treating most tapeworm infections in human and livestock for approximately 50 years (Andrews *et al.*, 1982; Al-Hadiya 2005; Panahi *et al.*, 2022). The Repurposing Drugs in Oncology (ReDO) project has identified a variety of antiparasitic medications as high-potential agents (Hu *et al.*, 2013). Niclosamide is one of these medications, as reported by Wang *et al.* (2009).

In our study, we evaluated the effect of Nic on colon carcinogenesis in rats during the initiation and post-initiation (promotion) phases of colon cancer development. Taking into account a major endpoint of this study, the enumeration of the colonic morphological marker ACF. Crypt multiplicity and the total number of ACs were also calculated in addition to estimation of histopathological alterations. DMH alone treated rats had a noticeably greater incidence of ACF in their middle and distal colons (Aranganathan and Nalini 2013; Sharma *et al.*, 2017). These findings are in line with earlier research, which also indicated that the distal colon had a higher incidence of colon cancer than the proximal colon (Liu and Xu 2008; Balaji *et al.*, 2015).

Administration of Nic to DMH treated rats suppressed the ACF number, development and its multiplicity in contrast to what was found in the DMH group. Furthermore, Nic treatment along with DMH at the beginning of the experiment gave the most effective results (group V) (initiation stage) when compared with group IV that was treated with Nic after the DMH induction period (post-initiation stage). The suppressive effect of Nic against ACF induced by DMH is in line with what was found in a prior study that addressed Nic's ability to suppress early

events of colon carcinogenesis (Sayed *et al.*, 2023). That could be explained by Nic's possible antioxidant impact on the colon carcinogenesis induced by chemical carcinogens. It also has antiproliferative action in many human CRC cell lines (Kang *et al.*, 2021). Consequently, our findings implied that Nic impedes colonic ACF development and prevents the conversion of preneoplasia to malignant neoplasia.

The histopathological observations in this study revealed no anomalies in crypt morphology and architecture in the control and Nic groups. However, there was a range of pathological abnormalities in the colon tissue after administration of DMH, including aberrant crypt formation, depletion of mucin, numerous mitosis, and hyperchromatic nuclei along with dysplasia of high grade. Dysplastic rather than hyperplastic crypts are more associated with a higher malignancy incidence (Clapper *et al.*, 2020).

However, there was an improvement in the colon histopathological status upon treatment with Nic, reducing the degree of dysplasia in aberrant crypts, which can be attributed to the chemopreventive potential of Nic. We discovered that the observed damage was more improved in group V as it had a brought back histo-architecture, which resembles that of a normal colon, confirming the potent protective role of Nic against colon carcinogenesis when administered with DMH in the initial stage. This research revealed that Nic had a suppressive and protective effect on the early stages of colorectal cancer development. This has been confirmed by other studies that examined Nic's anticancer activity by inhibiting several pathways that are aberrantly activated in these stages of carcinogenesis in both *in vitro* and *in vivo* models (Li *et al.*, 2014; Satoh *et al.*, 2016). Some of these pathways include Wnt/ β -catenin, which is hyperactive in 80% of patients with sporadic CRC. Stat3, mTORC1, NF-kB and Notch signaling pathways (Wieland *et al.*, 2013; Londono-Joshi *et al.*, 2014; You *et al.*, 2014; Arend *et al.*, 2016). In addition to inhibiting all of these pathways,

which is essential for Nic's anti-proliferative action, Nic targets the mitochondria of cancer cells to induce apoptosis, growth inhibition and cell cycle arrest, making it a potentially effective anticancer agent (Ye *et al.*, 2014; Satoh *et al.*, 2016).

This multi-targeted property of Nic makes it an effective supportive treatment with other basic therapies in colon cancer treatment. In chemoresistant cells, it demonstrated a strong anti-proliferative effect against cancer cells (Chen *et al.*, 2010; Osada *et al.*, 2011; Mook *et al.*, 2013). It could also be used as prophylactic treatment, especially in patients with high risk of CRC, such as those with hereditary syndromes (e.g., FAP and Lynch syndrome) and people with a familial history of colorectal polyps or CRC. Additionally, Nic demonstrated no detectable toxicity on non-cancerous cells *in vitro*, while Nic-treated mice showed no adverse effects (Mook *et al.*, 2015; Mook *et al.*, 2017; Chen *et al.*, 2018; Wang *et al.*, 2018). The clinical trials registry included multiple Nic clinical trials for prostate and colon cancer (Chen *et al.*, 2018). It was proposed that individuals would not experience cumulative adverse effects from long-term exposure to Nic (Andrews *et al.*, 1982). So it could be used safely in a long-term treatment course.

CONCLUSION

This study aimed to confirm and evaluate the anticancer effect of Nic on colon carcinogenesis in a DMH-induced colon cancer animal model. This was indicated by a significantly lower incidence of ACF, ACs, and crypt multiplicity in the middle and distal colon in both Nic-treated groups. Nic reduced the DMH-induced histopathological lesions by decreasing the degree of dysplasia from severe to mild. These alterations were significantly lower in the initiation stage of CRC development in comparison to the post-initiation stage, which confirms the potent anticarcinogenic efficacy of Nic against colon carcinogenesis and makes it a preventive agent that impedes the progression of preneoplastic lesions to neoplasia.

However, more studies will be required to determine its clinical value as a prophylactic and supportive treatment and learn more about its possible role in the advanced stages of colorectal cancer.

REFERENCE

- Al-Hadiya, B.M.H. (2005):* Niclosamide: comprehensive profile. *Profiles of Drug Substances, Excipients and Related Methodology*, 32: 67–96.
- Andrews, P. Thyssen, J. and Lorke, D. (1982):* The biology and toxicology of molluscicides, Bayluscide. *Pharmacology & Therapeutics*, 19(2): 245–295.
- Aranganathan, S. and Nalini, N. (2013):* Retracted: Antiproliferative Efficacy of Hesperetin (Citrus Flavanoid) in 1, 2-Dimethylhydrazine-Induced Colon Cancer. *Phytotherapy Research*, 27(7): 999–1005.
- Arend, R.C.; Londoño-Joshi, A.I.; Gangrade, A. Katre, A.A.; Kurpad, C.; Li, Y.; Samant, R. S.; Li, P.-K.; Landen, C.N. and Yang, E.S. (2016):* Niclosamide and its analogs are potent inhibitors of Wnt/ β -catenin, mTOR and STAT3 signaling in ovarian cancer. *Oncotarget*, 7(52): 86803.
- Balaji, C.; Muthukumar, J. and Nalini, N. (2014):* Chemopreventive effect of sinapic acid on 1, 2-dimethylhydrazine-induced experimental rat colon carcinogenesis. *Human & Experimental Toxicology*, 33(12): 1253–1268.
- Balaji, C.; Muthukumar, J. and Nalini, N. (2015):* Effect of sinapic acid on 1, 2 dimethylhydrazine induced aberrant crypt foci, biotransforming bacterial enzymes and circulatory oxidative stress status in experimental rat colon carcinogenesis. *Bratisl Lek Listy*, 116(9): 560–566.
- Balgi, A.D.; Fonseca, B.D.; Donohue, E.; Tsang, T.C.F.; Lajoie, P.; Proud, C.G.; Nabi, I.R. and Roberge, M. (2009):* Screen for chemical modulators of autophagy reveals novel therapeutic

- inhibitors of mTORC1 signaling. *PLoS One*, 4(9), e7124.
- Bancroft, J.D. and Gamble, M. (2008): *Theory and practice of histological techniques*. Elsevier health sciences.
- Boivin, G.P.; Washington, K.; Yang, K.; Ward, J. M.; Pretlow, T.P.; Russell, R.; Besselsen, D.G.; Godfrey, V.L.; Doetschman, T. and Dove, W.F. (2003): Pathology of mouse models of intestinal cancer: consensus report and recommendations. *Gastroenterology*, 124(3): 762–777.
- Chen, W.; Chen, M. and Barak, L.S. (2010): Development of small molecules targeting the Wnt pathway for the treatment of colon cancer: a high-throughput screening approach. *American Journal of Physiology-Gastrointestinal and Liver Physiology*, 299(2): G293–G300.
- Chen, W.; Mook Jr, R.A.; Premont, R.T. and Wang, J. (2018): Niclosamide: Beyond an antihelminthic drug. *Cellular Signalling*, 41: 89–96.
- Chiou, Y.-S.; Tsai, M.-L.; Wang, Y.-J.; Cheng, A.-C.; Lai, W.-M.; Badmaev, V.; Ho, C.-T. and Pan, M.-H. (2010): Pterostilbene inhibits colorectal aberrant crypt foci (ACF) and colon carcinogenesis via suppression of multiple signal transduction pathways in azoxymethane-treated mice. *Journal of Agricultural and Food Chemistry*, 58(15), 8833–8841.
- Cho, N.L.; Redston, M.; Zauber, A.G.; Carothers, A.M.; Hornick, J.; Wilton, A.; Sontag, S.; Nishioka, N.; Giardiello, F.M. and Saltzman, J.R. (2008): Aberrant crypt foci in the adenoma prevention with celecoxib trial. *Cancer Prevention Research*, 1(1), 21–31.
- Clapper, M.L.; Chang, W.-C. L. and Cooper, H. S. (2020): Dysplastic aberrant crypt foci: biomarkers of early colorectal neoplasia and response to preventive intervention. *Cancer Prevention Research*, 13(3), 229–240.
- Day, D.W.; Jass, J.R.; Price, A.B.; Shepherd, N. A.; Sloan, J.M.; Talbot, I.C.; Warren, B.F. and Williams, G.T. (2003): Epithelial tumours of the large intestine. *Morson and Dawson's Gastrointestinal Pathology*. UK: Blackwell Publishing, 553–566.
- El-Deek, S.E.; Abd-Elghaffar, S.K.; Hna, R.S.; Mohamed, H.G. and El-Deek, H.E. (2022): Effect of hesperidin against induced colon cancer in rats: impact of Smad4 and activin a signaling pathway. *Nutrition and Cancer*, 74(2): 697–714.
- Fayazfar, S.; Oskouie, A.A; Safaei, A.; Zali, H. and Mojarad, E.N. (2021): Identification of key candidate genes and pathways associated with colorectal aberrant crypt foci-to-adenoma-to-carcinoma progression. *Gastroenterology and Hepatology From Bed to Bench*, 14(Suppl1), S41.
- Femia, A. Pietro; Luceri, C.; Toti, S.; Giannini, A.; Dolara, P. and Caderni, G. (2010): Gene expression profile and genomic alterations in colonic tumours induced by 1, 2-dimethylhydrazine (DMH) in rats. *Bmc Cancer*, 10, 1–13.
- Hamilton, S.R.; Vogelstein, B. and Kudo, S. (2000): Carcinoma of the colon and rectum In: Hamilton SR, Aaltonen LA. *World Health Organization Classification of Tumors. Pathology and Genetics of Tumors of the Digestive System*. IARC Press, Lyon, 101–119.
- Hirose, Y.; Kuno, T.; Yamada, Y.; Sakata, K.; Katayama, M.; Yoshida, K.; Qiao, Z.; Hata, K.; Yoshimi, N. and Mori, H. (2003): Azoxymethane-induced beta-catenin-accumulated crypts in colonic mucosa of rodents as an intermediate biomarker for colon carcinogenesis. *Carcinogenesis*, 24(1), 107–111.
- Hossain, M.S.; Karuniawati, H.; Jairoun, A.A.; Urbi, Z.; Ooi, D.J.; John, A.; Lim, Y.C.; Kibria, K.M.K.; Mohiuddin, A.K.M. and Ming, L.C. (2022): Colorectal cancer: a review of carcinogenesis, global epidemiology, current challenges, risk factors, preventive and treatment strategies. *Cancers*, 14(7), 1732.
- Hu, Y.; Ellis, B.L.; Yiu, Y.Y.; Miller, M.M.;

- Urban, J.F.; Shi, L.Z. and Aroian, R.V. (2013): An extensive comparison of the effect of anthelmintic classes on diverse nematodes. *PLoS One*, 8(7), e70702.
- Hussein, S.A.; Abdel-Aal, S.A. and Mady, H.A. (2013): Chemo preventive effect of Curcumin on oxidative stress, antioxidant status, DNA fragmentation and CASPASE-9 gene expression 1, 2-DMH-induced colon cancer in rats. *Benha Vet Med J*, 25(2): 125–138.
- Jin, Y.; Lu, Z.; Ding, K.; Li, J.; Du, X.; Chen, C.; Sun, X.; Wu, Y.; Zhou, J. and Pan, J. (2010): Antineoplastic mechanisms of niclosamide in acute myelogenous leukemia stem cells: inactivation of the NF- κ B pathway and generation of reactive oxygen species. *Cancer Research*, 70(6), 2516–2527.
- Johnson, C.M.; Wei, C.; Ensor, J.E., Smolenski, D.J.; Amos, C.I.; Levin, B. and Berry, D. A. (2013): Meta-analyses of colorectal cancer risk factors. *Cancer Causes & Control*, 24, 1207–1222.
- Kang, H.E.; Seo, Y.; Yun, J.S.; Song, S.H.; Han, D.; Cho, E.S.; Cho, S.B.; Jeon, Y.; Lee, H. and Kim, H.S. (2021): Metformin and niclosamide synergistically suppress Wnt and YAP in APC-mutated colorectal cancer. *Cancers*, 13(14), 3437.
- Karthikkumar, V., Sivagami, G., Viswanathan, P. and Nalini, N. (2015): Rosmarinic acid inhibits DMH-induced cell proliferation in experimental rats. *Journal of Basic and Clinical Physiology and Pharmacology*, 26(2): 185–200.
- Li, Y., Li, P.-K., Roberts, M.J., Arend, R.C., Samant, R.S. and Buchsbaum, D.J. (2014): Multi-targeted therapy of cancer by niclosamide: A new application for an old drug. *Cancer Letters*, 349(1): 8–14.
- Liu, R. and Xu, G. (2008). Effects of resistant starch on colonic preneoplastic aberrant crypt foci in rats. *Food and Chemical Toxicology*, 46(8), 2672–2679.
- Londono-Joshi, A.I., Arend, R. C., Aristizabal, L., Lu, W., Samant, R.S., Metge, B. J., Hidalgo, B., Grizzle, W.E., Conner, M. and Forero-Torres, A. (2014): Effect of niclosamide on basal-like breast cancers. *Molecular Cancer Therapeutics*, 13(4): 800–811.
- Lu, Q., Jiang, B., Lin, C. and Shan, T. (2008). Dark Aberrant Crypt Foci with activated Wnt pathway are related to tumorigenesis in the colon of AOM-treated rat. *Journal of Experimental and Clinical Cancer Research*, 27(1), 1–7.
- Luo, F., Luo, M., Rong, Q.-X., Zhang, H., Chen, Z., Wang, F., Zhao, H.-Y. and Fu, L.-W. (2019). Niclosamide, an antihelmintic drug, enhances efficacy of PD-1/PD-L1 immune checkpoint blockade in non-small cell lung cancer. *Journal for Immunotherapy of Cancer*, 7: 1–13.
- Miller, K. D., Siegel, R. L., Lin, C. C., Mariotto, A. B., Kramer, J. L., Rowland, J. H., Stein, K. D., Alteri, R. and Jemal, A. (2016): Cancer treatment and survivorship statistics, 2016. *CA: A Cancer Journal for Clinicians*, 66(4), 271–289.
- Mook Jr, R. A., Chen, M., Lu, J., Barak, L. S., Lyerly, H. K. and Chen, W. (2013). Small molecule modulators of Wnt/ β -catenin signaling. *Bioorganic & Medicinal Chemistry Letters*, 23(7), 2187–2191.
- Mook Jr, R. A., Ren, X.-R., Wang, J., Piao, H., Barak, L. S., Lyerly, H. K. and Chen, W. (2017): Benzimidazole inhibitors from the Niclosamide chemotype inhibit Wnt/ β -catenin signaling with selectivity over effects on ATP homeostasis. *Bioorganic & Medicinal Chemistry*, 25(6), 1804–1816.
- Mook Jr, R. A., Wang, J., Ren, X.-R., Chen, M., Spasojevic, I., Barak, L. S., Lyerly, H. K., and Chen, W. (2015): Structure–activity studies of Wnt/ β -catenin inhibition in the Niclosamide chemotype: Identification of derivatives with improved drug exposure. *Bioorganic & Medicinal Chemistry*, 23(17): 5829–5838.
- Moskaleva, E.Y., Perevozchikova, V.G.,

- Zhirnik, A.S. and Severin, S.E. (2015): Molecular mechanisms of antitumor activity of niclosamide. *Biochemistry (Moscow) Supplement Series B: Biomedical Chemistry*, 9(4): 312–324.
- Muthu, R., Selvaraj, N. and Vaiyapuri, M. (2016): Anti-inflammatory and proapoptotic effects of umbelliferone in colon carcinogenesis. *Human and Experimental Toxicology*, 35(10), 1041–1054.
- Muthu, R., Thangavel, P., Selvaraj, N., Ramalingam, R. and Vaiyapuri, M. (2013): Synergistic and individual effects of umbelliferone with 5-fluorouracil on the status of lipid peroxidation and antioxidant defense against 1, 2-dimethylhydrazine induced rat colon carcinogenesis. *Biomedicine & Preventive Nutrition*, 3(1): 74–82.
- Norat, T., Aune, D., Chan, D. and Romaguera, D. (2014). Fruits and vegetables: updating the epidemiologic evidence for the WCRF/AICR lifestyle recommendations for cancer prevention. *Advances in Nutrition and Cancer*, 35–50.
- Ochiai, M., Watanabe, M., Nakanishi, M., Taguchi, A., Sugimura, T. and Nakagama, H. (2005): Differential staining of dysplastic aberrant crypt foci in the colon facilitates prediction of carcinogenic potentials of chemicals in rats. *Cancer Letters*, 220(1): 67-74.
- Okda, T. M., Abd EL-Aziz, M. A., El-Melegy, N. T., Taha, H. H. and Abd Elghaffar, S. K. (2014): Biochemical and Molecular Assessments of Possible Roles of Soybean in 1, 2-dimethylhydrazine-induced Colon Cancer Chemotherapeutic. *Academic Journal of Cancer Research*, 7(2), 152–161.
- Osada, T., Chen, M., Yang, X. Y., Spasojevic, I., Vandeusen, J. B., Hsu, D., Clary, B. M., Clay, T. M., Chen, W. and Morse, M. A. (2011): Antihelminth compound niclosamide downregulates Wnt signaling and elicits antitumor responses in tumors with activating APC mutations. *Cancer Research*, 71(12): 4172–4182.
- Panahi, Y., Dadkhah, M., Talei, S., Gharari, Z., Asghariazar, V., Abdolmaleki, A., Matin, S. and Molaei, S. (2022): Can anti-parasitic drugs help control COVID-19? *Future Virology*, 17(5), 315–339.
- Paulsen, J. E., Løberg, E. M., Ølstørn, H. B., Knutsen, H., Steffensen, I.-L. and Alexander, J. (2005): Flat dysplastic aberrant crypt foci are related to tumorigenesis in the colon of azoxymethane-treated rat. *Cancer Research*, 65(1), 121–129.
- Perše, M. and Cerar, A. (2011): Morphological and molecular alterations in 1, 2 dimethylhydrazine and azoxymethane induced colon carcinogenesis in rats. *BioMed Research International*, 2011.
- Rehman, M. U., Rahman Mir, M. U., Farooq, A., Rashid, S. M., Ahmad, B., Bilal Ahmad, S., Ali, R., Hussain, I., Masoodi, M., and Muzamil, S. (2018): Naringenin (4, 5, 7-trihydroxyflavanone) suppresses the development of precancerous lesions and inflammation in the colon of Wistar rats. *Environmental Toxicology*, 33(4), 422–435.
- Rodrigues, M.A.M.; Silva, L.A.G.; Salvadori, D. M.F.; De Camargo, J.L.V. and Montenegro, M.R. (2002): Aberrant crypt foci and colon cancer: comparison between a short- and medium-term bioassay for colon carcinogenesis using dimethylhydrazine in Wistar rats. *Brazilian Journal of Medical and Biological Research*, 35(3), 351–355.
- Satoh, K., Zhang, L., Zhang, Y., Chelluri, R., Boufraquech, M., Nilubol, N., Patel, D., Shen, M. and Kebebew, E. (2016): Identification of niclosamide as a novel anticancer agent for adrenocortical carcinoma. *Clinical Cancer Research*, 22(14), 3458–3466.
- Sayed, A., Youssef, E.A., Mahmoud, S.A., Yousry, S. and Abdel-Mawla, A.A. (2023): Effect of niclosamide on

- colorectal cancer induced by dimethylhydrazine in albino mice. *Egyptian Journal of Basic and Applied Sciences*, 10(1): 846–860.
- Senedese, J.M., Rinaldi-Neto, F., Furtado, R.A., Nicollela, H.D., de Souza, L.D.R., Ribeiro, A.B., Ferreira, L.S., Magalhaes, G.M., Carlos, I.Z. and da Silva, J.J.M. (2019): Chemopreventive role of *Copaifera reticulata* Ducke oleoresin in colon carcinogenesis. *Biomedicine & Pharmacotherapy*, 111, 331–337.
- Sharma, S. H., Chellappan, D. R., Chinnaswamy, P. and Nagarajan, S. (2017): Protective effect of p-coumaric acid against 1, 2 dimethylhydrazine induced colonic preneoplastic lesions in experimental rats. *Biomedicine & Pharmacotherapy*, 94: 577–588.
- Siddique, A. I., Mani, V., Arivalagan, S., Thomas, N.S. and Namasivayam, N. (2017): RETRACTED ARTICLE: Asiatic acid attenuates pre-neoplastic lesions, oxidative stress, biotransforming enzymes and histopathological alterations in 1, 2-dimethylhydrazine-induced experimental rat colon carcinogenesis. *Toxicology Mechanisms and Methods*, 27(2), 136–150.
- Siegel, R., DeSantis, C. and Jemal, A. (2014): Colorectal cancer statistics, 2014. *CA: A Cancer Journal for Clinicians*, 64(2), 104–117.
- Siu, I.-M., Pretlow, T.G., Amini, S.B. and Pretlow, T.P. (1997): Identification of dysplasia in human colonic aberrant crypt foci. *The American Journal of Pathology*, 150(5), 1805.
- Strimbu, K. and Tavel, J. A. (2010): What are biomarkers? *Current Opinion in HIV and AIDS*, 5(6), 463.
- Sugihara, Y., Zuo, X., Takata, T., Jin, S., Miyauti, M., Isikado, A., Imanaka, H., Tatsuka, M., Qi, G. and Shimamoto, F. (2017): Inhibition of DMH-DSS-induced colorectal cancer by liposomal bovine lactoferrin in rats. *Oncology Letters*, 14(5): 5688–5694.
- Suvarna, K.S., Layton, C. and Bancroft, J. D. (2018): *Bancroft's theory and practice of histological techniques*. Elsevier health sciences.
- Tanaka, T. (2009): Colorectal carcinogenesis: Review of human and experimental animal studies. In *Journal of Carcinogenesis* (Vol. 8, Issue 5).
- Thorup, I. (1997): Histomorphological and immunohistochemical characterization of colonic aberrant crypt foci in rats: relationship to growth factor expression. *Carcinogenesis*, 18(3): 465–472.
- Thyne, V. (2020): *The Effects of Different Wheat Types on Colon Cancer Risk*. University of Minnesota.
- Verma, A. and Shukla, G. (2013): Administration of prebiotic inulin suppresses 1, 2 dimethylhydrazine dihydrochloride induced procarcinogenic biomarkers fecal enzymes and preneoplastic lesions in early colon carcinogenesis in Sprague Dawley rats. *Journal of Functional Foods*, 5(2), 991–996.
- Wang, A., Ku, H., Liang, Y., Chen, Y., Hwu, Y. and Yeh, T. (2009): The autonomous notch signal pathway is activated by baicalin and baicalein but is suppressed by niclosamide in K562 cells. *Journal of Cellular Biochemistry*, 106(4), 682–692.
- Wang, J., Mook Jr, R. A., Ren, X., Zhang, Q., Jing, G., Lu, M., Spasojevic, I., Lyerly, H. K., Hsu, D. and Chen, W. (2018): Identification of DK419, a potent inhibitor of Wnt/ β -catenin signaling and colorectal cancer growth. *Bioorganic & Medicinal Chemistry*, 26(20), 5435–5442.
- Wargovich, M.J., Brown, V.R. and Morris, J. (2010): Aberrant crypt foci: the case for inclusion as a biomarker for colon cancer. *Cancers*, 2(3), 1705–1716.
- Wieland, A., Trageser, D., Gogolok, S., Reinartz, R., Höfer, H., Keller, M., Leinhaas, A., Schelle, R., Normann, S. and Klaas, L. (2013): Anticancer effects of niclosamide in human glioblastoma. *Clinical Cancer Research*, 19(15), 4124–4136.

- Yang, F., Ye, T., Liu, Z., Fang, A., Luo, Y., Li, Y., Li, Y., Zeng, A., Deng, Y. and Gou, H. (2016): Niclosamide induces colorectal cancer apoptosis, impairs metastasis and reduces immunosuppressive cells in vivo. *RSC Advances*, 6(107), 106019–106030.
- Ye, T., Xiong, Y., Yan, Y., Xia, Y., Song, X., Liu, L., Li, D., Wang, N., Zhang, L. and Zhu, Y. (2014). The anthelmintic drug niclosamide induces apoptosis, impairs metastasis and reduces immunosuppressive cells in breast cancer model. *PloS One*, 9(1), e85887.
- You, S., Li, R., Park, D., Xie, M., Sica, G. L., Cao, Y., Xiao, Z.-Q., & Deng, X. (2014): Disruption of STAT3 by niclosamide reverses radioresistance of human lung cancer. *Molecular Cancer Therapeutics*, 13(3): 606–616.
- Zahid, A. and Young, C.J. (2016): How to decide on stent insertion or surgery in colorectal obstruction? *World Journal of Gastrointestinal Surgery*, 8(1), 84.

التأثير المضاد للأورام للنيكلوساميد على سرطان القولون والمستقيم المستحث تجريبياً في الجرذان

سمر سليمان خلف ، ساري خليل عبد الغفار ، مروة فاروق على

Email: samar_soliman@vet.aun.edu.eg Assiut University web-site: www.aun.edu.eg

من الأدوات البحثية الأساسية لدراسة سرطان القولون والمستقيم (CRC) استخدام ٢٠١-ثنائي ميثيل الهيدرازين (DMH) كنموذج حيواني لتسريع القولون والمستقيم. تم تحديد النيكلوساميد، وهو دواء مضاد للديدان عن طريق الفم، كعامل محتمل مضاد للسرطان. تهدف هذه الدراسة إلى تحديد التأثير المحتمل للمضاد للسرطان للنيكلوساميد على التسريع في القولون والمستقيم. تم تقسيم خمسة وثلاثين جرذاً إلى خمس مجموعات. تلقت المجموعة الأولى (I) المذيب لمدة ٤ أسابيع. تلقت المجموعة الثانية (II) النيكلوساميد عن طريق الحقن داخل الصفاق I/P بجرعة ٢٠ ملجم/كجم من وزن الجسم يومياً لمدة ٤ أسابيع. تم إعطاء المجموعة الثالثة (III) حقن تحت الجلد S/C من DMH بجرعة ٢٠ ملجم /كجم من وزن الجسم مرتين في الأسبوع لمدة ٤ أسابيع. المجموعة الرابعة (IV) و التي تلقت DMH أولاً كما في المجموعة الثالثة، وبعد أسبوع واحد من آخر حقن DMH، تلقتوا نيكلوساميد عن طريق الحقن داخل الصفاق I/P بجرعة ٢٠ ملجم /كجم من وزن الجسم يومياً حتى نهاية التجربة. تلقت المجموعة الخامسة (V) النيكلوساميد عن طريق الحقن داخل الصفاق I/P بجرعة ٢٠ ملجم/كجم من وزن الجسم يومياً، وفي الوقت نفسه، تم إعطاؤها حقن من DMH تحت الجلد S/C بجرعة ٢٠ ملجم/كجم من وزن الجسم مرتين في الأسبوع لمدة أربعة أسابيع. وفي نهاية التجربة التي استمرت ١٢ أسبوعاً، تم ذبح الجرذان لأخذ العينات. تم جمع جميع عينات القولون من كل المجموعات لحساب بؤر التجويف الشاذة (ACF) باستخدام ٢، ٠٪ أزرق الميثيلين. تم أخذ عينات الأنسجة لفحصها النسيجي. وفقاً للسمات الطبوغرافية لأفات ما قبل الورم في القولون، وجدنا أن المجموعة الثالثة لديها أكبر عدد من ACF وتعدد السرداب، في حين أن المجموعتين IV و V كان لهما عدد أقل بكثير. مجهرياً، أظهرت الفئران التي تلقت DMH تغيرات معتدلة إلى شديدة في خلل التنسج. انخفضت هذه التغييرات بشكل ملحوظ في كلا المجموعتين المعالجتين بالنيكلوساميد، إلا أن المجموعة الخامسة أظهرت تحسن أفضل. أشارت هذه النتائج إلى التأثير الوقائي الواضح للنيكلوساميد ضد تطور بؤر التجويف الشاذة.

الكلمات الافتتاحية: سرطان القولون والمستقيم؛ DMH؛ نيكلوساميد؛ ACF؛ التغييرات النسيجية.