ضفيرة الزراع فى الجمل

د. محمد الشايب

الملخص

لقد وجد ان ضفيرة الزراع فى الجمل تتكون من الفروع البطنية للعصبين العنقيين الاخيرين والعصب الصدرى الاول فقط .

وقد تم شرح مصدر ومسار وتوزيع الاعصاب الصادرة من هذه الضفيرة بالتفصيل فى القائمه الاماميه للجمل وكذلك تم مناقشة النتائج ومقارنتها مع باقى الحيوانات المستأنسة .

Dept. of Anatomy and Histology Faculty of Vet. Med. Assiut University.
Head Prof. : Dr. H. Badawi

THE BRACHIAL PLEXUS OF THE CAMEL CAMELUS DROMEDARIUS

(With 4 Figures)

By

M. El - Shaieb

(Received at 27/1/1976)

SUMMARY

The brachial plexus of the camel (Camelus Dromedarius) is found to be derived from the ventral branches of the last two cervical and first thoracic nerves. The origin, course and distribution of each of its nerves were described in details. The observations were discussed and compared with that of other domestic animals.

INTRODUCTION

In the available literature only a very brief account on the brachial plexus of the camel was given by LESBRE (1903). It is therefore the object of this paper to report in some detail on the anatomy of this plexus of nerves of the camel.

MATERIAL AND METHODS

Four camles of the species (Camelus dromedarius) were used in this work, The origin and formation of the brachial plexus as well as the distribution of its nerves were examined by carefull dissection in all the eight forelimbs. The nomenclature used in this work was adopted by the Nomina Anatomica Veterinaria (1973).

RESULTS

The brachial plexus of the camel (1/1) (Camelus dromedarius) appears as a broad band between the two portions of the scalenus muscle. It was found that in all specimens, the brachial plexus of the camel is formed by the union of the ventral branches of the last two cervical nerves (7th and 8th) and the first thoracic nerve. Within the vertebral canal and close to the spinal cord the three roots of the brachial plexus are connected with each other by anastomotic branches.

The brachial plexus of the camel detaches the following nerves:

Nn. pectorales:

The pectoral nerves are represented by cranial and caudal nerves. Their fibers are derived from the eighth cervical and first thoracic nerves. The cranial pectoral nerve (N. pectoralis cranialis) (1/13) divides into 3-4 branches which ramify in the superficial pectoral muscle and the cranial and middle portions of the deep pectoral muscle.

The caudal pectoral nerve (N. pectoralis caudalis) (1/14) courses distally and caudally along the external thoracic vein on the deep surface of the deep pectoral which it supplies through 2-3 smaller branches. The caudal pectoral nerve detaches also a cutaneus branch about the middle of the arm which curves around the caudal border of the long head of the triceps muscle to ramify in the skin of the caudo-lateral aspect of the arm.

N. suprascapularis:

The suprascapular nerve (1/2) is derived from the seventh and eighth cervical roots of the plexus. It disappears between the supraspinatus and subscapular muscles 10-15 cm. proximal to the level of the shoulder joint. Close to the cranial border of the subscapular muscle it divides into three branches proximal, middle and distal. The proximal and middle branches ramify in the proximal and distal portions of the supraspinatus muscle. The distal and the largest branch continues the direction of the parent nerve between the subscapular and supraspinatus muscles. It curves around the cranial border of the scapula under the supraspinatus muscle to reach the lateral aspect of the scapula where it courses caudally to end in the infraspinatus muscle.

Nn. subscapulares:

The subscapular nerves (1/3) are derived from the seventh and eight cervical components of the brachial plexus. They are 2-3 small branches which are distributed in the subscapular muscle. In a single case the most caudal branch was found to connect with the thoracodorsal nerve by an asnastomotic twig.

N. thoracodoraslis:

The thoracodorsal nerve (1/5) is derived mainly from the eighth cerivcal and first thoracic roots of the brachial plexus and a small root from the seventh cervical was observed in few cases. It proceeds across the distal third of the medial aspect of the teres major muscle to innervate the latissimus dorsi muscle. close to its origin the thoraco-dorsal nerve gives off a branch (1/5) to the subscapular muscle and another one (1/5) to the teres major muscle. As it has already been mentioned the thoracodorsal nerve may be found to be connected with the subscapular nerve and in this case it was found to supply no branches to the subscapular muscle.

N. thoracicus longus:

The long thoracic nerve (1/4) is derived from the eighth cervical and a small root from the seventh cervical components of the plexus. It courses caudally along the lateral aspect of the chest wall across the surface of the M. serratus ventralis to which it detaches 5-7 twigs.

N. musculocutaneus:

The musculocutaneus nerve (1/12) is given together with the median and ulnar nerves by a common trunk which is derived from the eighth cervical and first thoracic roots of the brachial plexus as well as small one from the seventh cervical root. On reaching the M. coraco-brachialis it divides into two unequal branches. Ramus muscularis proximalis and Ramus muscularis distalis. The larger proximal muscular branch detaches a small twig to the M. coracobrachialis and traverses it near its proximal third to end in the M. biceps brachii by 3 branches. The distal muscular branch innervates the M. coracobrachialis. The ansa axillaris which is formed between the median and musculocutaneus nerves was not observed in the camel.

N. axillaris:

The axillary nerve (1/6) arises in common with the radial nerve by a commonstem which is dervied from the eighth cervical and first thoracic components of the brachial plexus. It disappears behind the shoulder joint in the area bounded by the subscapular, teres major and long head of the triceps. It appears on the lateral aspect of the arm under cover of the deltoid muscle where it detaches a twig to the M. Capsularis and to the shoulder joint. Beneath the deltoid muscle the axillary nerve gives off a branch to the teres minor muscle three branches to the deltoid muscle, and a cutaneus branch (N. cutaneus brachii lateralis cranialis). It then continues distally along the deep surface of the deltoid muscle to end in the caudal portion of the brachiocephalic muscle.

The cutaneus branch of the axillary nerve (N. cutaneus brachii lateralis cranialis) (3/2) appears from beneath the distal portion of the deltoid muscle It continues distally on the lateral head of the triceps muscle and on reaching the flexor aspect of the elbow joint it divides into two branches. One of these branches (N. cutaneus antibrachii cranialis) anastomoses with the cutaneus branch of the radial nerve, while the other branch divides into 2-3 smaller twigs which are distributed in the skin and fascia on the dorsolateral aspect of the arm and the proximal end of the forearm.

N. radialis:

Mention has been given to the origin of the radial nerve (1/7) in common with the axillary nerve from the eighth cervical and first thoracic components of the brachial plexus. The radial nerve descends distally for a short distance along the caudal border of the brachial artery to reach the interval between

the long and medial heads of the triceps muscles. It then runs along the lateral aspect of the M. brachialis covered laterally by the lateral head of the triceps and the M. extensor carpi radialis. It then passes distally between the extensor muscles of the carpus and digits and the proximal extremity of the radius. It then descends along the radius where it ends in the M. abductor digiti I (pollicis) longus.

During its course the radial nerve detaches the following branches:

Two branches for each of the three heads of the M. triceps-brachii, a branch to the anconeus muscle, a cutaneus branch (N. cutaneus antibrachii lateralis), 4-6 twigs to the M. extensor carpi radialis as well as an anastomotic branch which joins a muscular branch of the median nerve to the M. brachialis and 2-3 branches to the extensor muscles of the digits and M. extensor carpi ulnaris.

The cutaneus branch of the radial nerve (N. cutaneus antebrachii lateralis S. Ramus superficialis (3/3) divides under the lateral head of the triceps muscle into a cranial (3/3) and a caudal branch (3/3") which become superficial from under the distal border of the lateral head of the triceps muscle and descend along the lateral aspect of the M. extensor carpi radialis. The caudal branch ramifies in the skin of the caudo lateral aspect of the forearm as well as the skin of the cranio-lateral aspect of the fore-arm and carpus by two branches. The cranial branch ramifies in the skin of the cranio-lateral aspect of the fore-arm and carpus. It detaches two twigs which descend distally along the medial and lateral borders of the cephalic vein in the forearm, carpus and metacarpus where they form the Nn. digitales dorsales communes II and III (4/a). The medial twig (N. digitalis dorsalis communis II) continues distally along the abaxial surface of the medial digit as N. digitalis dorsalis III abaxialis (4/3). The lateral twig (N. digitalis dorsalis communis III) divides at the distal end of the metacarpus into two nerves Nn. digitales dorsales III and IV axialis (4/4) which run along the dorso-axial aspects of each digit.

As mentioned before the cranial branch of the cutaneus branch of the radial nerve is connected with the cutaneus branch of the axillary nerve in the proximal end of the forearm.

In only two cases an anastomotic twig was observed between the cranial and caudal branches of the cutaneus branch of the radial nerve.

N. medianus:

As mentioned before the Median nerve (1/11, 2/1) is detached with the ulnar and musculocutaneus nerves by a common trunk from the eighth cervical and first thoracic roots of the brachial plexus and a small branch from the seventh root. It descends along the cranio medial aspect of the brachial artery in the arm region. At the elbow joint it crosses the medial aspect of that

artery and continues distally into the forearm along the caudal border of the median artery between the radial head of the deep flexor muscle and the M. flexor carpi radialis. In the arm region and at the level of the elbow joint the median nerve is covered medially by the fascia of the arm and the superficial pectoral muscle. At the carpus the nerve descends in the carpal canal and continues into the metacarpal region cranial to the artery and along the medial border of the deep flexor tendon.

About the middle of the metacarpal region the median nerve divides into medial and lateral branches namely N. digitalis palmaris communis II (2/4) and N. digitalis palmaris communis III (2/5) respectively. The medial one N. digitalis palmaris communis II (2/4) divides at a distance of 5-6 cm. above the fetlock into the N. digitalis palmaris III axialis (2/6) and N. digitalis palmaris III abaxialis (2/7) which pass along the corresponding aspects of the medial digit enclosed by the foot pad.

The lateral branch N. digitalis palmaris communis III (2/5) detaches a communicating branch (Ramus communicans) (2/8) above the fetlock joint to the N. digitalis palmaris IV abaxialis of the ulnar nerve. It then continues distally along the axial aspect of the lateral digit as N. digitalis palmaris IV axialis. (2/5).

Along its course the median nerve supplies the following branches:

— A branch of considerable size is given off about the middle of the M. biceps brachii. This branch disappears between the M. biceps brachii and the medial head of the triceps, joins a small twig from the radial nerve and enters the M. brachialis.

— Several muscular branches (Rami musculares) are detached just below the elbow joint to the M. flexor carpi radialis, the humeral and radial heads of the deep flexor muscle and an interosseous branch (N. interosseus antibrachii) through the interosseous space for the radius and ulna.

— Two other branches are detached at the distal fourth of the fore-arm for the synovial sheaths around the flexor tendons and the carpal joint.

N. ulnaris:

The ulnar nerve (1/8, 3/5) arises from the most caudal part of the common nerve trunk for it, the median and musculocutaneous nerves. The ulnar nerve crosses the medial aspect of the brachial vesseles as it descends towards the olecranon where it is covered medially by the fascia of the arm and the superficial pectoral muscle. In the forearm region the nerve continues distally at first between the M. flexor carpi ulnaris and the M. extensor carpi ulnaris, then between the latter muscle and the superficial digital flexor muscle.

At the proximal third of the medial head of the triceps muscle the ulnar nerve supplies a cutaneus branch (N. cutaneus antibrachii caudalis.) The latter descends under the fascia of the arm into the fore-arm crossing the medial aspect of the median nerve. About 10 cm. below the elbow joint it divides into two branches. One of these branches ramifies as cutaneus twig on the caudal aspect of the forearm. The other branch continues distally in the forearm and carpus supplying the skin on the caudo-medial aspect of these regions.

Slightly distal to the olecranon the unlar nerve gives off three muscular branches (rami musculares) which ramify in the M. flexor carpi ulnaris, M. flexor digitalis superficialis and the ulnar head of the deep flexor muscle.

At the distal fourth of the fore-arm the ulnar nerve divides into a dorsal branch (ramus dorsalis) (1/9, 3/5, 4/2) and a palmar branch (ramus palmaris) (1/10, 2/2, 3/5"). The ramus dorsalis (1/9, 3/5', 4/2) passes laterally to emerge between the tendons of the M. flexor carpi ulnaris and of the M. extensor carpi ulnaris and descends along the dorso-lateral aspect of the carpus metacarpus and lateral digit as the N. digitalis dorsalis IV abaxialis (4/5).

The ramus palmaris (1/10, 2/2, 3/5") continues distally behind the carpus and metacrpus along the lateral border of the deep flexor tendon; it detaches 1-3 branches (2/10) to the suspenscry ligament.

The palmar branch of the ulnar nerve unites above the fetlock with the ramus communicans of the N. digitalis palmaris communis III of the median nerve and continues as the N. digitalis palmaris IV abaxialis (2/9) along the abaxial aspect of the lateral digit.

DISCUSSION

The present investigation shows that the brachial plexus of the camel is derived from the ventral branches of the last two cervical nerves and that of the first thoracic nerve. In the horse however it is formed from the ventral branches of the last three cervical and first two thoracic nerves BRADLEY (1947), AKAEVSKI (1968) and SISSON (1969). The contribution of the 2nd thoracic nerve to the brachial plexus was found by SHERRINGTON (1898) in monkeys, horse, rabbit and rat, it was sometimes absent in dog and frequently absent in the cat. WINGATE TODD (1912) reproted that great individual variation is found throughout the mammalian series in that communication given by the 2nd thoracic nerve to the brachial plexus.

The origin of the different nerves given by the brachial plexus of the camel is determined for the first time from the spinal nerves.

The thoracodorsal nerve of the camel is found to detach branches to the subscapular and teres major muscles, RAGHAVAN (1964) states that the N. thoracodorsalis in the ox is confounded at its origin with the axillary nerve and also with one of the two branches of the nerves to the M. subscapularis and the nerve to the teres major.

The ansa axillaris which is formed by the union of the median and musculocutaneus nerves of other domestic animals like horse BRADLEY (1947) and SISSON (1969) is not observed in the camel.

TODD, WINGATE (1912) noted that in the group of mammals comprising the camels, llamas and giraffes the nerve supply to the sterno-and brachiocephalic muscles comes entirely from the cervical nerves, in this investigation the brachiocephalic muscle of the camel is found to be partly innervated by a branch from the axillary nerve entering it close to its humeral attachemnt.

The established anastomosis between the cutaneus branches of the axillary and radial nerves observed in the camel is not met with in other domestic animals in the available literature. The innervation of the M. brachialis of the camel is similar to that of the ox (RAGHAVAN (1964).) It receives a branch from the median nerve besides the branch from the radial. The branches from these two nerves may either enter the muscle separately or they may unite to form a common nerve. While in the horse SISSON (1969) reported that the radial nerve inconstantly supplies branch to the brachialis muscle and this muscle is cheifly innervated from the median nerve.

Unlike that of the ox the cutaneus nerve of the radial nerve of camel descends distally by two branches along the medial and lateral border of the cephalic vien into the metacarpal region. LAKSHMINARASIMHAN (1968) observes a rare variation in the terminal part of the course of the radial and median nerves in a bull calf. The cutaneus branch of the median nerve which is reported in other domestic animals BRADLEY (1964) (1947), RAGHAVAN and SISSON (1969) is not observed in the camel, it may be replaced by the large cutaneus branch of the ulnar nerve (N. cutaneus antibrachii caudalis),

The terminal branches of the median and ulnar nerves resemble those of the ox RAGHAVAN (1964), AKAEVSKI (1968) and SISSON (1969).

REFERENCES

Akaevski, A.E (1968) Anatomya domashmikh Zhivotnyckh. Moskva.

Bradley, O.C., (1947): Topographical anatomy of the horse-Fore and hind limbs. London.

Lakshminarasimhan, A. (1968). A rare variation in the radial and median nerves in a bull. calf. *Indian Vet. J.* 45, 1002-1003.

Lesbre, M.F.X., (1903). Recherches Anatomiques sur les Camelidées. Archives du Museum D'Histoire Naturalles, Lyon.

Raghavan, D. (1964). Anatomy of the ox. Indian council of Agricultural Research. New Delhi.

Sisson, S. and Grossman, *J.* (1969). The anatomy of domestic animals. Saunders comp. Philadelphia and london

Sherrington, (1898). Experiments in Exmination of the peripheral Distribution of the fibres of the posterior Roots of some spinal nerves. *Phil. Trans. Roy. Sac. Lodn.*, Vol, 190 B.

Todd, T. wingate Todd, C.G., (1912). The sterno and brachiacephalic muscles and their nerve supply with special reference to the Ungulata. *Anat. Anz. B.* 42 P. 71-79.

Todd, Wingate, (1912): The hinder Fnd of the brachial plexus in man and mammals. *Anat. Anz. B.* 42 . 129-144.

Auther's adress Dr. M. El-Shaieb. Fac. of vet. Med. Assiut university. Dept of Aanatomy.

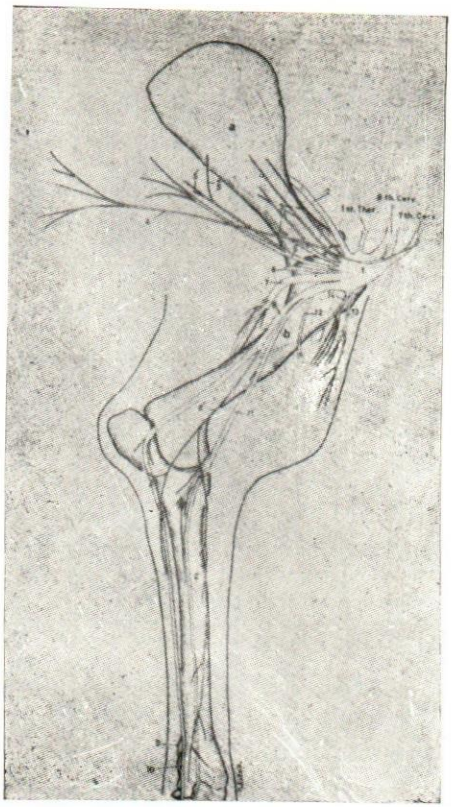

Fig. 1. Diagram of Left fore Limb of camel (medial view)

a.—Scapula b- humerus c-radius and ulna 7th. cerv. 8th. cerv. 1st. thor. (Roots of the bracial plexus).

1.—Brachial plexus 2-N. suprascapularis 3-Nn. subscapulares 4- N. thoracolongus 5-N. thoracodorsalis 5-Its branch to M. terses major 5 ". its brach to M. subscapularis 6-N. axillaris 7-N. radialis 8-N ulnaris 8' its cutaneus branch (N. cutaneus antibrachii caudalis). 9-dorsal branch of ulnar nerve 10-palmar branch of ulnar nerve 11-N. medianus 12-N. musculocutaneus 13-N. pectoralis cranialis 14-N. pectoralis caudalis.

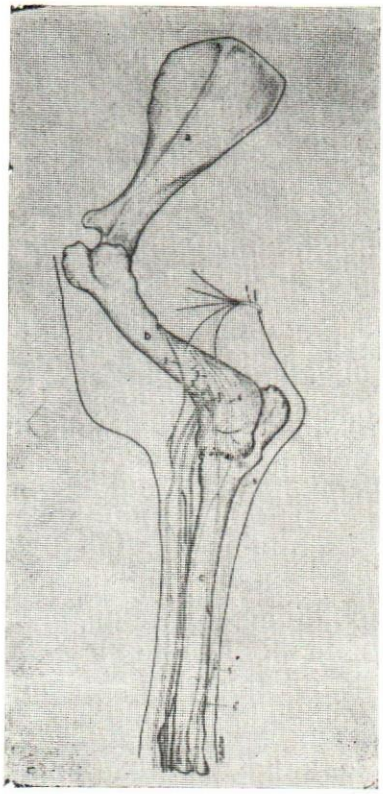

Fig. 3. Diagram of left fore-limb of camel (shoulder, arm and forearm) lateral view.

a.—Scapula b—humerus c.—radius and ulna.

1.—Cutaneus branch of caudal pectoral nerve.

2.—N. cutaneus brachii lateralis cranialis of axillary nerve.

3.—N. cutaneus antibrachii lateralis of the radial nerve 3′.—its cranial branch 3″-its caudal branch.

4.—continuation of the radial nerve. 5. N. ulnaris .

5.—its dorsal brach 5'' its palmar branch.

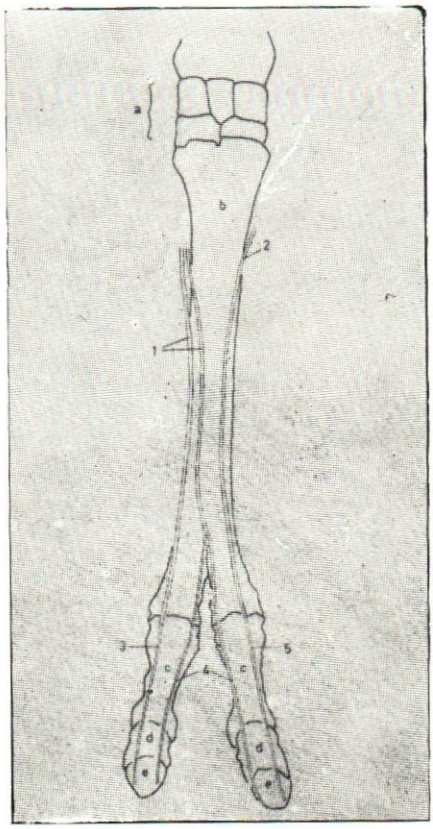

Fig. 4. Diagram of cranial(dorsal)aspect of the distal end of left fore-limb of the camel

a.—carpus b.—Metacarpus c.—lst phalanx d.—2nd phalanx e.—3rd. phalanx-

1.—Nn. digitales dorsales communes, II, III from cutaneus antibrachii lateralis of the radial nerve.

2—Ramus superficialiss dorsalis of the ulnar nerve which forms the N. digitalis dorsalis communis IV

3—N. digitalis dorsalis III- abaxialis.

4—N_n. digitales dorsales III and IV-axialis.

5—N. digitalis dorsalis IV abaxialis.