الأستئصال التجريبي للمرىء العنقي
وتوصيل نهايته في الكلاب

م. منزلي ، ن. مسك ، ح. سالم ، م. سليم

أجريت الدراسة الحالية على ٤٨ من الكلاب الصحية ظاهرية واستهدفت فتح المرىء واستئصال ١ ، ١½ ، ٢ سم من المرىء مع توصيل النهايتين في الحال . ولقد أظهرت النتائج أن الجزء الذي يمكن استئصاله من المرىء العنقي في الكلاب مع الأحتفاظ بوظيفته لا يزيد طوله عن ١½ سم .

Depts. of Surgery and Pathology,
Faculty of Vet. Med. Assiut University,
Heads of Depts. Prof. Dr. M. El-Monzaly and Prof. Dr. A.R. Khater.

EXPERIMENTAL RESECTION OF THE CERVICAL OESOPHAGUS WITH END-TO-END ANSTOMOSIS IN DOGS

(With 9 Figures)

By

M. EL-M. MONZALY, N.A. MISK, H.A. SALEM and M.A. SALEIM

(Received at 8/4/1980)

SUMMARY

The present study was conducted on 48 apparently healthy dogs. The operations performed were oesophagostomy and 1, 1½ and 2 cm. oesophageal resection with immediate end-to-end anastomosis. The results showed that the amount of resection of the cervical oesophagus in dogs must not exceed than 1.5 cm. in lenth and in which its function is to maintatined.

INTRODUCTION

Oesophageal anastomosis after resection of the cervical oesophagus is one of the important operative techniques described for the radical treatment in case of its surgical diseases in man and animals.

Oesophageal resection was indicated in cases of strictured segment of the oesophagus due to swallowing of corresive substances, peptic oesophagitis or previous oesophageal surgery (ELLIS,ANDERSON and CLAGETT 1958; BESLEY 1965; BAKER and HOFFER 1966 and HARRISON 1972), oespphageal neoplasms (THRASHER, ICHINOSE and PITOT,1963 and COLGROVE 1971), achalasia (PRIBAM, 1922 and DE'OLIVER 1955) and spirocerca lesions (THRASHER et al. 1963).

The surgery of the cervical oesophagus is somewhat difficult due to some problems that are not encountered either in its thoracic portion or other parts of the alimentary tract (BAKER et al. 1966 and SINGH and TYAGI 1972). These problems could be summarized as follows: The cervical

oesophagus lacks a serosa, its blood supply is comparatively meagre, it is subjected to constant movement, its enclosure with some vital structures such as trachea, common carotid artery, vagosympathetic trunk and left recurrent laryngeal nerve. Attempts at anastomosis induce stricture of its lumen.

The purpose of the present investigation is to carry on studies on the healing process of the cervical oesophagus in cases of oesophageal resection as well as end-to-end anastomosis and to determine to what extent the surgeon can resect the cervical oesophagus and at the same time preserve its function with a minimal degree of complication.

MATERIAL AND METHODS

The present study was conducted on 48 apparently healthy dogs between 1 and 3 years old and of 10-20 Kg. body weight. The animals were divided into 4 main groups each comprising 12 animals. The operations performed were oesophagostomy, 1, 1½ and 2 cm. oesophageal resection. The suture material used was 4/0 catgut inserted with an eyeless round needle.

The specimens for patho-anatomical and histo-pathological studies were taken from the site of operation at one, two, three, four, five and six weeks post operations.

Preoperative treatment:

Food was witheld overnight before the operation. 15 minutes before the induction of general anaesthesia (Thiopental sodium "Nesdonal" intravenously in a dose of 20-30 mg/Kg. body weight). The animal was premedicated with an intramuscular injection of chloropromazine HCl (Neurazine) in a dose of 1 mg/Kg. body weight(HALL, 1974). The area of operation at the ventral aspect of the neck was prepared for aseptic operation.

Operative procedures:

A longitudinal incision of 8-10 cm. was made at the middline of the ventral aspect of the neck. Exposure of the oesophagus was performed by

the technique after MISK and HIFNY (1976). Special attention was paid to the vagosympathetic trunk and the left recurrent laryngeal nerve which were run along the lateral and medial aspects of the cervical oesophagus, respectively, so as to avoid their injuries. The operative procedures varied according to the needed operation.

Group I:Oesophagostomy (12 dogs).

Group II:1 cm. oesophageal resection (12 dogs).

Group III:1.5 cm. oesophageal resection (12 dogs).

Group IV:2 cm. oesophageal resection (12 dogs).

The two cut ends of the oesophagus were anastomosed end-to-end using an eyeless round needle, catgut No. 4/0 and the modified Plakhotin technique (ENGLISH, 1959; KNIGHT, 1963; BAKER and HOFFER, 1966 and MISK,1973 and 1974). The latter suture is an inverting suture including the full thickness of the oesophageal wall and is applied in a single row, PLAKHOTIN, (1946) and MISK, (1974). After suturing the oesophageal wound the oesophagus was returned to its normal position and the cervical wound was closed.

Post-operative care:

Only water and milk were given once daily for three days following the operation. From the fourth day on, a normal diet of small piece of bread, raw meat and cooked rice was given once daily.

Clinical picture:

The animals were clinically examined daily from the day of operation till the end of experiment for general condition, appetite and the swallowing process. Local changes at the site of operation and the process of healing of the skin wound were also observed.

Post Mortem and Macroscopic Examinations: Special attention was paid to:

* Condition at the ventral aspect of the neck for presence of odema, abscesses and fistulation.
* Adhesions between the oesophagus and the surrounding structures.

* Condition of the oesophageal wound from ouside and inside for the presence of suture material fixed or hanging in the lumen of the oesophagus.
* Formation of a ridge and changes in the diameter of the oesophageal lumen at the site of operation.
* Formation of ulcers or abscesses.
* Healing condition of the oesophageal wound with special reference to the mucous membrane.

Histopathological examination:

Small pieces from the site of operation including the operated and healthy parts were fixed in 10% neutral formalin solution for microscopical examination to study the healing process and histopathological changes of the oesophageal wound.

RESULTS

Clinical picture:

The clinical picture of the experimental animals in the first three groups were similar. At the first few days after the operation some of the experimental animals easily drank milk and water, while others swallowed milk only with difficulty. At the end of the first week the process of drinking returned to normal. Also swallowing process of meat pieces was somewhat difficult at one week after operation but at the end of the second week food prehension improved and appetite became good.

A slight oedematus swelling at the ventral aspect of the neck appeared at the first week then gradually disappeared. Healing of the skin wound was completed at the end of the first week.

The clinical picture of the animals of the fourth group (2 cm. resection) varied from other groups. At the second day after the operation the general condition of the experimental animals was poor with general depression and they lay for a long time in lateral recumbency. Appetite

was lost. Some animals tried to drink milk with great difficulty and immediate vomition was observed. On the third day a large oedematus swelling was developed at the ventral aspect of the neck. Ten out of the twelve animals of this group died (six on the fourth day and four on the fifth). Two animals survived, one was sacrified after one week and the other two weeks after operation. The skin sutures ruptured in one of them forming a fistula. A foamy, purulent discharge mixed with food material and saliva was seen coming from the fistula.

The body temperature increased up to 39.5°C, 2 days after operation and fell below normal before death.

Post-Mortem and Macroscopical Examination:

Postmortem examination of the experimental animals of the first three groups revealed an inflammatory reaction around the operated part of the oesophagus. Slight to severe adhesions between the oesophagus and surrounding structures, especially the trachea, were observed. These adhesions had disappeared or were only seen in small area at the end of the second week. The diameter of the oesophagus at the site of anastomosis was decreased in the first three weeks after operation. There was a small elevated ridge at the site of anastomosis which varied in height between 1 and 1.5 mm. in oesophagostomy (Fig. 1), 1.5-2 mm. after 1 cm. oesophageal resection and 2-4 mm. in cases of 1½ cm. oesophageal resection. The ridge diminished gradually in height and had completely disappeared at the sixth week. Flattening of the oesophageal wound usually occurred with disappearance of the ridge and the edges of the wound were separated from each other by a bare area of mucous membrance which was about 0.5 cm. wide in cases of oesophagostomy and diminished in width gradually till the fifth and sixth week (Figs. 2&3) and appeared to be covered by a mucous membrane. After oesophageal resection the width of this area varied in different specimens between 0.5 and 1 cm. and was not covered by mucous membrane (Fig. 4).

After 2 cm. oesophageal resection a large amount of food material was found subcutaneously and around the oesophagus. Severe inflammatory reaction of the cervical muscles, ruptured oesophgus with lacerated edges and offensive odour were observed.

The animals that survived revealed the same picture of inflammatory reaction and severe adhesions of the oesophagus to the neighbouring structures, especially the trachea. The oesophageal wall healed incompletely and a fistula was recognized (Fig. 5).

Microscopical examination:

The mucous membrane had not been formed on the first and second weeks after oesophagostomy. It began to regenerate at the beginning of the third week to form a thin layer (Fig. 6). It reached its normal thickness at the fifth and sixth weeks post-operation (Fig. 7). It reached its normal thickness at the fifth and sixth weeks post-operation (Fig. 7). After oesophageal resection, the process of regeneration of the mucous membrane began at the beginning of the fourth week as a very thin layer (Fig. 8). On the fifth and sixth weeks it almost reached its normal thickness (Fig. 9).

The layers of musculosa began to be replaced by fibrous tissue. The proliferation of connective tissue began at the adventitia. The connective tissue replaced all layers of the oesophagus, which became more condensed on the fifth and sixth weeks.

After 2 cm. oesophagus resection the mucous membrane did not regenerate in a large area of the wound. All layers were replaced by connective tissue. Blood vessels appeared congested and accompanied by slight haemorrhages.

DISCUSSION

Successful results of cervical oesophageal resections with end-to-end anastomosis depend upon many factors; oesophageal elasticity, type

of suture material used for joining the cut ends of the oesophageal wound, type of suture technique used, length of the resected part, type of the needle, handling procedure and experience of the surgeon in the field of oesophageal anastomosis beside the post-operative care.

On the basis of the results of the present study, it is recommended that the amount of resection of the cervical oesophagus in dogs must not exceed 1.5 cm. in length, taking into consideration the type of suture material, the suture technique and the type of the needle.

Where an oesophageal lesion needs more than 1.5 cm. resection,other methods such as oesophageal grafing or reconstruction must be attempted. This because resection of more than 1.5 cm. in dogs leads to oesphageal rupture with consequent formation of fistulae and even to death.

The healing process of different layers of the oesophagus at the site of the wound varied according to the type of operation performed. After oesophagostomy the mucous membrane regenerated at the third week after operation. When the traction at the end of the oesophageal stumps increased due to resection, regeneration of the mucous membrane occurred only at the fifth or even the sixth week. When the amount of traction became more as in group IV (2 cm. resection), the healing of oesophageal stumps did not occur and the oesophageal wound ruptured.

The absence of mucous membrane until the beginning of the fifth week after 1.5 cm. oesophageal resection may lead to rupture of the operated area when the animal swallows large pieces of food material.

On the basis of the presented findings it is recommended to give easily swallowable small pieces of meat to the operated animals after 1.5 cm. oesophageal resection.

Concerning the process of healing of other layers of the oesophagus at the site of the wound, all layers of the oesophageal wall was replaced by dense connective tissue. The larger the distance between the edges of the oesophageal wound, the more the amount of C.T. formation. The

submucosal oesophageal glands were completely obliterated and replaced by connective tissue after all the oesophageal operations.

In the tubular parts of the alimentary tract the risk of stenosis as a result of end-to-end anastomosis is expected. The idea is different in the case of oesophageal anastomosis. An explanation may be that the flattening that occurs at the site of wound i.e. absence of stenosis could be attributed to the following:

1) The increase in tension on the line of the anastomosis as a result of shortening of the oesophagus, as well as the inversion of the edges of the two stumps after suturing.

2) Peristaltic movement of the oesophagus during swallowing.

3) Weakness and friability of the catgut one week after operation helped the oesophageal ends to separate from one another to compansate the loss of tissues.

In spite of the danger of flattening of the oesophageal wound and absence of mucous membrane at the site of healing, no complications occurred in the first three groups of animals, i.e. up to 1.5 cm. oesophageal resection.

The clinical picture of animals with oesophageal anastomosis and resection indicated that these animals can tolerate the resection up to 1½ cm. The swallowing and drinking processes appeared to be somewhat difficult only at the first two weeks and then became normal. These results are in agreement with those given by WRIGHT (1926), KNIGHT (1951) and MISK (1974).

The surgical wounds of the oesophagus, muscles and skin of the neck in the first three groups healed without any complications. This result was in contrast to the reports of many authors O'CONNER, (1956) PAKER and SAYER (1958) and SHUTTLEWORTH and SMYTHE,(1960), who advised leaving the cervical wound open with or without suturing the oesophageal wound.

RESECTION OF THE CERVICAL OESOPHAGUS

The swelling at the ventral aspect of the neck in the first two weeks after the operation may be due to the inflammatory reaction and usually disappeared later.

REFERENCES

Baker,G.J. and Hoffer,R.E. (1966): Surgical correction of oesophageal stenosis in the dog. J.A.V.M.A. 148: 44-47.

Belsey,R. (1965): Reconstruction of the oesophagus with left colon. J. Thoracic and Cardiovasc. Surg. 49: 33.

Bennett,R.R. and Zydeck,F.A. (1970): A comparison of single layer suture patterns for intestinal anastomosis. J.A.V.M.A., 157: 2075.

Colgrove,D.J. (1971): Transthoracic oesophageal surgery for obstructive lesion caused by Spirocerca lupi in dogs. J.A.V.M.A., 158: 2073-2076.

De Olivira,J. (1955): "Tratamento tirurgo megaesogage Pesfincterectamia esofagocardica", Tecnica a tatica passaal.J.O.A.O. An paulist. med. e. Cir., 70: 351.

Ellis,F.E.; Jr.Anderson;H.A. and Clagett,O.T. (1958): Treatment of short oesophagus with stricture by oesophagogastrectomy and antral excision. Ann. surg., 148 - 256.

English,P.B. (1959): Transthoracic oesophagotomy in a cat. Aust.Vet. J., 35: 41-43.

Hall,L.W.(1974): Wright's Veterinary Anaesthesia and Analgesia. 7th. Ed. London, Bailliere Tindall and Cassell.

Harrison,D.F. (1972): The surgery of some strictures and stenosis of upper oesophageal strictures. Ann. Roy. Coll. Surg. Eng.,50: 303- 304.

Knight,G;c; (1951): The diagnosis and treatment of oesophageal impaction in dogs with special reference to transthoracic oesophagotomy. Vet. Rec., 63: 543 - 548.

Knight,G.C. (1963): Transthoracic oesophagotomy in dogs: a survey of 75 operations. Vet. Rec., 75: 264 - 266.

Misk,N.A. (1973): Effectiveness of different type of suture for use in surgery of the oesophagus and intestine of dog and sheep. Sbornik Nauchnykh Trudov, Moskovskaya Veterinernaya Akademiya, 89 part 1 : 45 - 47.

Misk,N.A. (1974): Comparison and evaluation of trials to extract foreign bodies from digestive tract of animals. Thesis, Moscow.

Misk,N.A. and Hifny,A. (1976): Surgical exposure of the cervical oesophagus in some domestic animals. Proc. of 13th. Arab Vet. Med. Congr. 317-334. Cairo 13-16 Nov.

O'Connor,J.J. (1965): Dollar's Veterinary, Surgery 4th. Ed., Bailliere, Tindall and Cox, Ltd. London.

Paker,C.W. and Sayer,A. (1958): Oesophageal rupture in a standard breed mare.J.A.V.M.A. 133: 371 - 373.

Plakhotin, M. V. (1946): Sero-muscular intestinal suture. Voenn - Veterinarnaya sbornik 15 - 17, Moscow.

Pribram, Bio. (1922): Zur Pathologie und Chriurgie derpastischen neurosen. Arch. Klin. Chir. 120 : 207.

Shuttleworth, A.C. and Smythe, R.H. (1960): Clinical Veterinary Surgery Vol. 2. Operative Surgery, Crosby Lockwood, London.

Singh,J. and Tyagi,R.P.S.(1972): Experimental studies on the oesophageal anastomosis with special reference to transplantation in buffalo calves. Indian V.J. 49 No. 8 : 814 - 821.

Thrasher,J.P.; Ichinsoe,H. and Pitot,H.C. (1963): Am.J.Vet. Res. 24:100.

Wright, J.G. (1926): Intrathroacic oesophageal obstruction in the dog. Presternal oesophagotomy. Vet.J.Vol. 89: No. 3 : 113-118.

(Fig. 1) : One week specimen (Group 1, oesophagostomy) showing an elevated ridge between the edges of the oesophageal wound.

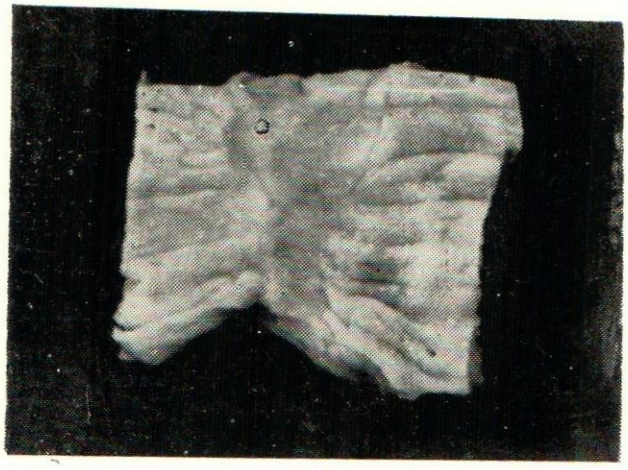

(Fig. 2) : Four weeks specimen (Group 1, oesophagostomy) showing the area devoid of mucous membrane still present between the edges of the wound.

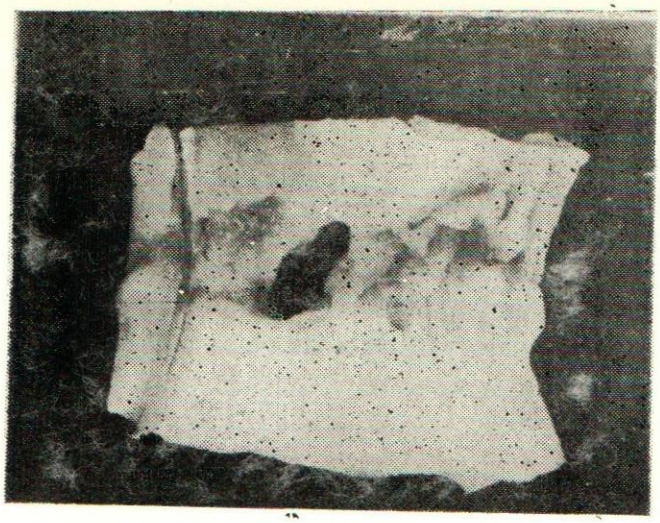

(Fig. 5) : Two weeks specimen (Group IV-2 cm oesophageal resection) showing presence of a fistula and area devoid of mucous membrane separating the edges of the oesophageal wound.

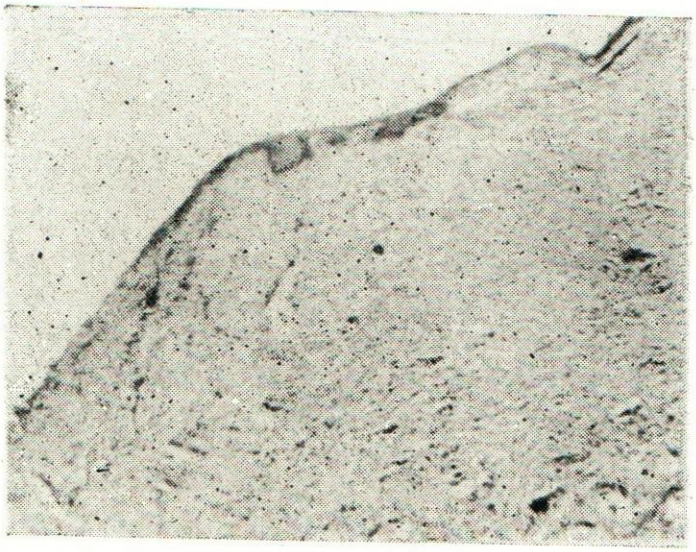

(g. 6) : Formation of the mucous membrane as a thin layer 3 weeks following the operation (Group 1 oesophagostomy) (H & E - X 12.5 x 6.3).

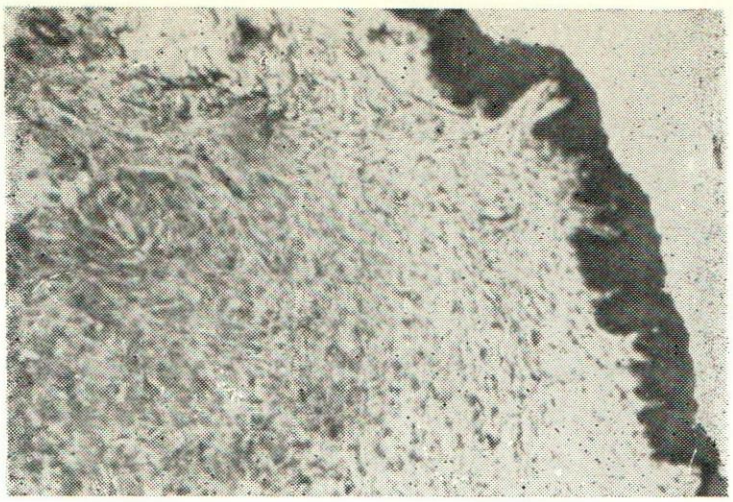

(Fig. 7) : Complete formation of thin mucous membrane 6 weeks after operation (Group 1·oesophagostomy) (H & E·X 12.5 x 6.30).



(Fig 8) : Encroachment of the m.m. over the C.T. filling the space between the edges of the oesophageal wound 3 weeks after the operation. (Group 11·1 cm. oesophageal resection) (H & E, X 12.5 x 16).