قسم الجراحة - كليتى الطب البيطرى - جامعتى أسيوط والزقازيق .
رئيسى القسم : أد . محمد المصطفى منزلى ، أ.د / سيد الصواف .

دراسة مقارنة للطرق الجراحية لاستئصال الطحال فى الحمير

محمود طنطاوى ، عاطف بلبل ، تيسير سامى

تم محاولة استئصال الطحال بواسطة ثلاث طرق مختلفة فى الحمير ومكان الجراحة : بعد ازالة الضلع الأخير - بعد ازالة الضلع السابع عشر أو فى المنطقة الفارغة .

ولقد اجريت جميع الجراحات فى الحمير فى الوضع واقفا .

ولقد تمت العمليات الجراحية بنجاح تام تحت تأثير الكومبلين للتهدئة قبل العملية بجانب التخدير بالحقن الموضعى مستخدما توتوكايين .

ولقد وجد أن أسهل الطرق الثلاث لاستئصال الطحال فى الحمير بعد ازالة الضلع السابع عشر حيث أنه يعطى فراغا كافيا لربط الأوعية الدموية للطحال .

Dept. of Surgery,
Faculty of Vet. Med. Assiut & Zagazig University,
Heads of Dept. Prof. Dr. M. Monzaly & Prof. Dr. S. El-Sawaf.

COMPARATIVE TECHNIQUES FOR SPLENECTOMY IN DONKEYS

(With 5 Figures)

By

M. TANTAWY, A.E. BOLBOL and M.T. SAMY

(Received at 16/9/1980)

SUMMARY

Three operative techniques for splenectomy in donkeys were tried. The operation sites were,after resection of either the last ribe,or the 17th rib,and in the flank region. The operations were performed in the standing position.

All the operations were successfuly performed under the effect of Combelen as a premedication and Tutocain local infiltration anaesthesia.

The easiest way for splenectomy in donkeys was after resection of the 17th rib as it gave enough space for ligating the splenic vessels.

INTRODUCTION

Splenectomy is sometimes used for research work and usually indicated in cases of affections of the spleen especially after its injury through accidental perforating abdominal wounds.

QUINLAN, DE KOCK and MARARIS (1935) performed splenectomy in horses through a left vertical flank incision on the recumbent position 5 cm caudal to the last rib, under the effect of i.v. infusion of chloral hydrate and chloroform inhalation anaesethia.

Splenectomy in equines was tried with success by WITZEL and MULLENAX (1964) who performed the operation after resection of the last three ribs, using promazine as a premedication followed by adminstration of Halothan-Oxygen mixture.

DENNIG and BROCKLESBY (1964) described a simple technique for splenectomy in horses and donkeys after resection of the 17th left rib using chloral hydrate narcosis together with local anaesthetic (Zylotox).

Splenectomy in donkeys was tried with success after resection of the last rib, under the effect of Combelen and Procaine HCl 1% local infiltration anaesthesia (TANTAWY,1976) who doscribed the said technique over 6 animals.

MATERIAL AND METHODS

Fifteen clinically healthy donkeys were used in this investigation. The animals were of different age, sex and body weight. They were classified into three groups according to the site of operation.

The first group comprised six donkeys. They were operated after resection of the last rib.

The second group comprised six animals and splenectomized after resection of the 17th rib.

The third group (3 donkeys) was performed in the flank region three fingers posterior to the last rib.

All animals were kept for eating as usual. The operations were performed after tranquilization of the animals by i.m. injections of 1% Combelen in doses of 0.023 ml/Kg b wt as recommended by TANTAWY et al. (1979) and application of 2% Tutocaine as local infiltration anaesthesia.

The operation site for aseptic operation was prepared. A skin incision was made over the last rib and began at its dorsal extremity and continued downwards to the cost-chondral junction. The rib was then resected completely. The underlying tissues and peritoneum was incised, where the posterior half of the spleen become clearly visible,Exposure of the gastrosplenic vessels were made clear by bringing the apex of the spleen outside the flank incision (Fig. 1&2). The gastresplenic vessels were ligated by No. 2 chromic catgut and dissected except at the base of the spleen.

The suspensory ligament was separated carefuly. The base of the spleen was rotated cranio-laterally to dissect the renolinal ligament, where its medial and lateral parts were transected separately. Rotation of the spleen now

caudo-laterally facilitates the exposure of the main splenic vessels which could be ligated with two ligatures using chromic catgut No. 2 and cut inbetween, the removal of the spleen is accomplished.

The laparotomy incision was closed as the usual manner.

Splenectomized animals were given i.m. dose of Penicillin-Streptomycin together with i.v. dextrose 25% daily for five successive days.

The second group was operated after resection of the 17th rib (Fig. 3&4). The operation was performed as the above mentioned method. In this technique the base and the apex of the spleen were completely visible. Dissection of the splenic ligament as well as ligation of the splenic vessels were easily performed than in the above method.

The third group was perfomed behind the last rib in the flank region, by making a dorso-ventral incision (Fig. 5). The spleen is partially shown especially when the stomach is filled with food, which usually pushes the spleen posteriorly. It is difficult to dissect the splenic ligaments and ligate the vessels.

RESULTS AND DISCUSSION

All operated animals withstood the operation perfectly. Combelen proved satisfactory as a premedication to keep the animal in the standing position. Also, Tutocain 2% as a local infiltration anaesthesia gave the desired effect.

The technique of splenectomy following resection of the 17th or 18th ribs was nearly similar to that described by DENNIG and BROCKLESBY (1964) and TANTAWY (1976). The obtained results for flank splenectomy contradict with the results obtained by QUINLAN et al.(1935), because it was difficult to reach the splenic vessels in order to ligate them.

Surgical resection of the 17th rib was similar to that described by WITZEL and MULLENAX (1964) who operated on the spleen after resection of the last three ribs, however their method consumed more time. In the present work it was noticed that resection of the 17th rib only gave an ample space for handling the spleen and operating thereon. Finally one can easily conclude that splenectomy in donkeys following resection of the 17th rib surpasses other methods.

REFERENCES

Dennig,H.K. and Brocklesby,D.W. (1964): Splenectomy of horses and donkeys. Vet. Rec. 77: 40-44.

Quinlan,L.G., De Kock and Mararis,I.P. (1935): The operation of splenectomy in horses, cattle, sheep, goats, pigs and some south african antelopes. A summary of the results of 98 splenectomies.The Onderpoost J.Vet.Med. Sci. industry, Vol. 5, No. 1.

Tantawy, M. (1976): Approach to laparotomy in equines (Eques Asinus) in the standing position under the effect of tranquillizers and local anaesthesia. Thesis, M.V.Sc., Assiut University, Assiut, A.R.Egypt.

Tantawy,M., Bolbol,A.E. and Mottelib,A.A. (1979): Studies on the clinical use of some tranquillizers in donkeys. Vet.Med. Rev. 2: 106-114.

Witzel,D.A. and Mullenax,C.H. (1964): A simplified approach to splenectomy in horses. Cornell Vet., 54: 628-636.

Fig. (1)



Fig. (2)

(Fig. 3)

Fig. 1: Apex of the spleen shown through the flank incision after resection of the 18th rib.

Fig. 2: The spleen outside the flank incision after resection of the last rib.

Fig. 3: The 17th rib was shown through the flank incision.

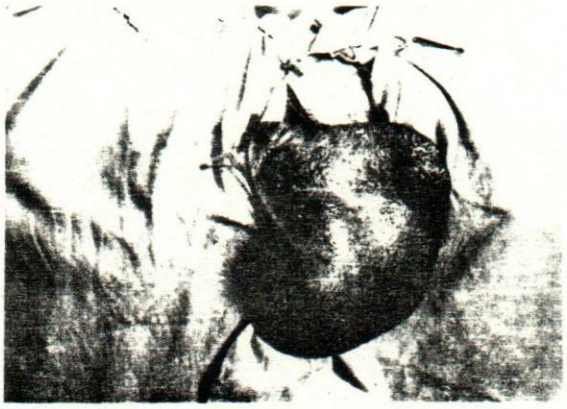

Fig. 4: The spleen seen outside the laparotomy incision after resection of the 17th rib.

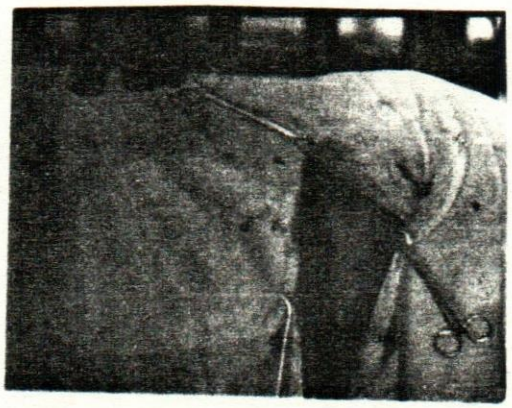

Fig. 5: The flank incision behind the last rib.