قسم : الجراحـــة
كلية الطب البيطرى ـ جامعة أسيوط
رئيس القسم : ا.د / نبيل أحمد مسك

التشريح الجراحى للرغام فى بعض الحيوانات الأليفة

نبيل مسك ، فتحى مكادى ، تيسير سامى * ، عبد الله حفنى **

لما كانت المعلومات والخصائص التشريحية فى الحيوانات الأليفة بمثابة أساس يرتكز عليه أجراء أيلاج أنبوبة رغامية للتخدير بالأستنشاق لتلك الحيوانات وكذلك أجراء بعض العمليات الجراحية فى الرغام . لذلك تم فى هذا البحث دراسة التشريح الجراحى للرغام فى الجمال والجاموس والأبقار والخيول والبغال والحمير والأغنام والماعز والكلاب والقطط .

شملت هذه الدراسة قياس الطول الكلى والعنقى والصدرى للرغام ، أحصاء عدد حلقاته العنقية والصدرية ، قياس متوسط العرض لحلقاته المختلفة وقياس قطره الداخلى والخارجى فى المستويات المختلفة .

نوقشت النتائج لبيان أهمية دراسة الخصائص التشريحية للرغام ومدى الأستفادة منها عند أختيار أنبوبة رغام مناسبة وكذلك أجراء العمليات الجراحية المختلفة فى الرغام .

---

* قسم الجراحة ـ كلية الطب البيطرى ـ جامعة الزقازيق
** قسم التشريح ـ كلية الطب البيطرى ـ جامعة أسيوط

Dept. of Surgery,
Faculty of Vet. Med., Assiut University,
Head of Dept. Prof. Dr. N.A. Misk.

SURGICAL ANATOMY OF THE TRACHEA IN SOME DOMESTIC ANIMALS

(With 3 Tables & 9 Figs.)

By
N.A. MISK; F.M. MAKADY; M.T. SAMY* and A. HIFNY**

(Receiced at 12/1/1986)

SUMMARY

Certain anatomical features of the trachea are important for endotracheal intubation, tracheostomy and tracheal resection.

Some authors (MILLER, et al. 1964; AKAEVSKY, 1968; MAY, 1970; NICKEL, et al. 1973 and SISSON and GROSSMAN, 1975) have been described the trachea in some domestic animals but without indicating the external diameter, internal diameter, width of tracheal rings, length and number of tracheal rings.

The available literatures about the anatomy of the trachea in camel, buffalo, mule and donkey are meagre (DROANDI, 1936 and GEORGI, 1951).

The aim of the present work is to study some anatomical features of the trachea which have an important for endotracheal intubation and tracheal surgery in general.

MATERIAL and METHODS

The surgical anatomy of the trachea was studied in camel, buffalo, cow, horse, mule, donkey, sheep, goat, dog, and cat. 3-15 tracheas from each species were collected from the slaughterhouse or obtained from newly sacrified animals. Each sample was examined freshly for some morphological features including:

1- Total length of the trachea (from the cricoid cartilage to the carina) and the length of its cervical and thoracic parts seperately. +

2- Total number of the tracheal rings and the number of tracheal rings in the thoracic and cervical parts.

3- The width of tracheal rings.

4- The external and internal diameters of the trachea in a dorsoventral and transverse lines were measured at different levels (tracheal rings No. 2, 5, 10 ....etc) and the averages were calculated.

---

* Dept. of Surgery, Fac. of Vet. Med., Zagazig Univ.
** Dept. of Anatomy, Fac. of Vet. Med., Assiut Univ.

\+ A scaple puncture was performed at the annular ligament between the two tracheal rings at the level of the first rib to determine the line of demarkation between the cervical and thoracic parts.

Also the tracheal ring No. 2, 5, 10, 15, 20 ....etc for each species were collected and photos were taken to illustrate the shape of the tracheal lumen along its whole length.

RESULTS

The averages of the values of different measurements of the length of the trachea, number and width of the tracheal rings are illustrated in table one. The external and internal diameters of the trachea in a dorsoventral and transverse lines are illustrated in table two. Figures 1-9 illustrate the shape of tracheal lumen in different domestic animals at different levels.

DISCUSSION

Knowledge about the length and internal diameter of the trachea in different domestic animals are important for determination of different sizes and lengths of endotracheal tubes used for inhalation anaesthesia. The total length of endotracheal tube for each animal can be calculated without additional external dead space if the distance between the cricoid cartilage and the oral orifice was estimated and added to the whole length of the trachea given in table 1.

Different sizes of endotracheal tubes were designated by one of five systems stated by SAMA (1971), namely; the french catheter gauge, the Magill number, the Davel scale, the internal diameter in millimeter and the external diameter in millimeter. The Association of Veterinary anesthetists of great Britain and Treland has established the essential requirements for veterinary endotracheal tubes in farm animals as seen in table III. Our results are not in consequent with that given by the Association concerning the external diameter of endotracheal tubes in millimeters in most farm animals. The internal diameters of the trachea given in table 2 are less than the external diameter of the endotracheal tubes established by the association.

HALL (1974) stated that 30mm external diameter of endotracheal tube is adequate for small thoroughbreds, 25mm tube is suitable for cattle of about 450 Kg body weight, 16mm tube for large sheep and calves, 11-12mm tube are adequate for most adult goats and 12-16mm tube for dogs. These results are more or less in consequent with our data given for such animals if compared with the external diameter of the trachea given in table 2.

Moreover, it is interesting to established that the shape of the tracheal lumen is differs from one species to another. In general, the trachea of equine is flattened dorsoventrally and the tracheal lumen is nearly elliptical in a transverse line while the trachea of the cow, sheep and goat are contracted laterally with nearly rounded tracheal lumen. The trachea of the camel and buffalo are more or less flattened dorsoventrally with nearly rounded tracheal lumen. Such variations in the shape of the tracheal lumen can be taken in consideration during designation and manufacturing the shape of endotracheal tubes. This may facillitate the process of intubation and reduce any additional presure of the inflatted cuff on one place of tracheal mucous membrane more than the other. Excessive or unequal pressure of the inflatted cuff on the mucous membrane of the trachea may leads to ulcerastion or stenosis (BRYANT, et al. 1971; KNECHT, et al. 1972 and GORDON, 1973).

SURGICAL ANATOMY OF THE TRACHEA

At the mean time the external diameter of endotracheal tubes for camel, buffalo, mule and donkey can be suggested according to the data given in table 2.

Small or massive tracheal resections are indicated for the treatment of some congenital and acquired surgical affections of the trachea such as hypoplasia,diverticulum, collapse, wounds, fistulae, tracheomegally, fracture and neoplasms (CULP, 1938; BROWN and LUMB, 1958; SCHEBITZ, 1960; SHAFF, 1963; JACKSON, 1965; SCOT, 1978 and BEDORD, 1982). Knowledge about the number of cervical and thoracic tracheal rings seperately are important for determination of the number of tracheal rings resection when it is dictated.

Moreover, the width of tracheal rings is essential for determination of the diameter of the surgical wound needed for application of a perminant tracheal tube in different domestic animals. The diameter of the crown of a perminant tracheal tube must not be larger than the transverse diameter of the trachea. Also the width ofthe flattened part of the temporary tracheal tube must not exceed the inner diameter of the trachea in a transverse line otherwise fracture and massive distruction of the trachea will resulted during its introduction.

As a conclusion it should be emphasized that knowledge about the surgical anatomy of the trachea in different domestic animals is essential for safety endotracheal intubation and correct surgical interference sithout unsuspected complications.

REFERENCES

Akaevsky, A.E. (1968): The anatomy of the domestic animals. Kolos, Moscow.

Bedford, P.G.C. (1982): Tracheal hypoplasia in the English bulldog. Vet. Rec. III. No. 3: 58.

Brown, J.D. and Lumb, W.V. (1958): Tracheal obstruction in a dog. J.A.V.M.A. 15: 521.

Bryant, L.R.; Trinkle, J.K. and Dunilier, L. (1971): Reappraisal of tracheal injury from cuffed tracheostomy tube. J.A.V.M.A. 212: 625.

Culp, O.S. (1938): Primary carcinoma of the trachea. J. Thorac. Surg. 7: 471.

Droandi, I. (1936): Il Cammelo, Firenze. Instituto agricalo Coloivala Itabano, Firenze 1.

George, A.N. (1951): The respiratory system in the camel.' Thesis. Fac. Vet. Med., Cairo Univ.

Gordon, W. (1973): Surgical correction of tracheal stenosis in a dog. J.A.V.M.A. 162: 479.

Hall, L.W. (1974): Wright's veterinary anaesthesia and analgesia. Seventh edition. Bailliere, Tindall. London.

Jackson, R.E. (1965): Cited by Done, S.H.; Clayton-Jones, D.G. and Price, E.K. J.A.V.M.A., 146: 517 (1970).

Knecht, C.D.; Schall, W.D. and Barrett, R. (1972): Iatrogenic tracheostenosis in an dog J.A.V.M.A. 160: 1427.

May, N.D.S. (1970): The anatomy of the sheep 3rd Ed. University of Queensland press.

Miller, M.E.; Christensen, G.C. and Evans, H.E. (1964): Anatomy of the dog. Philadelphia. W.B. Saunder company.

Nickel, R.; Schummer, A. and Seiferle, E. (1973): The visera of the domestic mammals. Verlag Paul Parey. Berlin. Hamburg.

Schebitz, H. (1960): Rontgenbefund einer oesophagotracheal fistel nach Fremdkorper perforation beim hund. Tieraztl. Umsch 15: 87.

Scott, E.A. (1978): Ruptured trachea in the horse: a method of Surgical reconstruction. Vet. Med. Small animal clinician 4: 485.

Shaff, S.J. (1963): A plastic adhesive for nonsuture repair of tracheal wounds. J.A.V.M.A. 143, No. 2: 158.

Sisson, S. and Grossman, J.D. (1975): Anatomy of domestic animals. Rev. By R. Getty, 5th Ed., W.B. Saunders Co., Philadelphia, London, Toronto.

Soma, L.R. (1971): Textbook of veterinary anaesthesia. The Williams and Wilkins Company. Baltimore.

Table (I)

Showing the length of the trachea, number and width of the tracheal rings in certain domestic animals

	No. of tracheal rings (average)			Length of the tracheal (cm)			width of the tracheal rings. (average in mm)
	Total	Cervical	Thoracic	Whole	Cervical	Thoracic	
Camel	65.0	45.0	20.2	89.2	68.2	21.0	11.8
Buffalo	50.2	33.0	17.0	57.0	39.6	17.4	9.8
Cow	50.0	29.0	21.0	48.0	32.0	16.0	8.9
Horse	56.0	40.0	16.0	70.0	50.0	20.0	10.8
Mule	52.0	37.0	15.0	64.0	43.0	21.0	10.2
Donkey	45.7	31.6	14.1	45.7	32.6	13.1	7.8
Sheep	50.0	26.0	24.0	29.0	16.0	13.0	4.5
Goat	55.0	35.0	20.0	26.0	16.0	10.0	4.2
Dog	40.0	24.0	16.0	17.0	10.0	7.0	4.0
Cat	46.0	28.0	18.0	10.5	7.0	3.0	1.5

Table (II)

The transverse and dorsoventral measurements of the external and internal diameters of the trachea in certain domestic animals, (average in mm)

		Camel	Buffalo	Cow	Horse	Mule	Donkey	Sheep	Goat	Dog	Cat
External	Transverse	36	55	35	55	47	37	24	17	21	10
diameter	Dorsoventral	35	45	52	48	36	29	30	19	17	7
Internal	Transverse	32	46	25	47	39	32	20	12	19	8
diameter	Dorsoventral	27	37	30	25	20	20	18	13	16	6

Table (III)

External diameter of veterinary endotracheal tubes for farm animals (Recommendations of the Association of Veterinary Anesthetists of Great Britain and Ireland) stated by Soma 1971

External diameter (millimeters)	Animal
43	Large thoroughbred horses
38	Thoroughbred horses, Bull and Large Cows
31	Large and medium ponies and most Cows
26	Medium and small ponies and yearling Cattle
22.5	Large rams and 6 months calves
19.5	Adult sheep
17	Yearling sheep
15	Younger sheep and newborn calves

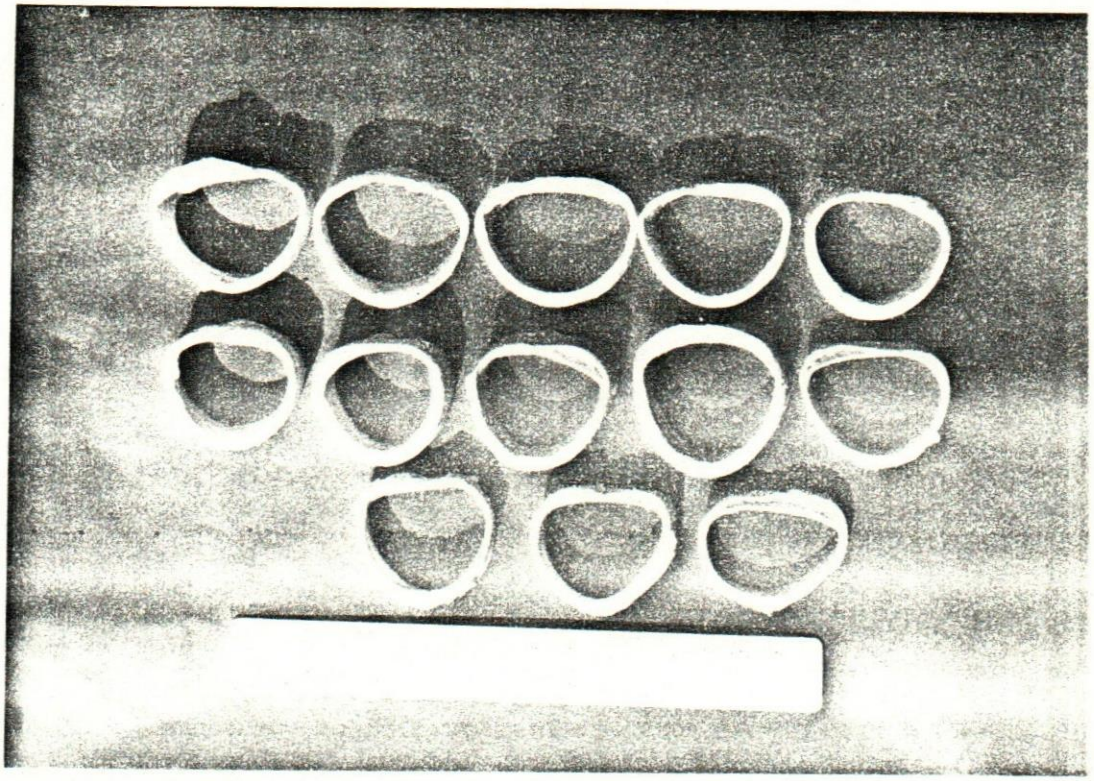

Fig. (1)
The tracheal rings No. 2,5,10,15,20,25,30,35,40,45,50,55 and 60 in camel

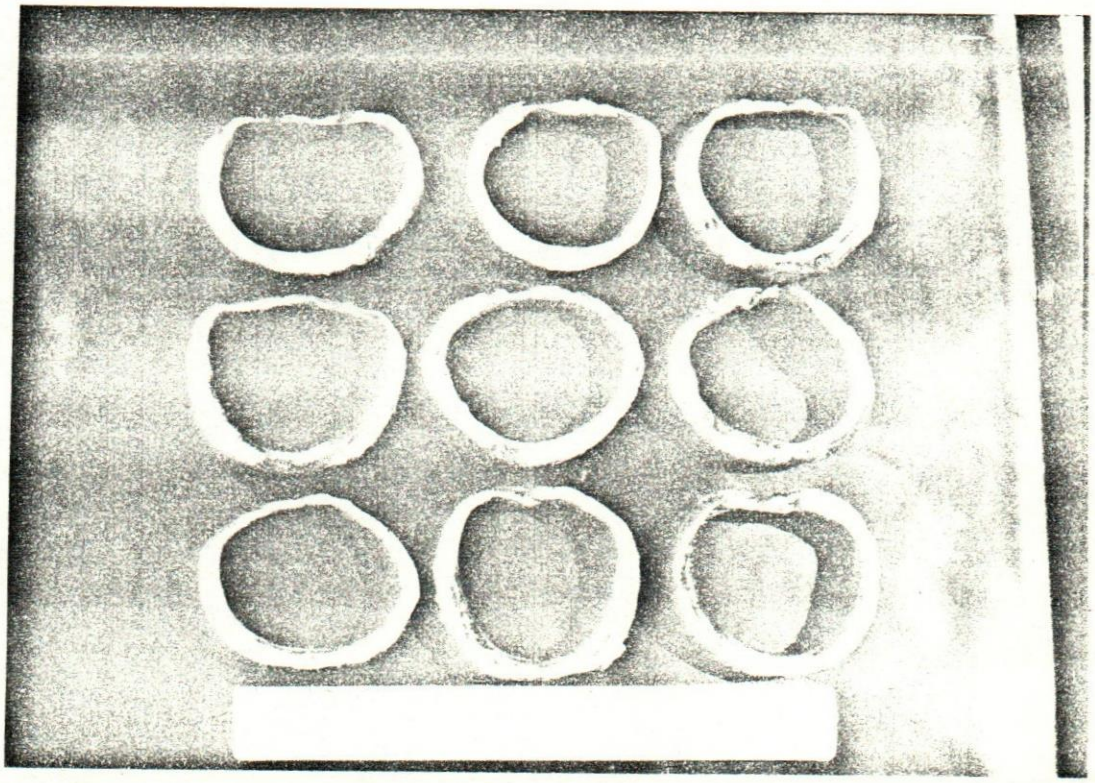

Fig. (2)
The tracheal rings No. 5,10,15,20,25,30,35,40 and 45 in a buffalo to show the shape of the tracheal lumen along its whole length

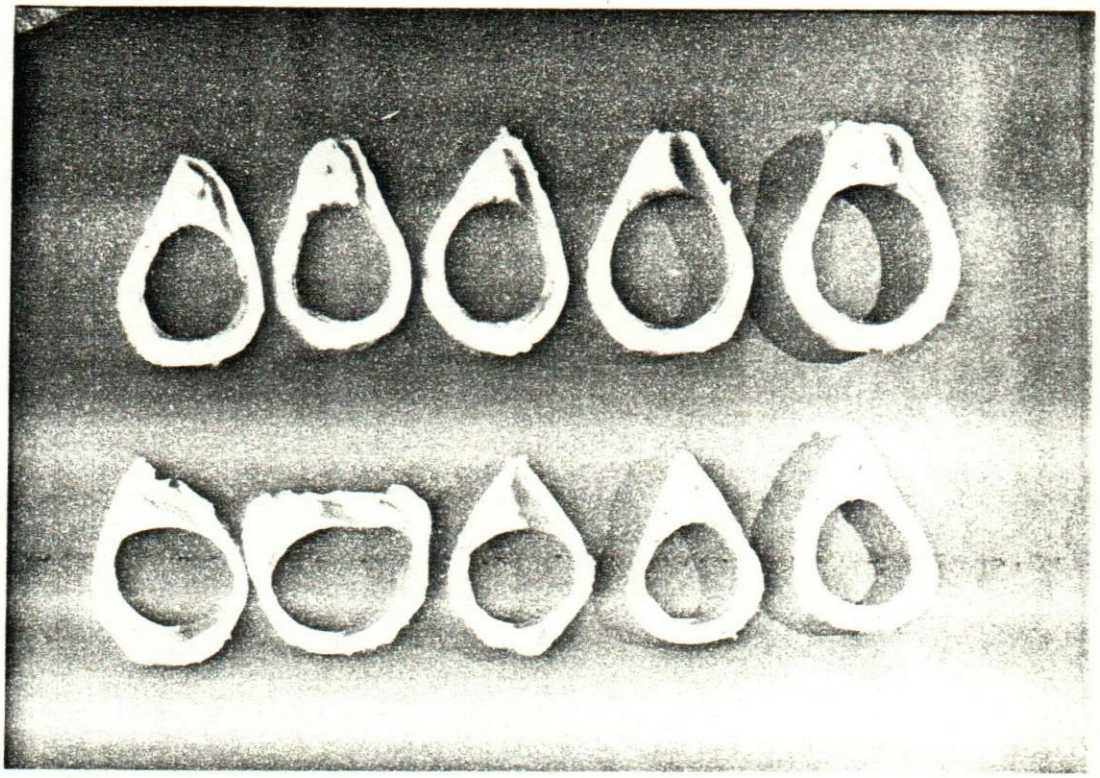

Fig. (3)
The tracheal rings No. 2,5,10,15,20,25,30,35,40 and 45 in a cow

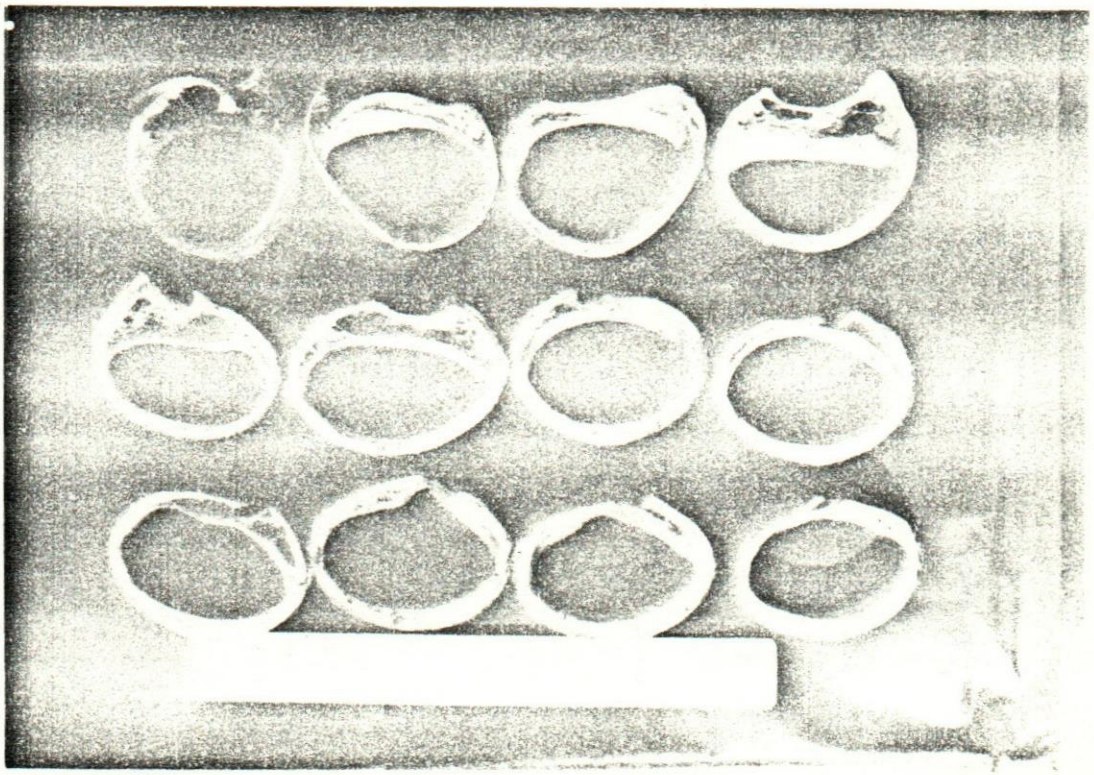

Fig. (4)
The tracheal rings No. 2,5,10,15,20,25,30,35,40,45,50 and 55 in a horse

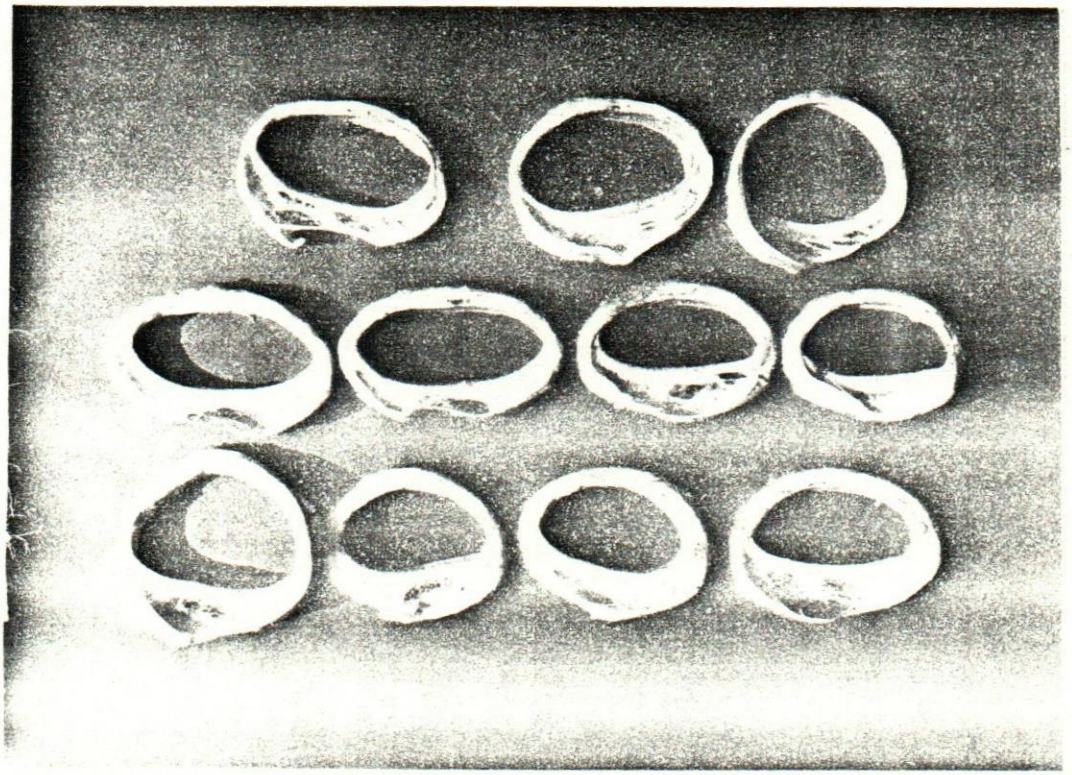

Fig. (5)
The tracheal rings No. 2,5,10,15,20,25,30,35,40,45 and 50 in a mule

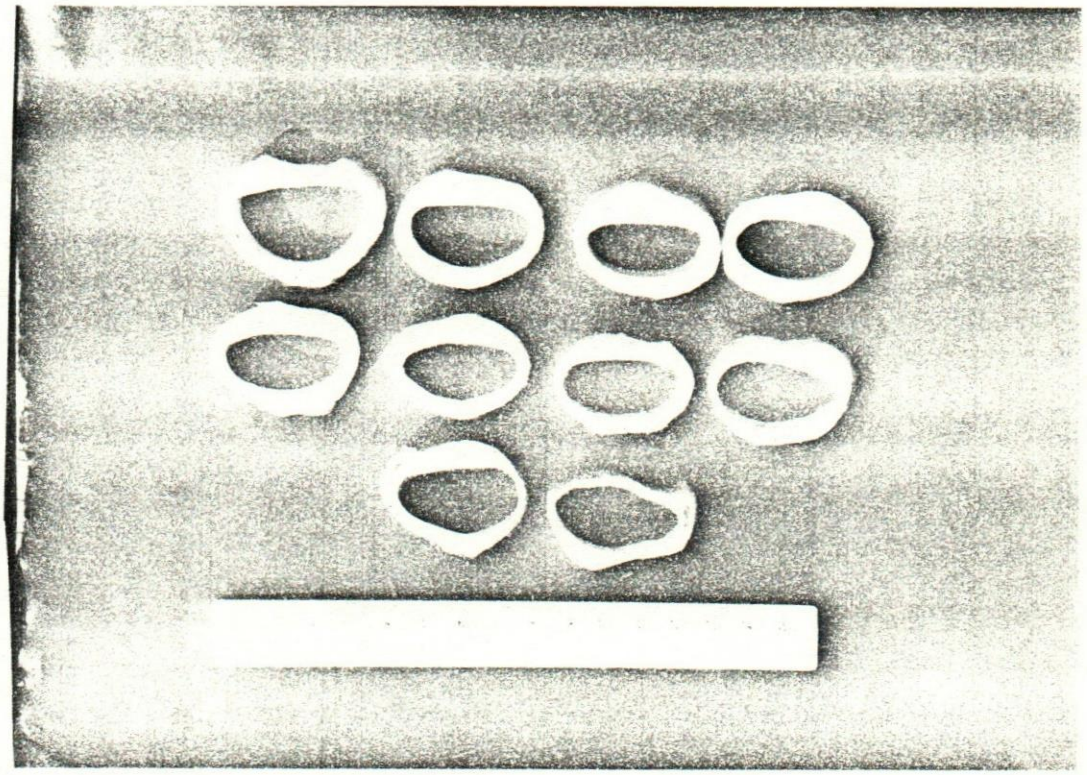

Fig. (6)
The tracheal rings No. 2,5,10,15,20,25,30,35,40 and 45 in a donkey

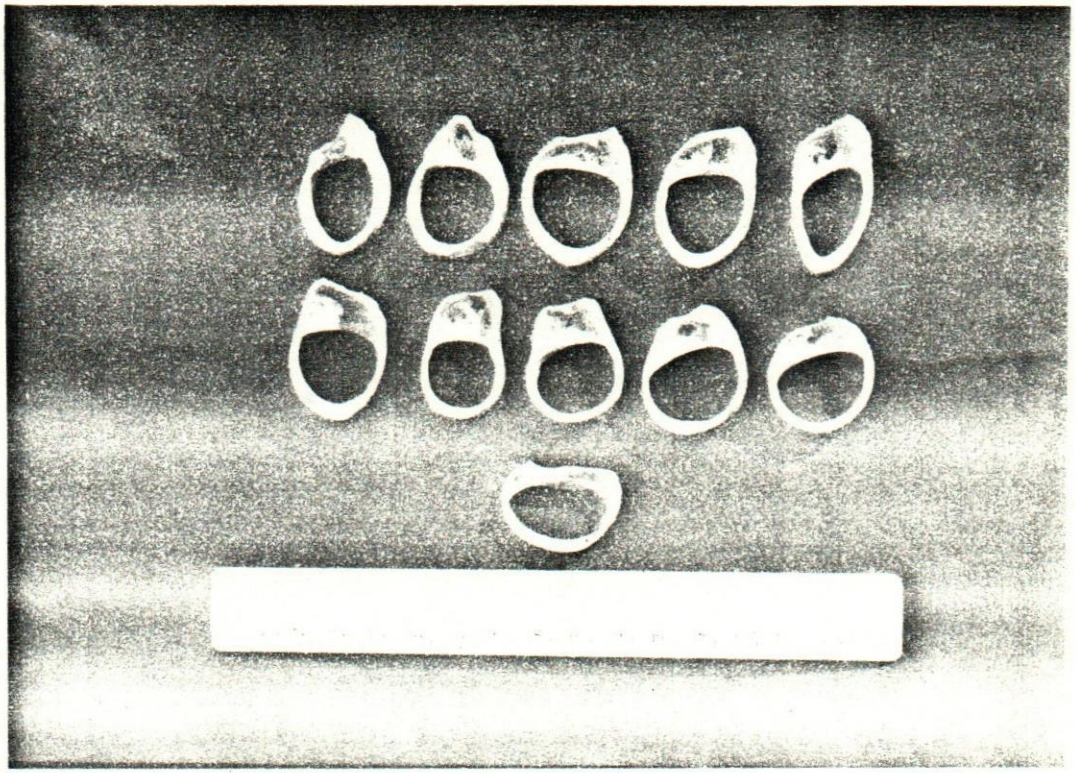

Fig. (7)
The tracheal rings No. 2,5,10,15,20,25,30,35,40,45 and 50 in sheep

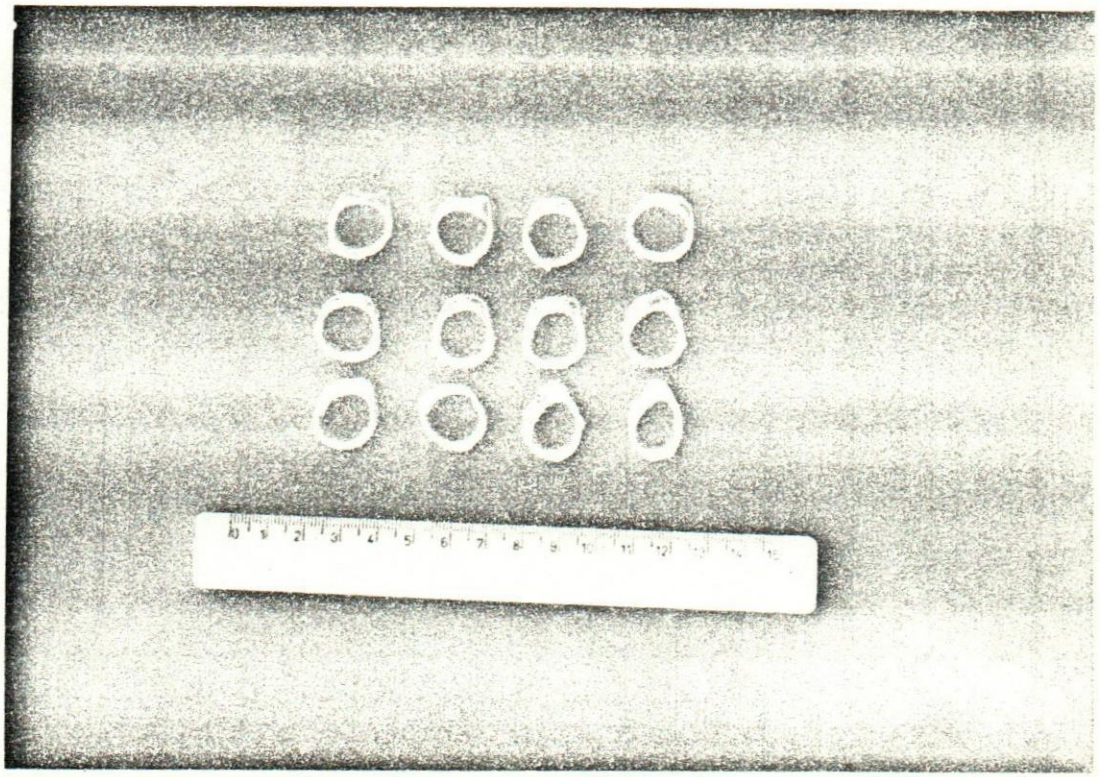

Fig. (8)
The tracheal rings No. 2,5,10,15,20,25,30,35,40,45,50 and 55 in goat



Fig. (9)
The tracheal rings of a dog (A) No. 2,5,10,15,20,25,30 and 35
and of a cat (B) No. 2,5,10,15,20,25,30,35,40 and 45