قسم الباثولوجيا
كلية الطب البيطري ـ جامعة أسيوط
رئيس القسم : أ٠د/ حمدي عبدالعزيز سالم

دراسة التأثير الباثولوجي والتغيرات الباثولوجية لفطر الباسيلوميسز في الكتاكيت الفيومي

محمود عبدالظاهر ، عبدالفتاح البدري *

تم حقن ٤٠ كتكوت فيومي على ثلاث أيام بفطر الباسيلوميسز المعزول من الفراخ الفيومي النافقة ٠ وقد لوحظت التهابات مزمنة في الاكياس الهوائية والأغشية الرقيقة والرئة والكبد ٠ وقد وجد أن الفطر له تأثير باثولوجي خطير على الكتاكيت الفيومي حيث وصلت نسبة النفوق الى ٤٥٪ ٠

* معهد بحوث صحة الحيوان ـ قنا

Dept. of Pathology,
Fac. of Vet. Med., Assiut University,
Head of Dept. Prof. Dr. H.A. Salem.

EXPERIMENTAL STUDY OF THE PATHOGENICITY AND PATHOLOGIC PICTURE OF PAECILOMYCES SPECIES ISOLATED FROM THE LUNG OF DEAD FAYOUMI CHICKENS

(With 8 Figures)

By

A.Z. MAHMOUD and A.A. EL BADRI*

(Received at 31/10/1987)

SUMMARY

Fourty fayoumi chicks (three days old) were inoculated with paecilomyces species isolated from the lung of dead fayoumi chickens. The purpose was to study the pathogenicity and pathologic picture of this fungus in Fayoumi chickes. Focal granulomatus inflammation was observed in the serous membranes, Lung, liver and heart. granulomas in the liver, lung and heart were small in size and were frequently encapsulated. Paecilomyces species isolated from the lung of dead chickens were highly pathogenic for Fayoumi chicks causing deaths of 45% of it.

INTRODUTION

During the last few years poultry population has been considerably increased in Egypt. From the economic point of view, avian mycosis considered as an important infection due to its high morbidity and mortality in poultry farms. Pathogenic fungi has been isoalted by many workers from the digestive and respiratory tract as well as from the surrounding environment of poultry in different parts of the world ALLER (1967); SHARMA et al. (1971) JAND and DHILLON (1973) and EL-BADRI (1979). Pathogenic paecilomyces fspecies were isoalted from different sources including, respiratory tract of fowl with gross lesions, broder houses, equipment, duck ration, egg inocubators and hatcheries (SHARMA et al., 1971; RAJAN and SIVADAS, 1971; REFAI et al., 1976 and SAIF and ABOUL-KIER, 1970). EL-BADRI (1979) could isolated paecilomyces from crop and lung of turkey poults. The purpose of this investigation was to study the pathogenicity and pathologic picture of paecilomyces species isolated from the lung of dead Fayoumi chickens.

MATERIAL and METHODS

Fourty Fayoumi chicks (three days old) were inoculated with paecilomyces species isolated from the lung of dead Fayoumi chickens. Each chick was inoculated (into the heart) with one dose of 0.25 ml of culture suspension contained 200,000 spores (grown on sabouraud's agar for 21 days). 5 chicks used as control. All inoculated and control chicks were kept under observation for 21 days, feeds and watered ad libtum. Clinical symptoms, daily deaths and post mortem lesions were recorded. At the end of the experimental periods the chicks were killed and examined carefully. Samples for histopathological studies were taken from

---

* : Research Institute of Animal Health. Kena.

air sacs, serous membranes, liver, spleen, lung and heart stained with haemotoxyline and eosin and eosin and periodic acid schiff (PAS).

RESULTS

18 birds were died during experimental period. Mortality begin from the third day and continued to 17th days post infection. Prominent lesions were observed in the serous membranes, air sacs, liver lung and heart. No mortality observed among control chicks. Grossly: some organs from birds died in first week post infection were enlarged and congested. The serous membranes and air sacs were thickned, turbed and contained caseous material. Two weeks post infection grayish white nodules were observed in the air sacs, serous membranes (pericardium, pleura and peritonum), liver and lung. Three weeks post infection the liver and lung were atrophied, firm in consistance and pale in colour.

Microscopically: The air sacs and serous membranes in chicks died in the first week post infection were thickned with excessive fibrin deposition, lymphoid, macrophages, heterophil cells reaction. Abundant amount of fungal structures including mycelli, conidia vesicales and spores could be observed Fig.1 & 2. At the second week post infection typical granuloma consists of necrotic centre, surrounded by few giant and lymphoid cells were observed in the air sacs and serous membranes (Fig. 3). At this stage abundant amount of fungal mycelli, condiform heads, vesicales, and spores were observed in the serous membranes. In chicks killed three weeks post infection the serous membranes and air sacs were thickned by proliferation of fibrous connective tissue infiltrated by lymphoid and Macrophages cells (Fig. 4). Only remenant of necrotic granuloma were observed in the prolifrating connective tissue. Abundant population of fungal mycelli and spores were observed at this stages. The liver from chicks died in the first week post infection showed prominent vascular lesions including dilatation and congestion of the sinusoids, portal blood vessels and central veins. Some of the portal blood vesseles were thrombosed. Focal areas of lymphoid and heterophil cells reaction were observed in the portal tract. Minute small focal granulomas consisted of few giant cells and lymphoid cells were seen in the liver. Focal areas of necrobotic changes were observed in the hepatocytes. These necrobotic changes included cytoplasmic vacculation, cytoplasmolysis and nuclear pyknosis. Chicks died in the second week post infection showed multiple typical granulomas consists of necrotic centre surrounded with few giant cells and lymphoid cells in the liver. These granulomas were prominently encapsulated by thick fibrous connective tissue capsule. At this stage some of the granulomas were enlarged and extended to destroy the adjacent liver cells. In birds sacrificed at the end of the third week) large areas of fibrosis were seen in the liver (Fig. 5). The prolifrated connective tissue in the area of fibrosis was infiltrated with lymphoid, macrophages and heterophil cells and showed remenant of giant cells. The liver cells adjacent to the areas of fibrosis were atrophied and the sinusoid were prominently dilated. Fungal structures were constantly observed in the liver. Spleen from birds died at an early stages showed deplation of lymphoid cells population. Haemorrhages in some areas, severe congestion of the sinusoid and prominent haemosidrosis were observed. Spleen from chickes died or killed at the end of the experiment showed increased population of lymphocytes and prolifration of reticuloendotheiial cells and plasma cells.

The lung from chickes died one week post infection showed areas of haemorrhages and prominent congestion. In chicks died in the second week post infection multiple focal areas of granulomatus reaction were observed in the lung parenchyma and tertiary branchioles (Fig. 6). The centre of these granuloma consists of fungal structures and necrotic tissue. This was surrounded from outside by a wide zone of lymphoid, epitheliod, heterophil and

few amount of giant cells. At this stages the granuloma were surrounded by cogested zone. Somtimes the lumen of the tertiary bronchioles were filled with fungal structures and necrotic debri. This was surrounded from outside by lymphoid and macrophages cells reactions. Numerous small minute granuloma consists of few giant cells and lymphoid cells were frequently observed at this stage (Fig. 7). At a latter stage (chicks killed three weeks post infection) the lung granulomas were surrounded by thick fibrous tissue capsule. Focal area of fibrosis were not infrequently seen in the lung at this stage (Fig. 8). The fibrosed areas were infiltrated by lymphoid cells. In some cases only remenant of necrotic granuloma were observed and was surrounded by wide area of fibrosis. In these areas of fibrosis the parenchymal tissue of the lung were completely destroyed. Fungal structures including mycelli and spores were constantly observed in the lung. The blood vessels in the myocardium adjacent to the pericardium were extensivly dilated and filled with blood. Haemorrhage in some areas were somtimes seen. Macrophages contained haemosidrine pigment, lymphoid, macrophages and heterophil cells infiltration were observed in the myocardium. Neither gross nor histopathological changes were observed in the organ of control chicks.

DISCUSSION and CONCLUSION

Pathogenicity of Paecilomcyes isolated from the lung of dead Fayoumi chickens were tested in three days old Fayoumi chicks. 45% of chicks died through the course of the experiment. Gross lesions were observed in some organs including air sacs, serous membranes, lung and liver. At an early stages (one week post infection) fibrinous air saculitis, pericarditis, pleuritis and peritonitis, along with small focal areas of haemorrhages in the pericardium were the only detectable gross changes. At some what latter stages (two weeks post infection) small nodules were observed in the air sacs, liver and lungs. Three weeks post infection some of the parenchymatus organs (liver and lung) showed atrophy and fibrosis.

Micromorphologically, fibrinous inflammation was observed in the air sacs and serous membranes at an early stages. At a latter stages (two and three weeks post infection) chronic granulomatus reaction along with diffuse prolifration of connective tissue were observed in the air sacs and serous membranes. Micromorophalogical changes in the liver at one week post infection were of vascular and alterative type. Two week post infection chronic granulomatus hepatitis with distinct enceapsulation of the granulomas by connective tissue was a constant feature. Three weeks post infection chronic atrophic cirrhosis was observed. A similar results were observed in turkey poults experimentally infected with paecilomyces by EL BADRI (1979). Changes in the lung at an early stage were prominently vascular. At the middle stages (two weeks post infection) chronic granulomatus bronchopneumonia developed and this lead to pulmonary fibrosis at the end of 3th weeks. Changes in the spleen represented the immune reaction of the body against infection (DVORKIN, 1970; NAFADY, 1978 and ALI, 1985). At an early stages deplation of lymphocytes were prominent. Latter on lymphoid cells prolifration were observed. PAS reaction demonstrated abundant amount of fungal structure in the middle of the granulomatus lesions. Similar findings were obtained in experimental Aspergillosis in piegons and were attributed to the direct effect of the fungus (ALI, 1985).

From this investigation we can concluded that, Paecilomyces infection in Fayoumi chicks passes through three stages. Acute stage characterized by vascular, alterative and exudative reaction of fibrinous type. Subacute stage characterized by focal productive granulomas contained abundant amount of fungal structures in the centeral necrotic zone and were distinctly encapsulated by connective tissue. Chronic stages characterized by extensive fibrosis and atrophy of the organs. We can also concluded that paceliomyces species isolated from dead Fayoumi chickens was highly pathogenic for Fayoumi chicks.

REFERENCES

Ali, S.R. (1985): Histopathological and serum electrophoretic studies on experimental aspergillosis in pigeons. M.V.Sc. Fac. of Vet. Med. Assiut Univ. Assiut, Egypt.

Aller, B. (1967): Fungi in the upper digestive and respiratory tract of hens. Br. Vet. Jour 123: 431.

Dvorkin, L.B. (1970): Pathogensis of aspergillosis in duckling. Veterinarya, Moscow, 4: 68.

El-Badri, A.A. (1979): Studies on mycotic diseases in turkeys. M.V.Sc. Thesis Fac. Vet. Med. Assiut Univ.

Jand, S.K. and Dhillon, S.S. (1973): Fungi associated with respiratory diseases of poultry. Ind. Vet. J. 50: 211.

Nafady, A.A. (1978): Pathological studies on aspergillosis in poultry. M.V.Sc. Fac. of Vet. Med. Assiut Univ. Egypt.

Rajan, A. and Sivadas, C.G. (1971): Comparative pathology of experimental pulmonary aspergillosis in duckling and chicken. Kerala J. of Vet. Sci. 2. No.1, 59-62.

Refai, M.: El-Bahay, G.M., Mostafa, F.M. (1976): Investigations on the role of moulds in poultry industry. Jour. Egypt. Vet. Med. Assoc. 35, 3: 66-76.

Saif, A. and Aboul-Khier, F. (1979): Studies on the Epidemiology of aspergillosis in poultry and poultry men. Jour. Egypt. Vet. Med. Assoc. 39, 3: 5-19.

Sharma, V.B.. Sethi, M.S. and Negis, S.K. (1971): Fungal flora of the respiratory tract of fowls. Poult. Sci. 50: 1041.

LEGENDS OF FIGURES

Fig. (1): Air sacs thickned with cellular reaction and fungal structures. Stain H&E (25 x 12.5 x).

Fig. (2): Fungal structures in the air sacs. PAS stain (25 x 12.5 x).

Fig. (3): Typical granuloma in the serous membranes. Stain H&E (25 x 12.5 x).

Fig. (4): Prolifration of connective in the serous membranes stain H&E (25 x12.5 x).

Fig. (5): Hepatic fibrosis, only remnant of giant cells and lymphoid cells were seen in the connective tissue stain H&E (25 x 12.5 x).

Fig. (6): Focal area of granulomatus bronchopneumonia stain H&E (16 x 12.5 x).

Fig. (7): Small pulmonary granuloma. Stain H&E (25 x 12.5 x).

Fig. (8): Focal area of pulmonary fibrosis. stain H&E x 12.5 x).



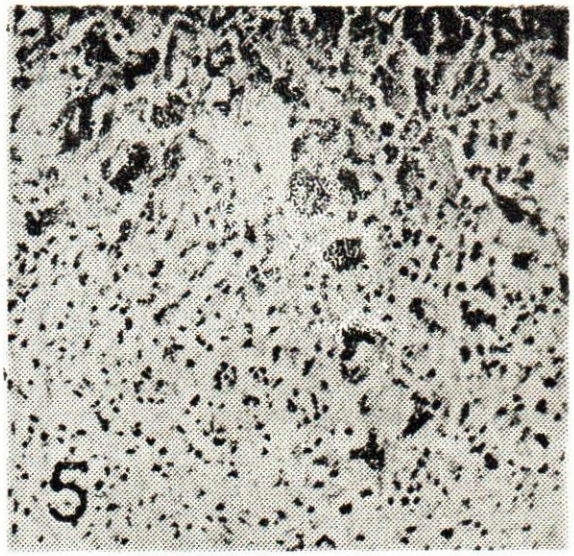
5

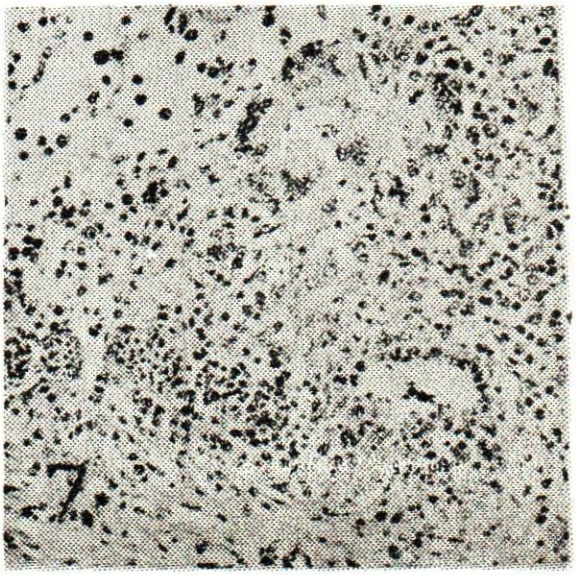
7

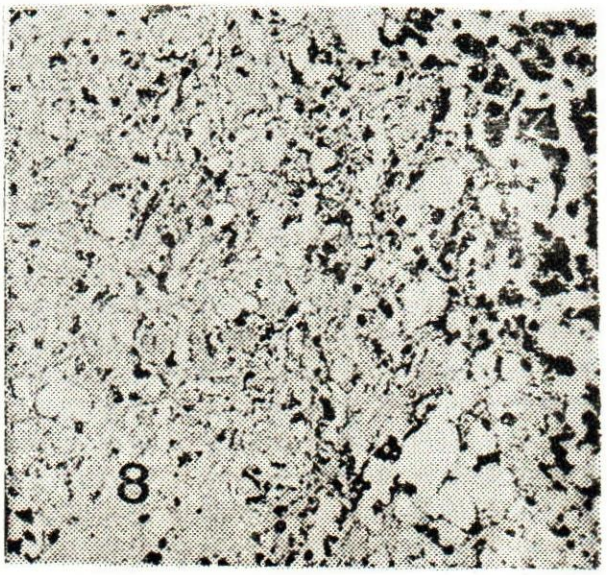
8