قســم : بحوث أمراض الجاموس.
معهد بحوث صحة الحيوان ـ الدقي.
رئيس القسم : أ.د. مرقص بولس.

الكوريني كمسبب لالتهاب المفاصل في العجول الجاموسي

عادل حلمي ، مرقص بولس* ، أحمد عامــر**

عزل ميكروب الكوريني من بوءرتين لالتهاب المفاصل في العجول الجاموسي وتبين من الفحص الاكلينيكي أن الاصابة عادة تكون من مفاصل العرقوب، الركبة الخلفية والركبــة الامامية ، بينما كانت اصابة مفصل المعقم وغمد الاوتار القابضة نادرة.

وكانت غالبية الميكروبات المعزولة هي الكوريني أوفيس بينما عزلت الكورينــي بيوجينس في حالة واحدة ودرست التغيرات الباثولوجية للغدد الليمفاوية والكبد والكلى كما وعولجت الحيوانات المصابة بالبنسلين والامبيسيلين لتقييم مدى فعالية العلاج.

---

* : قسم بحوث امراض الجاموس ـ معهد بحوث صحة الحيوان ـ الدقي.

** : قسم طب الحيوان ـ كلية الطب البيطري ـ جامعة أسيوط.

Animal Health Research Institute,
Res. Dept. of Buffalo Diseases,
Head of Dept. Prof. Dr. M.B. Morcos.

CONCURANT ARTHRITIS ASSOCIATED WITH CORYNEBACTERIUM SPP. IN BUFFALO CALVES

(With One Table and 4 Figures)

By

A.H. ELYAS*, M. MORCOS and A.A. AMER**

(Received at 5/10/1987)

SUMMARY

Two sporadic outbreaks of arthritis in 2 groups of buffalo calves arose from infection by Corynebacterium spp. The joints most commonly involved were the hocks, stifles and knees, and uncommonly were the fetlock and the synovial sheath of flexor tendon. The animals showed prominent clinical signs. Joints were enlarged. Arthritis greatly impeded locomotion. From the lesions Coryn. spp (Coryn. ovis in majority of cases and Coryn pyogenes in few instances) were recovered in pure culture. Histopathological changes were observed in joint capsules, lymph glands, liver and kidneys. Recovery occurred with treatment. The source of the infection and route of entry of the organisms to the body is a matter of conjecture. No trial was taken to produce the disease experimentally in this study.

INTRODUCTION

Arthritis commonly occurs in new born animals and it arises from infection of the navel by microorganisms such as Coryn. pyogenes, Spherophorus necrophorus, and Staph. spp. Coryn. pseudotuberculosis has been observed as cause of arthritis in lambs causing non-suppurative arthritis and bursitis and in areas where caseous lymphadenitis does not occur (HAMMERSLAND and WILKINS, 1941). Signs of arthritis localised in some larege joints of young buffalo calves were seen in sporadic outbreaks without being accompanied by history of navel infection or evidence of lesions in internal organs. This clinical picture arose a confusion in the diagnosis of the arthritis. The aim of this study is to report on the clinical history and the cause of the condition. This becomes more interesting when there are no previous reports available in this scope.

MATERIAL and METHODS

In February 1986, 48 male buffalo calves were bought from a variety of sources and brought into the farm which is located about 40 kilometers to the north of Cairo. The estimated age of animals was 8-10 weeks. Their general condition was "well". The previous history was free of illness except for mild diarrhoeas in few animals. The calves were raised for fattening untill they reached about 380-415 Kg body weight. On arrival to the farm, the

* : Animal Health Research Institue, Dokki.
** : Dept. of Med., Fac. of Vet. Med., Assiut University.

animals were divided into 4 groups and kept in houses with enought space and ventillation. They were allowed in open yards by day. This was followed untill they becamed 6-7 months old. and then kept indoors. The diet consisted of green fodder, hay and concentrates. Close to the calf yards there was a stable holding 22 dairy friesian cows and 15 milking buffaloes. Their ages ranged between 3-7 years. A previous history showed that microbial mastitis was a problem among cows and buffaloes and the causitive organisms included: E.coli, Strept. spp., Coryn. pyogenes, Staph. spp. and Proteus. Cures and improvements occurred after treatments. Retained placentae were observed in 9 cows and 7 buffaloes within the last 14 months but all cases were treated. Concerning the bought-in calves, there was no health complaint after their entry to the farm, except for few cases of diarrhea and respiratory troubles. They were treated and all recovered. At the end of April 1986, signs of arthritis were suddenly noticed till there were 7 diseased calves (14.5%). The appearance of arthritis took place till June/July 1986.

In February 1987, 67 male buffalo calves were purchased for the same purpose. They were nearly of similar age and condition as those bought-in in 1986. They also received similar management and feeding. During the early three weeks after arrival to the farm, the calves suffered from diarrhea (14 cases = 20.6%), respiratory troubles (9= 13%), tympany and enteritis (6= 8.8%). Sick animals were treated and good recovery was achieved. In May 1987, an arthritis syndrome began to appear among the animals till the end of July 1987, and the total number reported was 11 calves (10%). The syndrome was associated with general malaise and difficult movement.

Out of the 18 diseased animals, three died after long illness and no improvement towards recovery. Post-mortem examination was performed and samples of the joint capsules of the affected joints, lymph nodes, liver and kidneys were taken for histopatological studies. The specimens were fixed in formol 10%, embedded, sectioned and stained with Mayer's haematoxylin and eosin and Van Giesson's stains.

Sampling of the affected joints was performed aseptically by puncture and material for bacteriologic studies with refference to methods of isolation and identification according to CRUICKSHANK (1972). Antibiotic sensitivity tests and grading were performed as described by PATRA et al. (1974). There were 64 synovial samples taken for these studies.

The use of antibiotics was recommended for treatment as based on sensitivity testi using sensitivity discs (Difco). Joint lavage was advised and performed under aseptic precautions prior to injection of drugs.

RESULTS

I- Clinical and Bacteriologic Findings :

a) In April 1986, one calf appeared sick. It showed lamness, fever (39.2-39.7°C), inflammation of the right knee and both stifle joints, all were enlarged and painful. A thick greenish pus was aspirated. The right suprascapular lymph node was swallen. Respiration was hurried. Bacterial isolates were : Coryn. pyogenes.

b) In May 1986, two calves presented symptoms of difficult walking, enlarged and painful joints, fever (39.3 - 40.0°C), depression, weakness, inability to rise and difficult respiration. One of the calves died after 5 days of illness. The synovial fluid was aspirated from the knee, stifle and hock joints of all the calves. It was turbid and greenish in colour.

Bacterial isolates: the stifle joint of one calf showed gram + ve coccobucelli. Cultures of hock and carpal joints of the anther one developed a similar organism which was identified as Coryn. ovis.

c) In June 1986, four calves appeared stiff and feverish. They showed definite lameness and swollen carpal, hock and stifle joints. The joints had thick and turbid synovial fluid.

Bacterial isolates: a diphtheroid identified as Coryn. ovis was recovered. After 6 days of illness one of these calves died. On autopsy, the capsule of the stifle joints was thick and hyperaemic with some small erosions. The lungs showed lobular congestion. A fibrinous fluid was found in the peritoneal cavity. The lymph nodes were enlarged and congested. The kidneys were highly congested and showed small greyish spots in the cortex. Lung isolates: Coryn. pyogenes and Strept. spp. Kidney isolates: Coryn. pyogenes. Stifle joints isolates: Coryn. pyogenes.

d) In May 1987, there were 3 calves with swollen and painful knees and stifle joints. Two of them had in addition swollen and painful synovial sheath of the deep flexor tendon in the fetlock region of forelimbs. All animals had elevated body temperature (39.8 - 40°C), and impeded movement. Two animals showed arched back. Respiration was difficult and pulse weak. Synovial fluid was turbid and thick. After 5 days of illness, one calf died.

Bacterial isolates: joint cultures revealed organisms identified as Coryn. ovis. Synovial fluid from the sheath of the deep flexor tendon had gram+ve coccobacelli.

The autopsied calf: lungs revealed Coryn. pyogenes.

e) In June and July 1987, 8 animals presented signs of swollen and enlarged knees, hocks and stifle joints, the prescapular lymph glands were enlarged in one calf seen in July 1987. A second calf suffered from a right subparotideal swelling. All animals had lameness, difficult motion and mild fever (39.4 - 39.9°C). Joint cultures revealed Coryn. ovis. While Coryn. pyogenes was revealed from the parotideal abscess.

II- Sensitivity tests :

The results of antibiotic sensitivity of bacteria from aspirated synovial fluid are shown in table 1.

Table (1): In-vitro antibiotic sensitivity of joint bacterial isolates to.

Antibiotic	Very Sensitive		Sensitive		Slightly S.		Resistant	
	No	%	No	%	No.	%	No	%
Penicillin (10 iu)	41	64.0	16	25.3	4	6.3	3	4.6
Rifampicin (30 ug)	37	57.8	15	23.5	9	14.1	3	4.6
Ampicillin (10 ug)	32	50.0	24	39.5	3	4.6	5	7.8
Terramycin (10 ug)	25	39.1	22	34.3	12	18.7	5	7.8
Streptomycin (10 ug)	19	29.7	16	25.3	25	39.5	4	6.2
Erythromycin (is ug)	5	7.8	13	20.8	27	43.2	19	29.7

It could be seen from the above table that none of the antibiotics was fully sensitive against the organisms causing arthritis, nor did the organisms fully resistant to the antibiotics tested. The percentage of sensitivity ranged from 64.0% to 7.8% while the percentage of resistance varied from 4.6% to 29.7% of the antibiotics tested warranting effective use of these antibiotics and in particular the penicillin.

III- P.M. examination revealed the following:

The joint capsule of the left stifle joint was distended with greyish pus and the capsule thickened with hyperaemic spots. The lungs showed congestion and areas of hepatization. Lymph nodes were enlarged and congested. A serofibrinous fluid was present in the peritoneal cavity.

IV- Histopathological findings :

a) The joint capsule: There was diffuse infiltration with histocytes and neutrophiles. Most of blood vessels showed damage of the endothelial lining and perivascular cellular reaction.

b) In the lymph nodes there was subcapsular infiltration with inflammatory cells (neutrophiles), areas of toxic dystrophy, and degeneration with focal necrosis of lymphoid tissue, areas of extravasations and oedema.

c) The liver: There was degeneration of the hepatic cells and mononuclear cellular infiltration at the portal tracts with areas of toxic hepatic dystrophy (Fig. 1).

d) The kidneys: There was tubular nephrosis and interstitial mononuclear leucocytic infiltration. Severe medullaty intertubular casts, with hyaline casts were detected. Glomerular tuft was swollen, hyperaemic. Bavman's spaces are filled with easinophilic albuminous fluid (Fig. 3 & 4).

e) Lung: Congestion of lung tissue was prominant. Areas of bronchielitis with compunsatory emphysema were evident (Fig. 2).

V- Treatments :

The proportion of calves recovered from joint infection was high because there was a high correlation between in-vitro sensitivity and in-vivo response. The antibiotics which were widely used here were penicillin and ampicillin. They were effective in bringing out rapid resolution. The antibioitcs were used principally intraarticularly, after joint lavage, and intramuscularly. Other clinical signs such as respiratory troubles, fever ... etc were treated symptomatically. Cure was the result.

DISCUSSION

The present report seems to be of clinical importance since it deals with a particular condition of arthritis where Coryn. ovis was isolated from the affected joint. Although this organism has been confirmed as the causative agent for oedematous skin disease in buffaloes in Egypt, the present condition reported here has not been described yet in the literature. SOLIMAN et al. (1963) succeeded to isolate Coryn. pseudotuberculosis from five outbreaks of ulcerative lymphangitis, also named oedematous skin disease, affecting mainly buffaloes. Further studies by BARAKAT (1979, 1980) confirmed Coryn. pseudotuberculosis isolates from such cases. The lesions observed by them were similar to those previously reported by CARPANO (1934). We are very aware about the increase in morbidity rate from Coryn. pseudotuberculosis infection in buffaloes in different farms and provinces where outbreaks of ulcerative lymphangitis occur.

It is worth to mention that the epidemiology, nature of the disease and the associated clinical picture remained classical in two successive outbreaks (1983, 1984), with a similar percentage of disease incidence (14.5% & 16.4) respectively. This could happen although the animals were obtained from different sources. All isolates of Coryn. ovis were similar

in their morphology, growth pattern and some biochemical reactions. The source of the infection is difficult to determine but it might be probable that the environmental status in farm might have been a factor for advancement of the infection. Natural infection succeeded as if it might be attributed to the virulence of the organisms above the potential needed to initiate the infection. The disease history of the farm might be a factor to stimulate infection among calves with Coryn. ovis. Unidentified Corynebacteria were isolated by EL-SAWAF et al. (1961) from apparently normal and diseased gravid and non-gravid buffalo uteri. Also, diphtheroid organisms were isoalted from the genital tract of buffaloes and cows in cases of retained placenta and in normal delivery (ZAKI et al., 1961, 1963; ZAKI and FOAD, 1963, 1964; ZAKI and SABER, 1963; ZAKI et al., 1964). Despite these data, it is still difficult to ascertain the validity of our assumption. At time of bacteriologic examinations, the infection seemed to be in a progressive stage in the farm. The incidence of Croyn. ovis infection in the joints of calves seemed not dependent upon clinical examination at time of purchase, in as much as it was either absent or overlooked clinically. There is no reliable method for diagnosis of latent infection with Coryn. ovis (AWAD, 1961 and SHIGIDI, 1979). Because of the seosonal occurrence of arthictis, its transmission by insect vectors may be suggested but this is not confirmed. The choice of joints seems to justify the needs of the organisms to develop in deep sites with a surrounding oedeme. Generalised cases occurred on basis that a number of joints got infection. An increase in clinical cases was usually in spring months.

The histopathological changes described in this report in relation to liver, kidneys, joint capsules and lymph nodes were consistent. They gave a general impression that they could happen under the effect of a toxin produced by the organisms. These changes were reversible as reflected by clinical observations when the treated animals have been cured and their general condition improved.

ACKNOWLEDGMENT

The authors express thanks to Dr. A.H. Bayoumi, Prof. of Vet. Pathology, Faculty of Vet. Medicine, Assiut University for his valuable help in interpretting part of pahology in the study.

REFERENCES

Awad, F.I. (1961): Serological investigation of pseudotuberclosis in sheep. Agglutination test. Am. J. Vet. Res., 21: 251-253.

Barakat, A.A. (1979): Immunization against Caseous Lymphangitis by using Calmette and Guerin. (B.C.G). Bull. Off. Int. Epiz. 91, 9-10.

Barakat, A.A. (1980): Annual report on Oedematous Skin Disease. Ministry of Agriculture, Cairo, Egypt.

Carpano, M. (1934): Bull. Ministry of Agriculture, Techn. Sci. Ser., No. 135, Cairo.

Cruickshank, R.; Duguid, J.P.; Marmion, B.P. and Swain, R.H. (1975): Medical Microbiology 12th Ed. Churchill, Livingstone, Edinburg and London.

El-Sawaf, E.A.; Farrag, H. and Sameh, M. (1961): The bacterial flora of the cervical canal, uterine horns and fallopian tube in buffaloe and cows. Vet. Med. J., Giza, 7, 281-288.

Patra, R.C.; Tripathy,S.B. and Misra, S.K. (1974): Treatment of clinical bovine mastitis by different intramamary preparations following in-vitro sensitivity tests. Ind. Vet. J., 51, 375-378.

Shigidi, H.T. (1979): A composison of five serological tests for the diagnosis of experimental C. ovis infection in sheep. Austr. Vet. J., 50: 537-547.

Soliman, K.N.; Agamy, F.I. and Sayour, E.M. (1963): Ulcerative lymphangitis in buffaloe and cattle in Egypt. "Oedematous skin disease of buffaloe. Proc. 4th Ann. Arab. Vet. Congr., 99.

Zaki, K.; Abdel-Raof, M. and Siam, A.M. (1961): A bacteriological survey of the horns of the buffaloe uterus. Vet. Med. J., Giza, 7, 197-201.

Zaki, K.; Abel-Raof, M. and Siam, A.M. (1963): A bacteriological study of the uterine horns in cows. Vet. Med. J. Giza, 8, 225.

Zaki, K. and Fouad, M.S. (1963): Bacterial flora of retained placenta in buffaloes and cows. J. Egypt. Vet. Med. Assoc., 23: 179-182.

Zaki, K. and Fouad, M.S. (1964): The reproductive pattern of fresian cattle at a Governmental farm. J. Egypt. Vet. Med. Assoc., 24: 195-201.

Zaki, K. and Saber, M.S. (1963): Diagnosis of Corynebacterium-ovis in buffaloe. Vet. Med. J., Giza, 8: 175-180.

Zaki, K.; Zaki, O.A. and Moussa, A. (1964): The recovery of Corynebacterium ovis after delivery in cattle. Vet. Med. J. Giza, 9: 81-85.

EXPLANATION OF FIGURES

Fig. (1) : Liver: Toxic dytrophy of hepatic cells (X 250). H & E stain.

Fig. (2) : Lung: Pulmonary congestion, bronchitis and emphysema (X 160) H & E stain.

Fig. (3) : Kidney: Severe tubular nephrosis, hyaline casts Swallen glomerular tuft. Baumans space filled with eosinophilic albuminous fluid. (X 250) H & E stain.

Fig. (4) : Kidney: Severe medullary intertubular haemorrhage. (X 250) H & E stain.


1

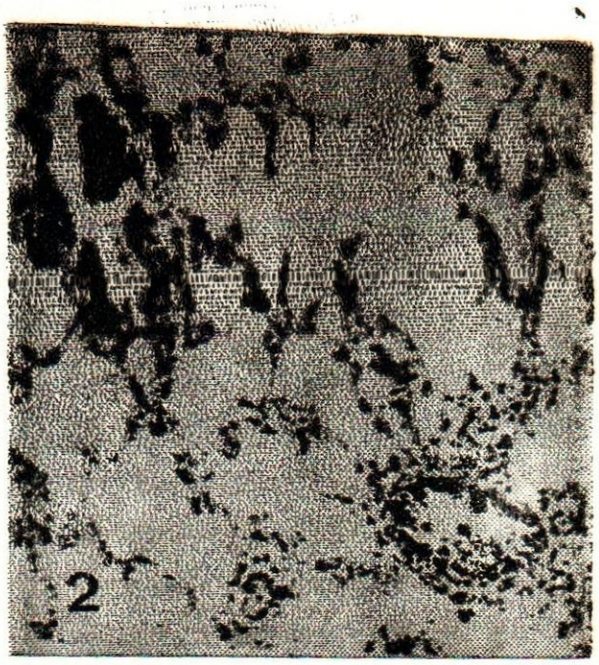
2

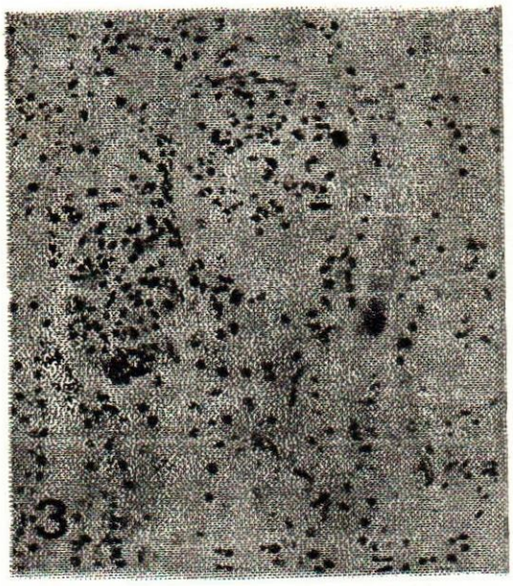
3

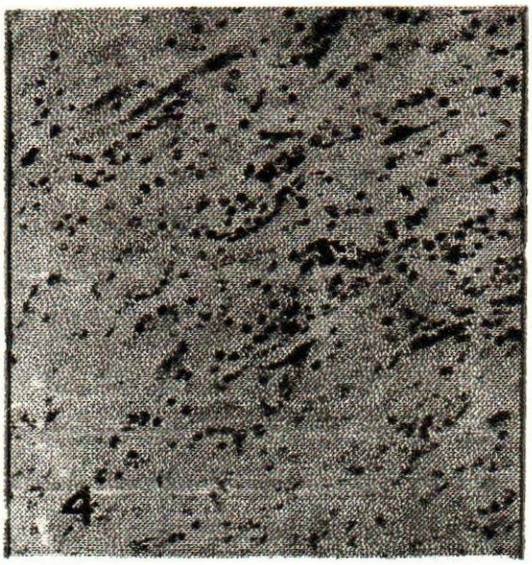
4