

Dept. Animal Medicine,  
Fac. Vet. Medicine, Kafr El Sheikh,  
Tanta Univ. Egypt.

## CLINICAL, EPIDEMIOLOGICAL AND HISTOPATHOLOGICAL ASPECTS OF AN OUTBREAK OF BUFFALO POX

(With 2 Tables and 18 Figures)

By

**M.H. AL GAABARY and A.A. ABUO RAWASH\***

\* Dept. Pathology, Fac. Vet. Medicine, Kafr El Sheikh, Tanta Univ.

(Received at 27/6/2004)

الجوانب الإكلينيكية والوبائية والهستوباثولوجية لوباء جدري الجاموس

مجدي حسنين عبدالقادر الجعيري ، عبد الرحمن أبو رواش

تناولت هذه الدراسة الأنماط الإكلينيكية التي ظهر عليها وباء جدري الجاموس في حيوانات قطنية بمحافظة الغربية وذلك في شتاء ٢٠٠٢-٢٠٠٣م حيث ظهرت ثلاث صور إكلينيكية: الأولى كانت شبيهة بجدري الأبقار حيث اقتصرت الإصابة على حلمات الطرغ للحيوانات المصابة دون مصاحبة أي أعراض أخرى والثانية ظهرت في مواضع محددة مثل الجوانب الداخلية للفخذين والرجلين الأماميتين وتحت الذيل وحول العين والفم مع ارتفاع طفيف في درجة الحرارة أما الصورة الثالثة فكانت عيفة حيث امتدت الآفات الجلدية لتشمل جلد الحيوان بأكمله بل وامتدت لتشمل الأغشية المخاطية للفم والأنف وصاحب هذه الصور الإكلينيكية تغيرات هستوباثولوجية متباينة ومن الناحية الوبائية: امتد الوباء على مدار ٩ أسابيع مسجلاً نسبة إصابة قدرها ٧,٨٧% بمعدلات إصابة قدرها ٠,٠٩ حيوان / أسبوع ونسبة نفوق قدرها ٥,٨% وكانت العلاقة بين عمر الحيوان واحتمالية إصابته بالمرض غير متوافقة.

### SUMMARY

A total of 216 buffaloes with different ages and sex, belonged to a private farm at Gharbia Governorate were exposed to skin disease suspected to be buffalo pox. Those animals were kept under observation for 12 weeks, the period during which new cases had been developed. The diseased animals were subjected to clinical, serological and histopathological examination. In addition, the pattern of occurrence including the duration of the outbreak, weekly incidence, temporal distribution and age susceptibility relationship were recorded. The results revealed great variations in the clinical reaction. Three clinical

forms were recorded: Mild form (cow pox-like form), moderate form with limited distribution of the lesions and severe generalized form with extensive distribution of the lesions all over the skin. The clinical variation was accompanied by pathological changes. Epidemiologically, it was found that the duration of the outbreak was 9 weeks with attack rate of 7.87 %. The incidence rate was 0.009 animal / week. The fatality rate was 5.8 %. There was no positive correlation between the age and the susceptibility to the disease.

*Key words: Buffalo pox, Histopathology, Epidemiology.*

## INTRODUCTION

Buffalo pox is a contagious viral disease characterized by development of typical pock lesions on the skin of the affected animal. It causes relatively high economic losses. About 70 % of the diseased buffalo cows developed mastitis and the milk yield is reduced by 30 % as the affected teat oftenly become blind. Mortality in young calves was reported. The disease was recognized as an important zoonotic disease by FAO/ WHO (Sreemannarayana and Ramachandraiah, 1999). The disease has been reported in Pakistan (Mahmood and Shah, 1985) India (Mallick, 1988, Mallick *et al.*, 1990 and Babu *et al.*, 1998), Italy and Egypt (Swell and Brocklesby, 1990). The objective of this study was to highlight an outbreak of buffalo pox specialty the clinical features, pattern of occurrence and histopathological changes.

## MATERIALS and METHODS

A total of 216 animals belonged to a private farm at Gharbia Governorate were exposed to a transmissible skin disease, suspected to be buffalo pox, where some of which were showing different stages of skin lesions distributed on the animal skin. The diseased animals were subjected to both clinical examination according to (Kelly, 1984) and serological examination, agar gel precipitation test, according to Sharama and Dhand (1971). Skin biopsies were collected in formalin saline 10 % and sectioned for histopathological examination according to Carleton *et al.* (1967). The attack rate and the incidence rate were determined according to Martin *et al.* (1994). In addition, the duration of the outbreak, the temporal distribution of the disease and the age - susceptibility relationship were recorded.

## RESULTS

### **Clinical findings:**

Out of 216 exposed animals, 17 showed clinical reaction varying in its severity and distribution of the pock lesions on the skin. In 3 lactating buffaloes, lesions were confined to the teats without any systemic reactions (Fig. 2). In other 6 animals, initial mild fever (39.9 – 40.2°C) had been developed ended by development of pock lesions in the inner aspects of the thighs, perineal region, fore limbs, brisket, perilibial area and ears (Figs. 3-8). A more severe form was developed in 8 animals. It was characterized by fever (40.1 – 40.9°C) lasting about one week, anorexia, edema of the legs, lacrymation, salivation and nasal discharge with extensive distribution of the pock lesions allover the skin of the diseased animals (Figs. 9, 10 and 11). It was observed that the severe affection of the teat interfere with the milking process reducing the milk yield. One of the diseased cases had been died after a course of 28 days during which the lesions extended to the mucous membrane of the nasal cavity. The death was proceeded by recumbence and respiratory distress. The lesions commenced as erythematous rash each of 1-2 mm. in diameter (Fig. 9). Thereafter, it became edematous and vesicular in nature which oftenly traumatized progressing rapidly to pustules and scabs with subsequent expansion in its diameter reaching about 1-2 cm. The pustular lesion showed depressed centers and appeared umbilicated (Fig. 10). The development of the lesion lasted about two weeks after which scabs fell off with complete healing within other 2 weeks.

### **Epidemiological features:**

The duration of the outbreak, weekly incidence, attack rate, temporal distribution of the disease and age susceptibility relationship were illustrated in Tables (1 and 2) and Fig. (1).

### **Histopathological changes:**

The lesions began with microscopic small local hamorrhages in the tips of the dermal papillae. The adjacent epidermal cells either showed marked proliferation (Fig. 12) or mild spongiosis of the stratum spinosum (Fig. 13). Slightly larger intradermal hamorrhages were observed in some cases (Fig. 14). Focal microscopic vesicles were detected in stratum spinosum of the affected epidermis (Fig. 15). Some of these vesicles showed mild leucocytic infiltration (Fig. 16). Healed lesions covered with scabs, formed of degenerated cell debris, were constant findings in all forms. The dermis underlying the vesiculated epidermis showed marked edema and proliferation of histocytes with

mild neutrophilic infiltration (Fig. 17). The dermal changes occasionally extended to the subcutaneous tissue (Fig.18).

### DISCUSSION

The clinical pictures recorded in this study were categorized into three clinical forms. The first form or cowpox-like lesions according to Murphy *et al.* (1999) was mild and the pock lesions were confined to the teats of the affected buffalo cows. In this form there was no any systemic reaction. The second form was moderate in its severity, where the distribution of the lesions was regional in nature; perineal region, inner sides of thighs, inner aspects of the fore limbs, under the tail, perilibial region, or ears of the animal in addition to mild elevation of body temperature. The third was the severe generalized form, in which the pock lesions were extensively distributed allover the skin of the affected animal with marked elevation of rectal temperature. So, buffalo pox is clinically differed from cow pox as described by kahrs (2001) who stated that the lesions of cow pox are confined to teats of the diseased cow. The moderate form is similar to that recorded by Mallick *et al.* (1990); Where the lesions are confined on the inner parts of the ear flap and around its base and on the eyelids, and that described by Babu *et al.* (1998); Where the lesions were restricted on the brisket region. The severe generalized form of the disease was similar to that recorded by Rana *et al.* (1988), Mary and Czerny (1990) and Sreemannaryana and Ramachandraiah (1999). The clinical findings that recorded in this study emphasize the role of the host susceptibility as a determinant which govern the clinical reaction and its severity particularly the distribution of the lesions on the skin of the diseased animal. Epidemiologically, it was found that the course of the outbreak that reported in this study was 9 weeks with attack rate of 7.9 % and fatality rate of 5.8 % and mortality rate of 0.46 %. While that reported by Mallick *et al.* (1990) was 16 weeks with morbidity of 14.2 % but the fatality was nil. In agreement with Mahmood and Shah (1985) and mallick *et al.* (1990) all cattle in contact with the diseased animals remained absolutely free from pox lesions. The short duration of the outbreak and the interruption in the curve of temporal distribution of the disease at the seventh week may attributed to the efforts adopted for control by isolation of the diseased animals. The period elapsed in between the first and second cases in the outbreak as shown in Table (1) and Fig. (1) revealed that the incubation period is nearly 2 weeks and the gradual occurrence of cases emphasize the entry of the disease to the farm with newly introduced animals. The

histopathological changes that reported in this study were similar to those reported by Carleton and Mc Gavin (1995).

#### REFERENCES

- Babu, R.M.; Rao, T.S.; Devi, V.R.; Rao, AVN. and Chand KP. (1998):* An outbreak of atypical form of buffalo pox. *Ind. Vet. J.* 75: 855 – 856.
- Carleton, MA.; Drury, RAB.; Willington, EAB.; Willington, EA. and Commerton, EA. (1967):* Carleton's Histological Techniques. 4<sup>th</sup> edition, Oxford Univ. press.
- Carleton, WW. and Mc Gavin, MD. (1995):* Thomson's Special Veterinary Pathology 2<sup>nd</sup> edition Mosby – year book. Inc.
- Kahrs, RF. (2001):* Viral diseases of Cattle, 2<sup>nd</sup> edition, Iowa State Univ. press.
- Kelly, WR. (1984):* Vet. clinical diagnosis 3<sup>rd</sup> edition, Bailliere tindall, London.
- Mahmood MA. and Shah MA. (1985):* Outbreak of pox like disease in buffaloes. *Pakistan Vet. J.* 5: 2, 94 – 95.
- Mallick, KP. (1988):* A note on epidemiological study of an outbreak of buffalo pox. *Ind. J. Vet. Medicine*, 8: 2, 146 – 147.
- Mallick, KP.; Rawany, VS. and Celly, CS. (1990):* A report on Buffalo - pox outbreak in Pathalgaon Block of District Raigarh. *Ind. Vet. J.* 67: 1173 – 1174.
- Martin, SW.; Meek, A H. and Willebery, p. (1994):* Vet. Epidemiology, 4<sup>th</sup> edition. Iowa State Univ. press.
- Mary, A. and Czerny CP. (1990):* Cow pox virus. In *Infectious Diseases of Ruminants*. Edited by Z. Dinter, B Morein Amsterdam: Elsevier Scientific publishers pp. 9 – 15.
- Murphy, FA.; Gibbs, EPJ.; Horzinek, MC. And Studdert MJ. (1999):* Vet. Virology 3<sup>rd</sup> edition, Academic press.
- Rana, UVS.; Garg, SK.; Rajesh Chandra; Varshney KC. and Rao, VDP. (1988):* Pathological studies on experimental buffalo pox in buffaloes. *Ind. J. Anim. Sciences* 58 (1): 63 – 67.
- Sharma, SN. and Dhanda, MR. (1971):* Immunodiffusion studies on sheep and goat pox viruses. *Indian J. Animal Sc.* 4 (3): 166 – 171.
- Sreemannaryana, O. and Ramachandraiah, K. (1999):* An outbreak of generalized form of buffalo pox. *Buffalo bulletin*, 18: 1, 3 – 4.
- Swell, MMH. and Brocklesby, DW. (1990):* Handbook on Animal Diseases in the tropics 4<sup>th</sup> edition PP. 283.

Table 1: The weekly incidence of buffalo pox during an outbreak in buffalo herd at Gharbia Governorate.

Weeks	No of A R	No of Dis ani	Weekly is Incidence
1	216	1	0.46 %
2	215	-	0.00 %
3	215	1	0.47 %
4	214	2	0.93 %
5	212	5	2.36 %
6	207	3	1.45 %
7	204	-	0.00 %
8	204	3	1.47 %
9	201	2	1.00 %
10	199	-	0.00 %
11	199	-	0.00 %
12	199	-	0.00 %
Total		17	7.87 %

$$\text{Attack rate} = \frac{17}{216} \times 100 = 7.87 \%$$

$$\text{Incidence rate} = \frac{17}{\frac{216 + 199}{2} \times 9} = 0.009 \text{ animal / week}$$

The course of the outbreak = 9 weeks.

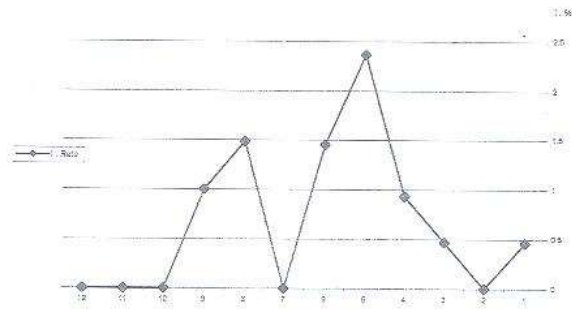


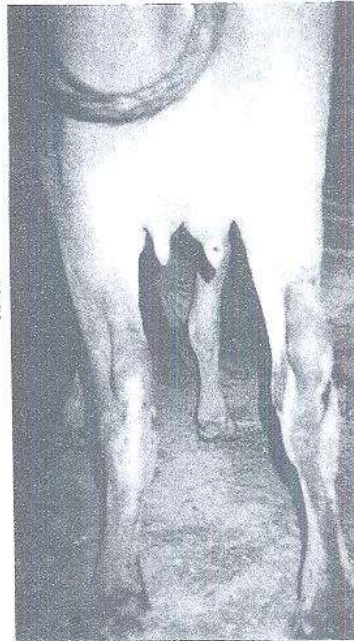Fig. 1: Temporal distribution of buffalo pox during an outbreak in buffalo herd at Gharbia governorate.

Table 2: The age-incidence relationship in buffalo pox.

Age Group	No of Exp. A.	No of Dis. A.	% of Dis. A.
Less than, 1 year	131	10	7.63
more than 1 year	85	7	8.23
TOTAL	216	17	7.87

Exp. A. = Exposed Animals.  
Dis. A. = Diseased Animals.

Fig. 2: Mild lesion of buffalo pox on the teat of lactating buffalo.



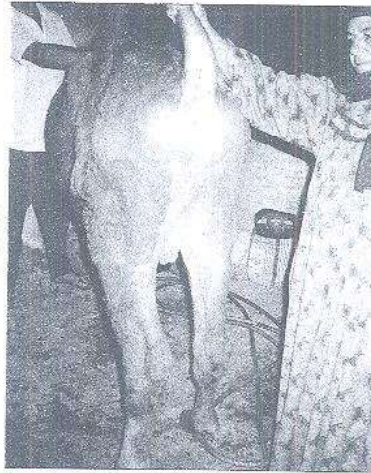

Fig. 3: A mild form of buffalo pox with mild lesions restricted on the inner aspect of the tail in a male buffalo calf.

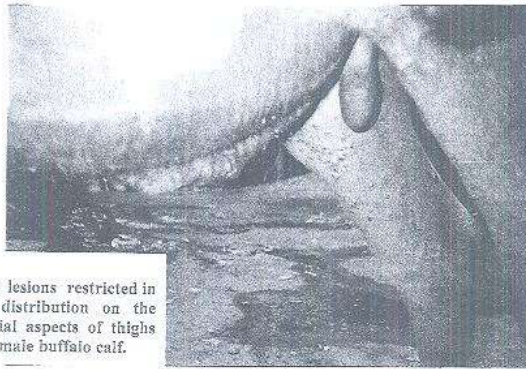
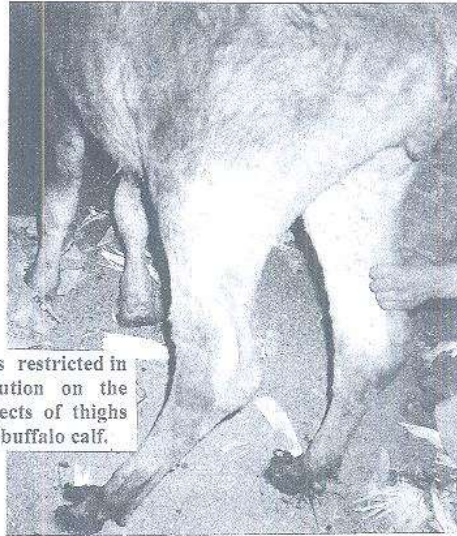


Fig. 4: Pox lesions restricted in its distribution on the medial aspects of thighs of a male buffalo calf.





**Fig. 5:** Pox lesions restricted in its distribution on the medial aspects of thighs of a female buffalo calf.



**Fig. 6:** Pox lesions on the neck, shoulders and medial aspects of the fore arms in buffalo calf.

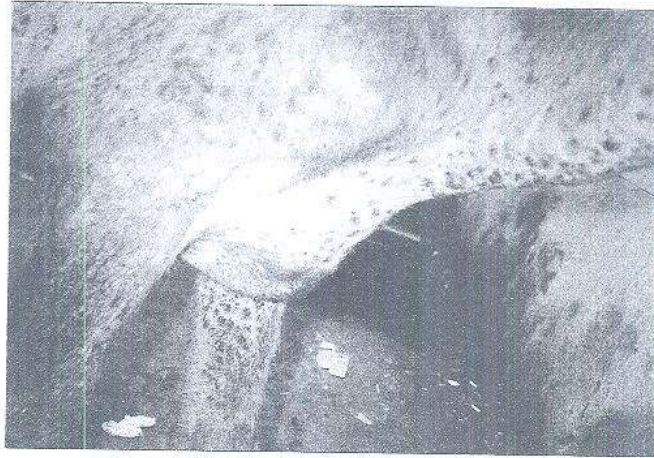


Fig. 7: Close-up on the lesions.

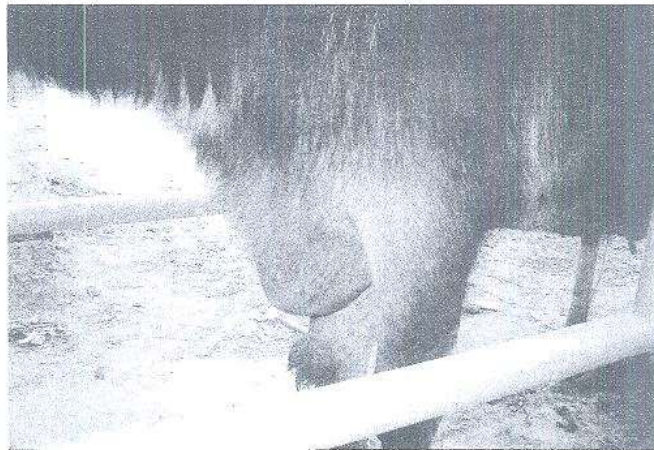
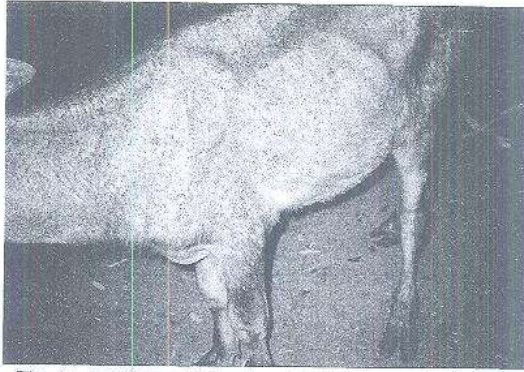


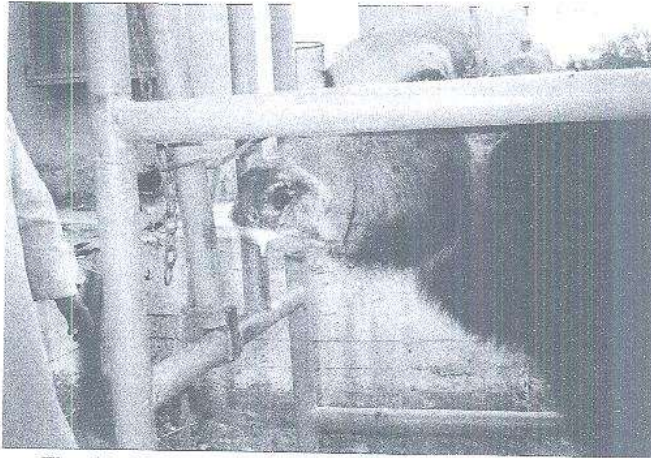
Fig. 8: A buffalo suffering from pox showing limited distributions of lesions on brisket.



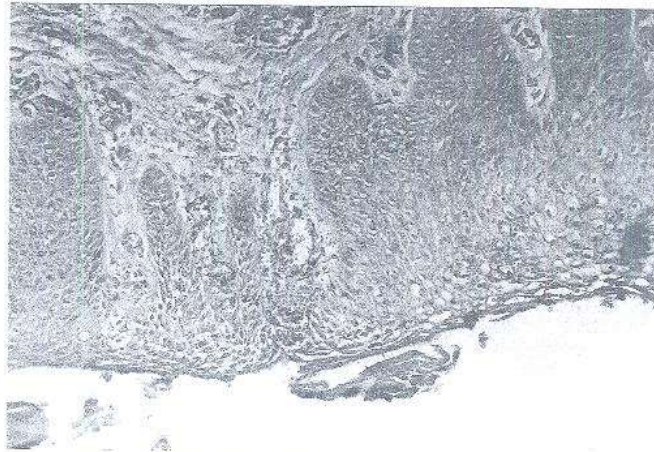
**Fig. 9:** A buffalo calf showing extensively generalized pox lesions all over the body.



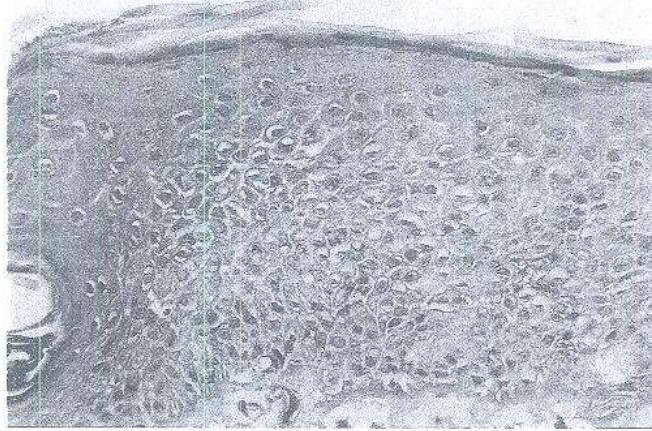
**Fig. 10:** A buffalo showing generalized form of buffalo pox. The lesions involve the hind quarters including the vulva and the udder.



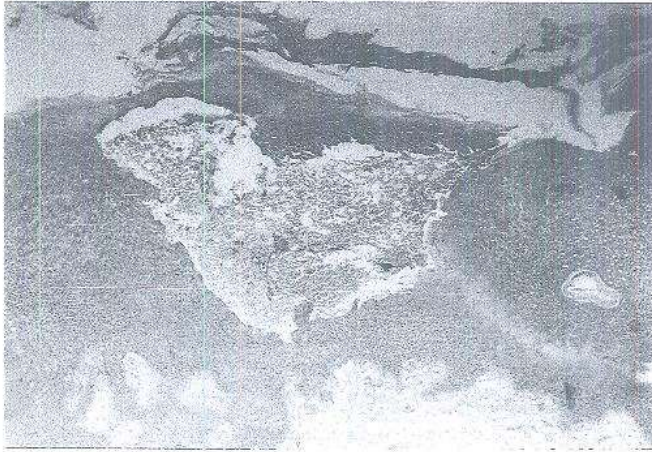
**Fig. 11: Buffalo pox lesions extend to involve the nasal mucous membrane.**



**Fig. 12: Microscopic small local hemorrhages in the tips of dermal papillae, (early stage of pox lesion).**

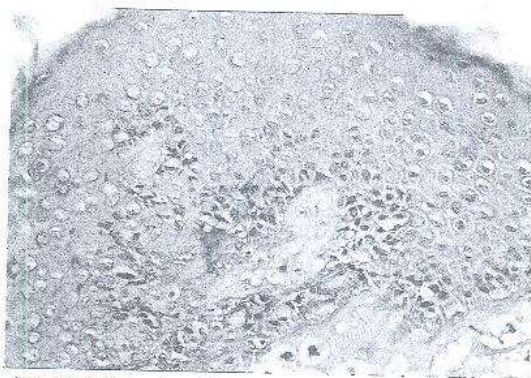
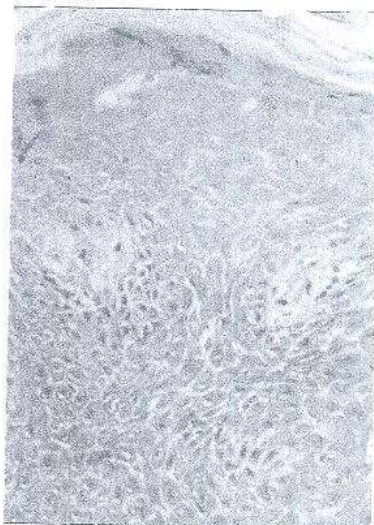


**Fig. 13: Mild spongiosis of stratum spinosum.**

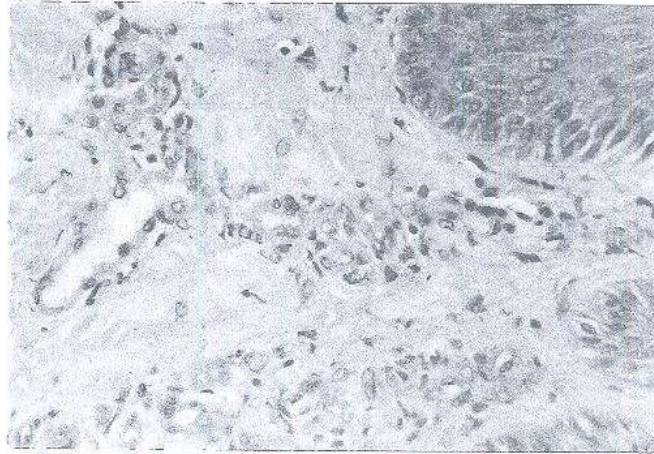


**Fig. 14: Intra dermal hemorrhage.**

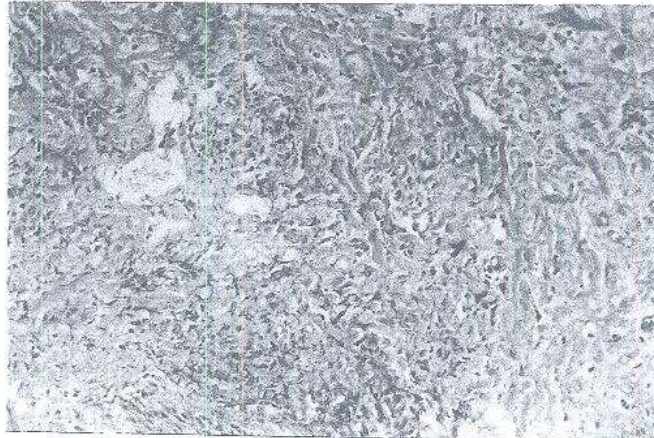
**Fig. 15:** Focal microscopic vesicles in stratum spinosum.



**Fig. 16:** Vesicles showed mild leucocytic infiltrations.



**Fig. 17: Marked edema and proliferations of histocytes with mild neutrophilic infiltrations in the dermis underlying the vesiculated epidermis.**



**Fig. 18: Dermal changes extend to the subcutaneous tissues.**