

AN OUTBREAK OF DERMATOPHYTOSIS IN GOAT KIDS (With 2 Tables and 7 Figures)

By

M.N. NASSIF and S.A. OSMAN
(Received at 25/9/2003)

دراسة عن القراع في جديان الماعز

مدهت ناصف محمد - سلامة أحمد عثمان

أعتمد هذا البحث على دراسة ظهور وباء لمرض القراع في قطع من الجديان الصغيرة في عمر أقل من ٦ شهور وعددها عشرون حيوانا في محافظة كفر الشيخ. وقد أوضحت هذه الدراسة انتشار المرض بصورة سريعة حيث أصيبت جميع الحيوانات ممثلا معدل إصابة وصلت إلى ١٠٠%. وقد أظهر الفحص المعلي لكحطات الجلد والشعر لمكان الإصابة في الحيوانات المريضة وجود فطر التريكوفايتون كمسبب للمرض في هذه الحيوانات. وتمثلت الأعراض الأكلينيكية لهذا المرض في وجود إصابات جلدية في صورة مناطق محددة ومستديرة خالية من الشعر عليها بعض القشور وقد لوحظ أن هذه الإصابات تركزت في مناطق الرأس والأذن والرقبة وأحيانا في الأرجل. وقد أظهر فحص صورة الدم للحيوانات المصابة وجود نقص معنوي في كل من كرات الدم الحمراء وتركيز هيموجلوبين الدم مقارنة بالحيوانات السليمة ظاهريا. كما أظهر التحليل البيوكيميائي لسيرم الدم في الحيوانات المصابة وجود نقص معنوي في مستوى عناصر الزنك وفيتامين أ في الجديان المصابة مقارنة بالسليمة ظاهريا. وقد تم التحكم في هذا الوباء بعلاج الحيوانات المصابة عن طريق العلاج الموضوعي لأماكن الإصابة باستخدام مرهم اليود بتركيز ١٠% بعد إزالة القشور يوميا ولمدة أربعة عشر يوما بالنسبة للمجموعة الأولى أو استخدام عقار الإيمافيرول كرش لأجزاء الجسم المختلفة ثلاث مرات بفواصل زمنية ثلاثة أيام مع تطهير المكان والأدوات باستخدام محلول الهيبوكلوريت ١٠% وقد أظهر عقار الإيمافيرول فاعلية أسرع خاصة مع الحقن العضلي لفيتامين أ وإضافة مخلوط الأملاح المعدنية لمليقة الحيوان.

SUMMARY

In July 2003, an outbreak of dermatophytosis was occurred in a flock of twenty goat kids at Kafr El- Sheikh Province. The morbidity rate reached 100% and *Trichophyton verrucosum* was identified in the examined skin scraping and hairs of infected animals through direct microscopic

examination and culture method. Clinically infected kids showed skin lesions in the form of circumscribed circular areas of alopecia, scaling and crusting. The lesions involved the face, external ears, neck and sometimes limbs, but generalized body involvement was not recorded. Hematological examination noted a significant decrease ($P < 0.05$) in erythrocytic count and hemoglobin concentration in infected kids compared to apparently healthy control ones from flock without skin lesions. Also serum biochemical analysis of infected animals revealed significant decrease ($P < 0.05$) in the levels of zinc and vitamin A in comparison with apparently healthy control ones, which reflecting the role of undernutrition in the spreading of infection. Control of this outbreak consists of immediate beginning of therapy by using daily topical application of 10% iodine ointment on the lesions of infected kids for 14 days in the first group or spraying entire animal body using enilconazole (Imaverol; Janssen) for three applications at three days interval in the second group, in addition to disinfection of animals pen and equipments using 10% hypochlorite solution to eliminate the fungal spores from the environment, but rapid clinical and mycological cure was observed in enilconazole treated group especially those received vit. A and mineral supplementation.

Key words: *Dermatophytosis, Goat kids*

INTRODUCTION

Goats are exploited for diverse purposes including meat, milk, cheese production and skin for leather making (Smith and Sherman, 1994).

Dermatophytosis is a fungal disease that affect the outer layer of the skin and hairs (Lateur, 2000 and Smith, 2002). Dermatophytes can affect any domestic animal, including livestock and pets, as well as humans (Connole, 1990). Although dermatophytosis is relatively common in cattle it is relatively rare in goats (Stannard, 1988; Hungerfords, 1990; Fraser, 1991; Matthews, 1991 and Radostits *et al.*, 2000).

Some dermatophytes have great zoonotic importance, where many of them occurring primarily in animals and can be transmitted from infected animals to man (Beck and Clark, 1998 and Nakamura *et al.*, 1999).

Although several genera of dermatophytes are involved in the etiology of dermatophytosis in goats, the vast majority of lesions are caused by *Trichophyton verrucosum* (Fraser, 1991; Matthews, 1991; Smith and Sherman, 1994 and Smith, 2002).

The transmission of dermatophytosis is usually by either direct contact with infected host (animals or humans) or indirect contact with infected exfoliated skin or hairs in premises and equipments (Scott, 1988; Radostijs *et al.*, 2000 and Smith, 2002).

Direct microscopic examination and culture of skin scraping and hairs from the periphery of lesions are necessary to confirm the clinical diagnosis of dermatophytosis (Katoh *et al.*, 1991; Porgerson and Abbott, 1999 and Markus *et al.*, 2001).

The available literatures lack about dermatophytosis in goats, so this investigation was delineated to study this disease in goats with a special reference to clinical picture, blood and serum biochemical parameters as well as control of an outbreak of such disease in kids.

MATERIALS and METHODS

1. Animals:

A goat flock belonging to Kafr El-Sheikh Province consists of 20 kids were subjected to this study; all of these animals were male and less than 6 months of age. According to the parasitological examination, all kids were free from external and internal parasites.

2. Clinical examination:

All kids were subjected to complete clinical examination according to Smith and Sherman (1994).

3. Fecal examination:

Parasitological examination of fecal matter was carried out according to Coles (1986) to ensure that kids are free from internal parasites.

4. Mycological examination:

Skin scraping was carried out (before treatment and after recovery) according to Kelly (1984). After that the scraped materials were divided into two parts: the first was subjected to direct microscopic examination (Koncman and Roberts, 1985) and the second for culture on Sabouraud Dextrose Agar Media (SDA) with chloramphenicol and cyclohexidine. The media kept at 27°C for 3 weeks. Identification of the

resulted colonies were carried out according to Kozłowska and Nuber (1996) and St-Germain and Summerbell (1996).

5. Hematological examination:

Anticoagulated blood samples were collected from infected animals as well as from apparently healthy control ones (i.e. from other flock in similar sex and age and without history of skin lesions). Erythrocytic and leukocytic counts, hemoglobin concentration and differential leukocytic count were carried out according to Coles (1986).

6. Serum biochemical analysis:

Copper and zinc estimation were carried out on the serum of diseased and apparently healthy kids using atomic absorption spectrophotometer (Willis, 1960), while, serum vitamin A level was estimated according to Nobert (1986).

7. Therapeutic trials:

Diseased kids were divided into two main groups each of 10 animals. Treatment was carried out after removal of skin crusts using daily topical application of 10% Iodine ointment for two weeks (1st group), while the second group were treated by spraying of all entire body using enilconazole (Imaverol; Janssen) for 3 applications at 3 days interval. In addition to the previous treatments and inside these groups, 5 kids from each were supplemented with vitamin A (100.000 I.U/animal) by intramuscular injection and mineral mixture as dietary additives, while the remaining animals not receive this treatment.

8. Statistical analysis:

The obtained data was analysed according to Snedecor and Cochran (1980).

RESULTS and DISCUSSIONS

Dermatophytes are a group of morphologically and physiologically related molds that cause well defined infection in vertebrates (Torres *et al.*, 2002). In the last two decades the incidence of infections caused by dermatophytes and other fungi has increased considerably (Weitzman and Summerbell, 1995 and Norris *et al.*, 1999). Moreover, the hazard of zoonotic infection and reduction of animal price gave ringworm a major attention (Osman *et al.*, 2002).

Concerning disease frequency, the disease spreads very rapidly in the flock, with most animals become affected within a few weeks causing a 100% morbidity rate. The highest spread of the infection to

affect all the flock may be attributed to the nature of the disease, where, it was highly contagious transmitted via direct and indirect contact (Scott, 1988; Hungerfords, 1990; Radostits *et al.*, 2000 and Smith, 2002). In addition to the increase susceptibility of young animals to this infection. The susceptibility of young animals are probably related to lack of prior exposure to infection and thus no immunity. Other factors that may be operative on occasion are over crowding and conditions that decrease resistance to infection such as poor nutrition (Scott, 1988 and Smith, 2002). Moreover, the environmental factors may aid in the increasing of the morbidity, where, the presence of kids indoors in hot humid climates with little or no sunlight have an increased the incidence (Stannard, 1988 and Smith, 2002).

The occurrence of this outbreak in July coincided with Radostits *et al.* (2000) who said that, however, high incidence of clinical cases was recorded in winter, outbreaks often occur during the summer months, where, close confinement and possibly undernutrition seem to be more important in the spread of the disease.

Mycological examination of the examined skin scrapings and hairs revealed *Tr. Verrucosum*, in agreement with the results of Fraser (1991); Matthews (1991); Smith and Sherman (1994) and Smith (2002).

The incubation period of ringworm may range from 1 to 6 weeks (Stannard, 1988 and Smith, 2002). So, the rapid appearance of the lesions within only few days after animal arrival (Purchasing) is indicative that these animals were affected before their arrival and reached when they were in the incubation period. Moreover, apparently healthy animals may carry the fungal spores in their skin. Similar observation was previously reported by Ali *et al.* (1988) and Efuntoye and Fashanu (2002) who isolated fungus from skin and pens of healthy animals.

The clinical signs observed during this outbreak included the appearance of skin lesions in the form of circumscribed circular areas of alopecia, scaling and crusting. In addition to multifocal nature of the lesion, the individual lesions usually vary considerably in size. Later, these lesions coalesce to each other forming large irregular lesions. These skin lesions were most commonly seen on the face, external ears, neck and sometimes limbs but generalized body involvement was not occurred. Also, pruritus was not observed (Figs. 1 - 4). In addition, infected kids showed some degree of discomfort and inappetence. Similar signs were previously reported by Hungerfords (1990); Fraser

(1991); Matthews (1991); Smith and Sherman (1994); Radostits *et al.* (2000) and Smith (2002). Under normal circumstances, dermatophytes only invade fully keratinized non-living tissue, thus the only clinical sign they can produce by their presence is alopecia, which results from breaking of the weakened hair shafts (Stannard, 1988).

Hematological examination revealed a significant decrease ($P < 0.05$) in erythrocytic count and hemoglobin concentration in infected animals compared to apparently healthy control ones (Table 1). This anemia may be attributed to the inappetence and under nutrition as kids were fed a poor quality roughage and concentrate during the outbreak of dermatophytosis.

Table 1: Hemogram in apparently healthy and diseased kids.

Variable	App. healthy kids (n=5)	Diseased kids (n=20)
RBCs ($10^6/\mu\text{l}$)	8.30 ± 0.5	$7.10 \pm 0.3^*$
Hb (g/dl)	9.5 ± 0.3	$8.1 \pm 0.4^*$
PCV (%)	24.3 ± 1.2	25.5 ± 1.5
WBCs ($10^3/\mu\text{l}$)	9.70 ± 0.2	10.1 ± 0.25
Neutrophils ($10^3/\mu\text{l}$)	3.20 ± 0.1	3.1 ± 0.2
Lymphocytes ($10^3/\mu\text{l}$)	4.80 ± 0.1	4.95 ± 0.3
Monocytes ($10^3/\mu\text{l}$)	0.55 ± 0.05	0.50 ± 0.03
Eosinophils ($10^3/\mu\text{l}$)	0.50 ± 0.03	0.51 ± 0.05

* = Significant at $P < 0.05$

Blood serum biochemical analysis of infected kids revealed a significant decrease ($P < 0.05$) in both zinc and vitamin A with the mean values of $101.3 \pm 2.2 \mu\text{g/dl}$ and $21.4 \pm 2.1 \mu\text{g/dl}$, respectively in comparison with $108.2 \pm 3.1 \mu\text{g/dl}$ and $26.5 \pm 2.05 \mu\text{g/dl}$ in apparently healthy kids (Table 2). These deficiencies may be contributed to the development of wide spread and chronic lesions of dermatophytosis (Lepper, 1972). Regarding serum zinc, McDowell (1989) reported that serum zinc level less than 0.8 ppm might associated with skin lesions. But concerning vitamin A, Smith and Sherman (1994) mentioned that, vitamin A is essential for normal epithelial covering and its deficiency enhance the skin lesion. Moreover, Liao *et al.* (1996) and Nonnecke *et al.* (1999) mentioned that, vit. A is essential for maturation of neonatal immune system and its deficiency cause suppression in autoimmunity by

decreasing hyperactivity of both cellular and humoral immune function and increase susceptibility to infectious diseases. In addition, Pandey and Mohin (1980) reported that young debilitating kids under nutritional deficiency are most at risk for developing ringworm.

Table 2: Serum biochemical constituents of copper, zinc and vitamin A in apparently healthy and diseased kids.

Variable		App. healthy kids (n=5)	Diseased kids (n=20)
Copper	µg/dl	98.3 ± 2.2	97.2 ± 1.5
Zinc	µg/dl	108.2 ± 3.1	101.3 ± 2.2*
Vit. A	µg/dl	26.5 ± 2.05	21.4 ± 2.1*

* = Significant at P<0.05

The choice of the proper treatment is determined by the site, extend of the lesions and the species involved, as well as by the efficacy, safety profile, and kinetics of the available drug. For localized non extensive infections, topical therapies are generally used, whereas in cases of extensive infections, systemic antifungal treatment is necessary (Paterson, 1999; Niewerth and Korting 2000; Alou *et al.*, 2001 and Debruyne and Coquerel, 2001).

In this investigation, treatment of the first group was carried out using daily topical application of 10% iodine ointment for 14 days after removal of skin crusts. In addition to the previous treatment, only five infected kids of this group received vitamin A (100.000 I.U/animal) intramuscularly together with mineral mixture containing zinc. While treatment of the second group was done using enilconazole spray of entire animal body for three applications at three days interval. Also, five kids of this group receive the previous treatment of vitamin A and mineral mixture. The results of treatment program revealed that recovery rate (clinical and mycological) was faster in enilconazole treated group especially those received vitamin A and mineral supplements (Fig. 5-7). Similar results were previously recorded by Radostits *et al.* (2000) who reported that supplementation of the diet with vitamin A to young housed animals should be encouraged as a preventive measure.

Disinfection of animal housing and equipments is essential to prevent disease spread and to prevent further occurrence of the disease. So disinfection must be done in adjunct with animal treatment. In this study 10% hypochlorite solution was used in the disinfection procedure

(Rycroft and McLay, 1991), where most of dermatophytes might remained viable in infected soil and premises for many years (Haggag *et al.*, 1999; Nashwa Khalifa, 2001 and Efuntoy and Fashanu, 2002).

Finally we must put in our mind some recommendations to limit the spread of dermatophytosis among animals:

1. Proper nutrition especially vitamin A and trace elements should be considered in the animal diet.
2. Topical application in the form of spray to wash the entire animal body is better than application on the lesion only.
3. Animal environment including, pens and equipments must be thoroughly disinfected using an efficient commercial fungicide.

REFERENCES

- Ali, M.S.; Arda, H.M.; Hassouna, M. and Shaheen, S.F. (1988):* Keratinophilic fungi on the hairs of goats from the West Bank of Jordan. *Mycopathologia*, 104(2): 103-108.
- Alou, L.; Maestre, J.R. and Moreno, R. (2001):* Consumo de Antifungicos de uso topico en Espana. *Rev. Esp. Quinioterap.* 14: 340-344.
- Beck, W. and Clark, H.H. (1998):* Zoophilic dermatophytes as epizoonoses pathogens and their significance to dermatology. *Hautarzt*, 49(6): 457-461.
- Coles, E.H. (1986):* *Veterinary Clinical Pathology*, 4th ed.; W.B. Saunders Company, Philadelphia and London.
- Connole, M.D. (1990):* Review of animal mycoses in Australia. *Mycopathologia*, 111(3): 133-164.
- Debruyne, D. and Coquerel, A. (2001):* Pharmacokinetics of antifungal agents in onychomycoses. *Clin. Pharmacokinet.* 40: 441-472.
- Efuntoy, M.O. and Fashanu, S.O. (2002):* Fungi isolated from skins and pens of healthy animals in Nigeria. *Mycopathologia*, 153(1): 21-23.
- Fraser, C.M. (1991):* *The Merck Veterinary Manual*. 7th ed. Printed in USA.
- Haggag, Y.; Draz, A. and Samaha, H. (1999):* Soil as a reservoir of certain dermatophytes and other fungi to man and animals. *Alex. J. Vet. Sci.* 15(1): 1-9.
- Hungerfords, T.G. (1990):* *Diseases of livestock*. 9th ed. Bibliography. pp. 542-543.

- Katoh, T.; Maruyama, R. and Nishioka, K. (1991):* Tinea corporis due to *Microsporum canis* from an asymptomatic dog. *J. Dermatology* 18: 356-359.
- Kelly, W.R. (1984):* *Veterinary Clinical Diagnosis*. 3rd ed. Bailliera Tindal. London.
- Koneman, E.W. and Roberts, G.D. (1985):* *Practical Laboratory Mycology*. 3rd ed. Williams and Wilkins. Baltimore, M.D.
- Kozłowska, E.A. and Nuber, D. (1996):* *Leitfaden der Praktischeaus Mycologie* Blackuie, Berlin.
- Lateur, N. (2000):* Dermatophytosis due to domestic animals. *Rev. Med. Brux.* 21(4): A 237-241.
- Lepper, A.W.D. (1972):* Research in Veterinary Science. 13; 105; 16; 287.
- Liao, C.H.; Erdman, J.R.; Vos, E.W. and Johnston, P.V. (1996):* Dietary vitamin A deficiency and the immune system in a murine model of systemic lupus erythematosus. *Nutrition Research* 16(2): 279-292.
- Markus, R.; Huzaira, M.; Anderson, R.R. and Gonzaliz, s. (2001):* A better potassium hydroxide preparation : In vivo diagnosis of tinea with confocal microscopy. *Arch Dermatology* 137(8): 1076-1078.
- Matthews, J.G. (1991):* *Outline of Clinical Diagnosis in Goats*. 1st ed. Butterworth. Heinemann Ltd., pp. 132-133.
- McDowell, L.R. (1989):* *Vitamins in Animal Nutrition: Comparative Aspects to Human Nutrition*. 1st ed. Academic Press, San. Diego, New York, Berkeley, Boston, London, Sydney, Tokyo and Toronto.
- Nakamura, Y.; Watanabe, S. and Hasegawa, A. (1999):* Dermatomycosis in human and animals. *Nippon Ishinkin Gakkai Zasshi*, 40(1): 9-14.
- Nashwa, Khalifa, O. (2001):* Zoonotic aspect of *Trichophyton mentagrophytes* in rabbit farms. *Beni-Suef. Vet. Med. J.* 11(2-A): 49-56.
- Niewerth, M. and Korting, H.C. (2000):* The use of systemic anthimycotics in dematology. *Eur. J. Dermatol.* 10: 155-160.
- Nobert, W.T. (1986):* Method of determination of vitamin A and β -Carotene chemistry. *Text Book of Clinical Chemistry* 1st ed. W. Saunders Company Philadelphia, London, Mexico Toronto: 336-960.

- Nonnecke, B.J.; Horst, R.L.; Waters, W.R.; Dubeski, P. and Harp, J.A. (1999):* Modulation of fat soluble vitamin concentrations and blood mononuclear leukocytes populations in milk replacers fed calves by dietary vitamin A and β -carotene. *J. Dairy Sci.* 82(12): 2632-2641.
- Norris, H.A.; Elewski, B.E. and Ghannoum, M.A. (1999):* Optimal growth conditions for the determination of the antifungal susceptibility of three species of dermatophytes with the use of microdilutions method. *J. Am. Acad. Dermatol.* 40(6, part 2).
- Osman, S.A.; Amer, S.A.; Abou-Rawash, A.A. and Mehrez, A.F. (2002):* Dermatophytosis in cattle: Clinical, Histopathological and Therapeutic studies. *Assiut Veterinary J.* 47(94): 263-278.
- Pandey, V.S. and Mohin, L. (1980):* Observations on ringworm in goats caused by *Trichophyton verrucosum* Br. *Vet. J.* 136: 198-199.
- Paterson, S. (1999):* Miconazole/chlorhexidine shampo as an adjunct to systemic therapy in controlling dermatophytosis in cats. *J. Small Anim. Pract.*, 40(4): 163-166.
- Porgerson, P.R. and Abbott, Y.E. (1999):* Comparison of Sabouraud dextrose agar with an alternative selective medium for the detection of dermatophytes and their results of a clinical survey of cats and dogs. *Irish Vet. J.* 52: 141-144.
- Radostits, O.M.; Blood, D.C. and Gay, C.C. (2000):* *Veterinary Medicine* 9th ed. Bailliere, London, U.K.
- Rycroft, A.N. and McLay, C. (1991):* Disinfection in the control of small animal ringworm due to *microsporum canis*. *Vet. Rec.* 129(11): 239-241.
- Scott, D.W. (1988):* *Large Animal Dermatology*, Philadelphia, W.B. Saunders, pp. 172-182.
- Smith, B.P. (2002):* *Large Animal Internal Medicine. Diseases of Horse, Cattle, Sheep and Goats.* 4th ed. Mosby.
- Smith, M.C. and Sherman, D.M. (1994):* *Goat Medicine.* 1st ed. Lea and Febiger.
- Snedecor, G.W. and Cochran, W.G. (1980):* *Statistical Methods.* 8th ed. the Iowa State, University Press, USA.
- St. Germain, G. and Summerbell, R. (1996):* *Identifying filamentous fungi.* Star Publishing, Belmont, C.A.
- Stannard, A.A. (1988):* *Syllabus for Veterinary Dermatology*, Davis, California, University of California.

Torres, B.F.; Cabanes, F.J.; Carrillo, A.; Esteban, A.; Tnza, T.; Abarca, L. and Guarro, J. (2002): Collaborative evaluation of optimal antifungal susceptibility testing conditions for dermatophytes. JCM, 40(11): 3999-4003.

Weitzman, I. and Summerbell, R.C. (1995): The dermatophytes. Clinic. Microbiol. Rev. 8: 240-259.

Willis, I.B. (1960): The determination of metals in blood serum by atomic absorption spectrophotometry. Spector. Chem. Acta, 16: 259-272.



Fig. 1: A kid showing circumscribed circular lesions in the face and external ear.

Fig. (2): A kid showing circumscribed circular lesions in the neck and limbs.

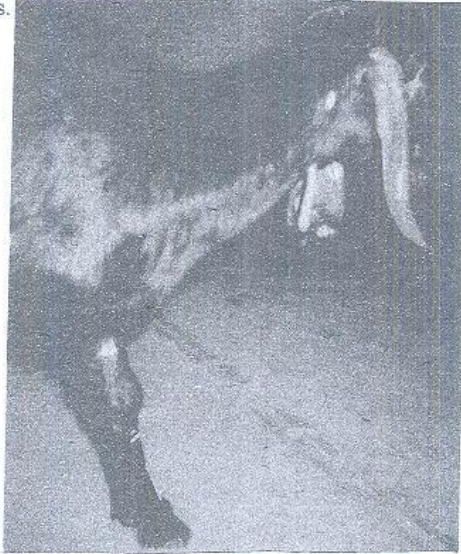


Fig. (3): A kid showing irregular coalesced lesions in the external ear.

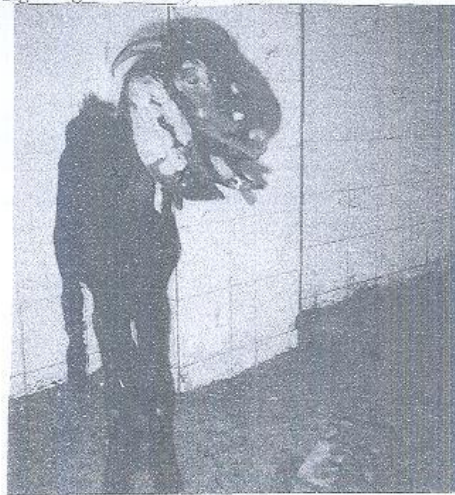



Fig. (4): A group of kids showing lesions of ringworm.

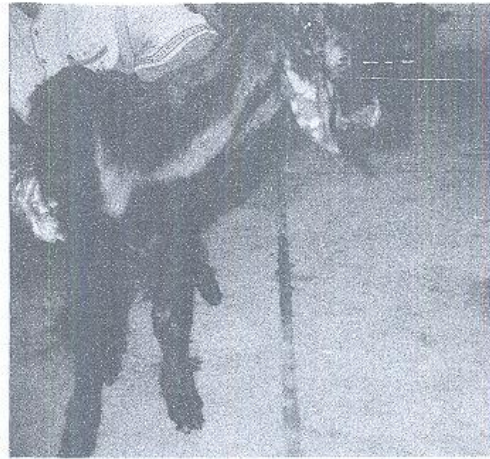

Fig. (5): A kid showing lesions before treatment.



Fig. (6): A kid after two weeks of treatment.




Fig. (7): A kid after three weeks of treatment.