

Dept. of Surgery, Anesthesiology and Radiology,  
Faculty Vet. Med., Cairo Univ., Beni-Suef Branch.

## PERMANENT URINARY DIVERSION IN RUMINANTS

(With 16 Figures)

By

**M.M. SEIF; M. ABDEL-FATTAH and A.M. SEDEEK**

(Received at 26/6/2005)

التحويل الدائم لمجرى البول في المجترات

محمد مصطفى محمد سيف ، محمد عبد الفتاح ، ايمن صديق

هدفت هذه الدراسة الى تقييم التدخل الجراحي اللازم لتحويل مجرى البول بصفة مستديمة في المجترات وذلك بواسطة تثبيت انبوب بالمثانة البولية. والجدير بالذكر ان هذه الطريقة يمكن استخدامها كعلاج جراحي لبعض حالات الاحتباس البولي الحرجة. تم اجراء التدخل الجراحي على مجموعتين من الحيوانات. المجموعة الاولى وهي تجريبية احتوت على ٦ من الماعز و٤ من عجول الابقار وقد تم فحص الحيوانات قبل اجراء التدخل الجراحي وتم متابعتهم بعد التدخل الجراحي باستخدام الموجات الفوق صوتية. اما المجموعة الثانية فقد اشتملت على ٤٧ حالة اكلينيكية (٢٢ من الماعز و٢٥ من عجول الابقار) وقد خضعت هذه الحيوانات لنفس التدخل الجراحي. ومن خلال متابعة وفحص الحيوانات وجدنا ان هناك جدوى من عمل التحويل الدائم لمجرى البول كعلاج جراحي لحالات الاحتباس البولي الحرجة في المجترات.

### SUMMARY

Permanent urinary diversion by using tube cystostomy was evaluated for its efficacy in treatment of selected cases suffered from urine retention in experimental and clinically affected animals. Experimentally, urine retention was induced then urinary diversion was performed in six male goats and four bull calves. All animals were observed for five months after operation. Pre and post-operative ultrasonographic examination was conducted for technical evaluation. Clinically, urinary diversion was performed in 22 male goats and 25 bull calves. It is concluded that the permanent urinary diversion by using tube cystostomy appears to be effective and satisfactory for management of selected cases of urine retention in ruminants.

**Key words:** Urinary diversion, cystostomy, urine retention.

## INTRODUCTION

Surgical diversion of body secretions or excretions is one of the most important surgical treatment used for management of complicated un-operable obstruction of normal passway, e.g.; conjunctivorhinostomy (Ismail and Attia, 1991); ureterosotomy and cystostomy (Ragab, 1989); intestinal bypass (Orsini and Donawick, 1986 and McIlwraith and Robertson, 1998); tracheostomy (Turner, *et al.*, 1982); and temporary tube cystostomy (Rakestraw, *et al.*, 1995 and Ragab and Seif, 1997).

Urinary diversion is indicated in case of recurrent urethral obstruction, chronic dysurea associated with urolithiasis, strangurea due to para-urethral tissue enlargement, acute urethral obstruction, dysurea following infra-anal urethroscopy, urethral anastomosis, and urethroplasty (Skelcher and Steele, 1978; Cooley, *et al.*, 1999; Nolte, *et al.*, 2002 and Gill and Gary, 2004).

Tube cystostomy is performed routinely for temporary or permanent urinary diversion. Temporary diversion may be performed concurrently with surgical repair of urethral trauma or to relieve acute urethral obstruction, while permanent tube cystostomy is indicated in cases suffering from complicated un-operable lower urinary tract obstruction (Cornell, 2000).

Temporary tube cystostomy could be achieved by using an indwelling Foley catheter (Pearce, *et al.*, 2003). On the other hand, permanent tube cystostomy was performed by a commercially available gastrostomy tube to achieve long-term urinary diversion especially in cases suffering from excessive granulomatous urethritis (Salinardi, *et al.*, 2003).

Tube cystostomy may be inserted percutaneously with ultrasonographic guidance (Streeter, *et al.*, 2002) or trans-abdominally through paramedian celiotomy (Oehme and Tillmann, 1965 and Rakestraw, *et al.*, 1995).

Conventional surgical techniques for treatment of lower urinary tract obstruction have been associated with stricture formation and subsequent recurrence of urethral obstruction leading to short-term prognosis, while tube cystostomy provided a long-term prognosis with minimal complications (Rakestraw, *et al.*, 1995).

## MATERIALS and METHODS

Ten experimental cases and 47 clinical cases were the subject of this study. Experimental cases involved six healthy native un-castrated



goats and four healthy bull calves of mixed breed. All animals were used for evaluation of permanent tube cystostomy as a method for urinary diversion. The age and weight of the experimental models ranged from 14-24 months and 20-35 kg b.wt. for goats and 7-18 months and 120-190 kg.b.wt for calves.

The clinical cases either in the veterinary practices or admitted to the clinic of veterinary surgery, faculty of veterinary medicine, Cairo University, Beni-Suef branch, were recorded and investigated clinically. The age and weight of the clinical cases ranged from 11-30 months and 18-42 kg b. wt. For goats and 8-20 months and 120-250 kg b. wt. for calves, and the breed was native breed in goats and balady or mixed breed in case of calves.

**Examination of the clinical cases revealed:**

- (a) 17 cases (7 goats and 10 calves) suffered from recent ruptured urethra 5-7 days after urethrotomy, and the clinical signs were inflammatory edema and urine infiltration in the ventral abdominal wall and presence of clotted blood and /or sabulous at the preputal opening.
- (b) 19 cases (10 goats and 9 calves) had stricture of the infra-anal urethrostomy and animals showed vocalization associated with urination attempts, bladder distension and scalds at the perineal as well as scrotopreputal region.
- (c) 5 castrated goats suffered from chronic dysurea with intermittent urine retention.
- (d) 6 calves suffered from ruptured urinary bladder as a sequellae of obstructive urethroliths with large stones that lodged at the neck of the bladder. Affected animals had urineprous odor of breathing, and abdominal distension.

Rayel's tube or nasoduodenal tube\* was used as cystostomy tube (size 8 and 10 for goat and size 12 and 14 for cattle calves) for both experimental and clinical cases (Fig. 1).

The male genitalia and site of implantation of the permanent tube cystostomy are illustrated in Figure (2).

Urine retention in experimental animals was induced under the effect of tranquilizer, either through tight ligation of the urethral process in goats (Fig. 3), or by plugging the external urethral orifice with blind segment of rubber tube and reinforcing it in position by purse string suturing in bull calves, for five months (period of experiment).

---

\*Poly Medicure Limited, 105, sector 59, HSIDC Ind. Area, Faridabad, India

All experimental animals were hydrated by intravenous normal saline in a dose of 50ml/kg/day and rate of infusion of 4 ml/kg/hour for two hours only according to Spier, *et al.* (1996). After two hours these animals suffered from non-productive urinary effort then they were subjected to surgery.

The surgical interferences either in experimental or clinical cases were conducted under the effect of anesthesia in the following manner:

- Male goats were anesthetized by intravenous diazepam 0.5% in a dose rate of 2 mg/kg. B. wt., followed by slow intravenous thiopental sodium 2.5% in a dose up to 10 mg/kg. B. wt. (Abdel Fattah, 1999).
- Bull Calves were sedated by xylazine HCl 2% in addition to prepubic linear infiltration analgesia using lidocaine HCl 2% (Hall and Clark, 1983).

The animals to be operated were secured either laterally or in dorsal recumbency, and then they were routinely prepared for aseptic surgery. A left para-preputal oblique celiotomy was made to reach the caudal abdominal structures. The urinary bladder was identified against the abdominal wall and exteriorized carefully (Fig. 4).

The seat of cystotomy (2 cm length) was detected according to accessibility of the bladder after traction and avoidance of vessels and any compromised bladder wall (Fig. 5). Urine was aspirated and the bladder was inflated with sterile isotonic saline solution, the hub of the Rayel's tube was placed in the bladder through the cystotomy incision and the other free end was pulled out from a minute punctured externalizing incision at the ventral apical bladder wall (Fig. 6&7). The hub of the tube was secured within the bladder with two purse string sutures and the cystotomy incision was closed according to Ludovic, *et al.*, (2005) with continuous pattern (Fig. 8).

The free end of the Rayel's tube was brought out through second small puncture incision in the wall of abdominal musculature, below the first incision by 2-3 cm, and in front of internal preputal lamina. Then enough length of the tube was left in the abdomen for the further increase in the animal size, and the tube was fixed by purse string suture to the abdominal muscular layer to prevent leakage of urine form the abdominal cavity into the subcutaneous tissue. Then the para-preputal celiotomy was closed routinely (Fig.9).

The free end was tunneled within the internal preputal lamina via splitting of the fornix of the prepuce then brought out from the external preputal orifice by cranial traction using artery forceps (Fig. 10&11).



After establishment of the saline-urine outflow via the cystostomy tube (Fig. 12), the excess of the tube was excised and the remaining part was trapped to the inner preputial lamina parallel to the free end of the penis. Broad-spectrum antibiotic, non-steroidal anti-inflammatory and fluid therapy were employed after surgery for 5 successive days.

Pre and post operative ultrasonographic examination was carried out on experimental cases by using 3.5/5.0 MHz curved array electronic transducer (R40-401665) and 6.0/8.0 MHz linear array probe (6CM-401663).

The clinical cases were monitored either by regular visiting of veterinary practices or by asking the owner by telephone calls for long term results of urinary diversion (up to weight of marketing) by using permanent tube cystostomy technique.

## RESULTS

Pre-operative ultrasonographic examination revealed distended urinary bladder with anechoic contents. The bladder wall was thin and appeared hyperechoic than the contents. The initial part of the calf urethra was also visualized clearly (Fig. 13 & 14).

The experimental animals were kept under observation for 5 months after surgery. All cases were in good health with continuous urine outflow via the permanent cystostomy tube.

Complications were minimal, and the most frequent complication was blockage of cystostomy tube with blood clots in one goat and one calf, and these animals were managed conservatively by flushing of the tube without second surgical interference.

Two weeks following surgery, ultrasonographic examination of the experimental cases revealed presence of cystitis in two goats and one calf. The wall of the bladder was thickened and the contents appeared as a multiple uniformly distributed tiny echoes. The hub of the cystostomy tube was located in position (Fig. 15). These cases were treated conservatively and four, six and eight weeks after surgery, ultrasonographic examination revealed normal collapsed bladder with uniform lining mucous membrane. Hyperechoic appearance of the hub of the cystostomy tube was observed and its dilated part appeared floating within clear anechoic urine (Fig. 16).

Follow up information (1-6 months) was available for all the clinical cases. Information obtained either by telephone calls or by re-

examination of the patients. All the operated cases were alive with no recurrence of urinary obstruction, except two goats died from causes unrelated to urinary obstruction three months post-operatively and one calf suddenly died from unknown cause one month post-operatively.

The short-term complications included obstruction of the tube with blood clots in three goats and five calves, 24 hours post-surgically, and the animal had pushed these blood clots after considerable straining.

The long-term complications were rarely serious, despite the presence of lower urinary tract infection that was treated by gentamycine sulfate 5 mg/kg. b. wt intramuscularly, twice daily, for five successive days.

## DISCUSSION

Surgical interventions that were described for management of obstructive urolithiasis in ruminants were; amputation of urethral process, urethrotomy, penile amputation, and perineal urethrostomy (Oehme and Tillmann, 1965; Misk and Semieka, 2002; Susan and Asa, 2003 and Van Meter, 2005).

Stricture formation and urethral scaring at the surgical site might expose these animals for re-obstruction. Long-term results have been described as poor because of recurrent obstruction and many authors stated that the ruminants shouldn't be kept longer than 3-4 months after surgery as a result of high incidence of reobstruction (Bailey, 1984 and Susan and Asa, 2003).

The insertion of a urethral silicone shunt represented a valuable contribution to relief urethral obstruction but the most serious complication of this technique was rejection of the shunt within two weeks (Skelcher and Steele, 1978).

Obstructive urolithiasis was more common in fattening calves (8-24 months) and castrated goats as the diameter of the urethra was narrow and the urethral process is often poorly developed in young castrated goats and may even be fused to the end of the penis (Hofmeyr, 1987; Nancy, 1995; Sadiq, *et al.*, 1998; Phil, 2001 and Van Meter 2005).

Temporary urinary diversion by using tube cystostomy can be performed concurrently with surgical repair of urethral trauma or to relieve acute urethral obstruction (Cornell, 2000 and Nolte, *et al.*, 2002), but the high incidence of failure of the temporary cystostomy tube (Foley catheter) to remain fixed in position as a result of deflating of the



balloon was the most serious complication encountered and required additional surgery (Rakestraw, *et al.*, 1995).

External fixation of the free end of the Foley catheter to the skin at the ventral paracostal area facilitates infection of the urinary tract and the animal may be chewing the catheter (Van Meter, 2005).

Permanent urinary diversion should be considered in cases of ruptured urethra with subcutaneous urine infiltration and necrosis of scroto-preputal region, occlusion of the neck of the bladder with large sized rough stone, chronic dysuria and stranguria, neurogenic bladder, bladder cancer, and extensive granulomatous urethritis (Smith, *et al.*, 1995; Cornell, 2000 and Salinardi, 2003).

Bladder marsupialization as a method for permanent urinary diversion was attempted by May, *et al.* (1998); May, *et al.* (2002) and Fortier, *et al.* (2004), the results were unacceptable because of partial dehiscence of the bladder from the body wall, urinary obstruction as a result of seroma formation occluding the bladder stoma, urine scald, cystitis, and bladder mucosal prolapse.

Procedure for placement of permanent tube cystostomy (permanent bladder cannulation) is relatively simple, inexpensive and satisfactory until the operated animal completes its fattening period. This makes our technique more applicable to our field conditions.

Fixation of the free end of the permanent cystostomy tube inside the preputal lumen minimize the chance of urinary tract infection as well as protect it from licking and chewing by the patient or by other animals, also the moist nature of the internal preputal lamina as a result of presence of convoluted glands and lining squamous epithelium protect the preputal cavity from irritation by the continuous free flow of urine which voided from external orifice of permanent cystostomy tube (Hofmeyr, 1987).

Ultrasonography proved its efficacy as an ideal aid for studying the healthy and diseased urinary system (Nyland and Mutton, 1995). The contents of the healthy bladder were hypoechoic and the wall was uniformly thick and smoothly demarcated inside and outside. Thickness of the bladder wall depended on the amount of the urine in the bladder; it was thinner when the bladder was full (Abu Zaid, 1995). In cases suffered from cystitis, the bladder appeared with irregular thick hyperechoic wall, the urine appeared anechoic with multiple uniformly distributed tiny echoes and this is in agreement with Hafez and El Khodary (2001).

Permanent urinary diversion by using permanent tube cystostomy appears to be an effective and satisfactory therapeutic option when utilized in selected cases. As with all ruminants, surgical operations however the risks and possible benefits must be weighted against the overall expenses involved.

## LEGENDS

**Figure 1:** Rayel's (cystostomy) tubes size 10, 12 and 14.

**Figure 2:** Relevant surgical anatomy showing site of implantation of the permanent tube cystostomy. Bladder (B), penis (P), prepuce (Pr), scrotum (S), and cystostomy tube (T).

**Figure 3:** Ligation of urethral process.

**Figure 4:** Distended urinary bladder (b: bladder).

**Figure 5:** Seat of cystostomy.

**Figure 6 & 7:** Implantation of cystostomy tube in the bladder.

**Figure 8:** Securing of the tube in the bladder with purse string suture.

**Figure 9:** Closure of the 1<sup>st</sup> abdominal incision and fixation of the tube with purse string suture in the 2<sup>nd</sup> abdominal incision.

**Figure 10 & 11:** Cranial traction of the tube via preputial splitting.

**Figure 12:** Saline-urine outflow via the cystostomy tube .

**Figure 13:** Distended urinary bladder (B) with anechoic contents and hyperechoic thin wall.

**Figure 14:** Initial part of calf urethra (U) and bladder (B).

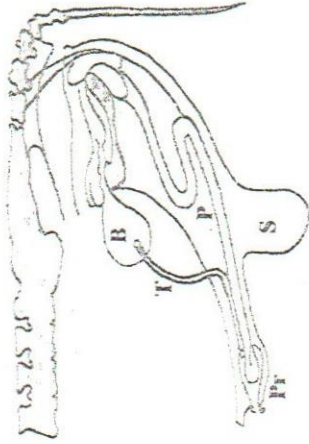
**Figure 15:** Thickening of the bladder wall (C), Bladder (B), Cystostomy tube (T).

**Figure 16:** Normal collapsed bladder with uniform lining mucous membrane, bladder (B), and cystostomy tube (T).

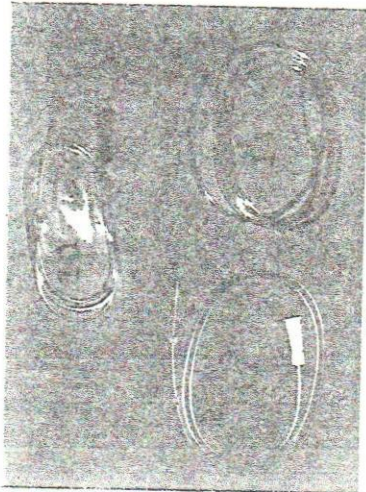




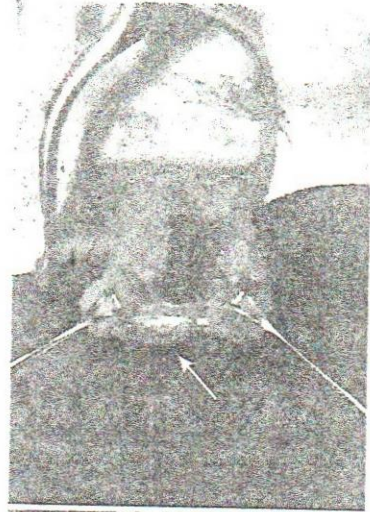**Figure 3**




**Figure 2**



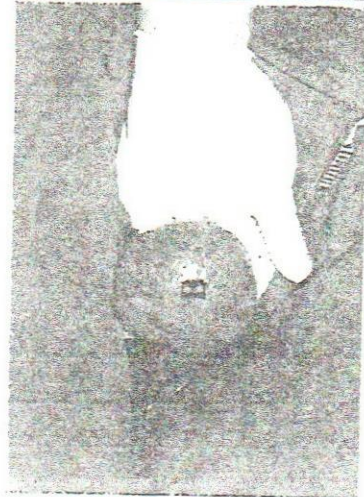**Figure 1**



**Figure 6**

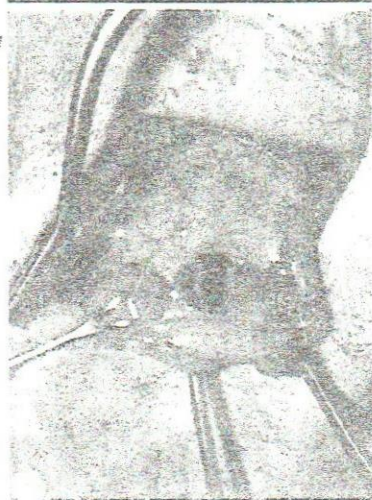


**Figure 5**

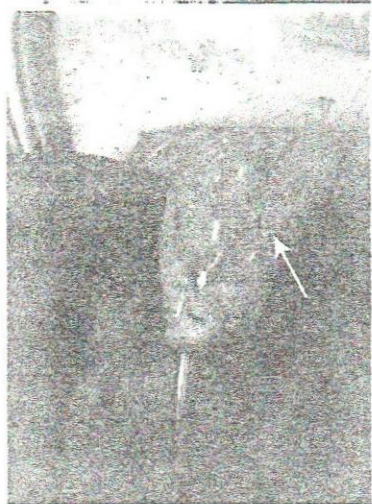

**Figure 4**





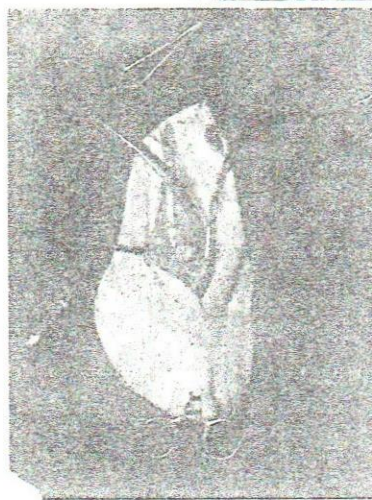
**Figure 7**




**Figure 8**



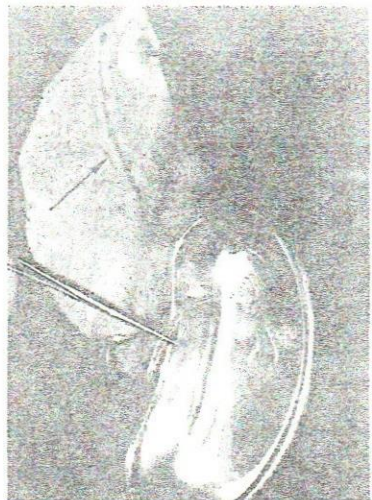
**Figure 9**



**Figure 10**

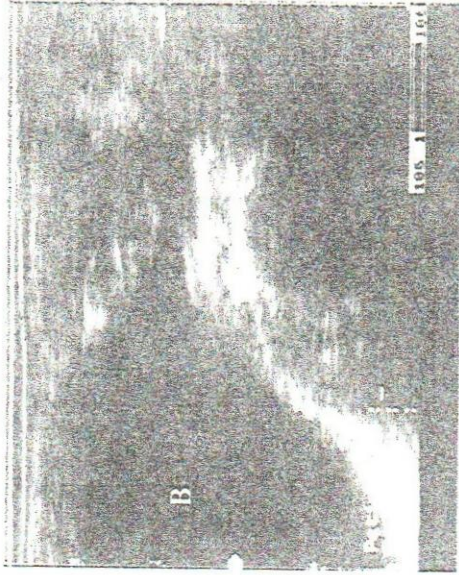


**Figure 11**

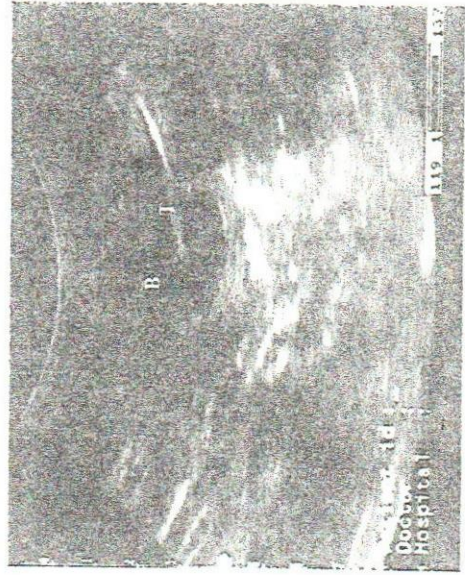

**Figure 12**

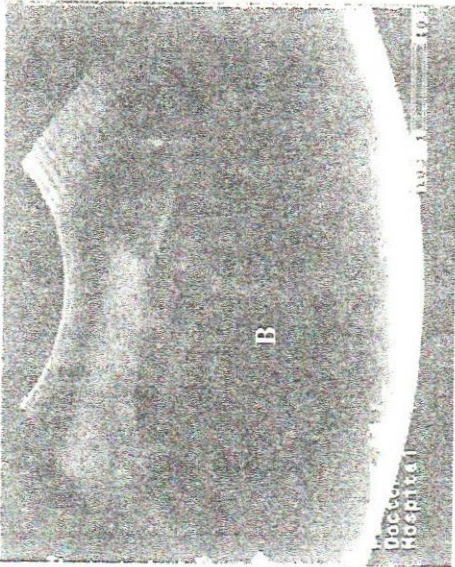



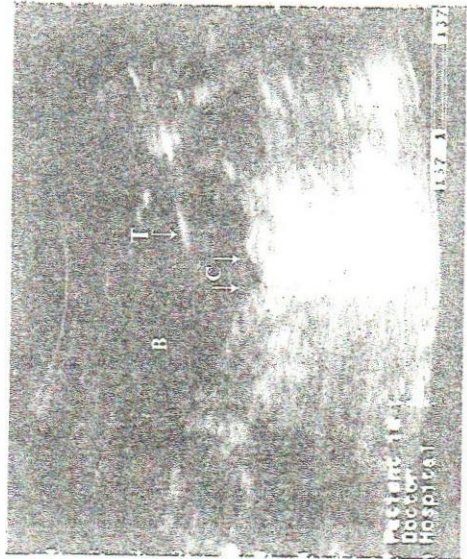**Figure 14**



**Figure 16**



**Figure 13**



**Figure 15**

## REFERENCES

- Abdel Fattah, M. (1999):* The goat as a model for experimental surgery. PhD thesis, Fac. Vet. Med., Cairo University, Beni-Suef branch, Egypt.
- Abu Zaid, R.M. (1995):* Radio and sonographic anatomical studies on the goat. MVSc thesis, Fac Vet Med, Suez Canal Univ. dept. of Anatomy and embryology.
- Bailey, D.E. (1984):* The male urogenital system. The practice of large animal surgery. Philadelphia, P.A. Saunders, Pp. 1105-1108.
- Cooley, J.A.; Waldron, D.R.; Smith, M.M.; Saunders, G.K.; Troy, G.C. and Barber, D.L. (1999):* The effect of indwelling transurethral catheterization and tube cystostomy on urethral anastomosis in dog. J. Am. Anim. Hospt. Assoc., Jul-Aug; 35 (4): 341-347.
- Cornell, K.K. (2000):* Cystotomy, partial cystectomy, and tube cystostomy. Clin. Tech. Small Anim. Pract., Feb.; 15(1): 11-16.
- Fortier, L.A.; Gregg, A.J.; Erb, H.N. and Fubini, S.L. (2004):* Caprine obstructive urolithiasis: requirement for 2nd surgical intervention and mortality after percutaneous tube cystostomy, surgical tube cystostomy, or urinary bladder marsupialization. Vet. Surg. Nov-Dec; 33(6): 661-667.
- Gill, M.S. and Gary, A.S. (2004):* Buccal mucosal graft urethroplasty for reversal of a perineal urethrostomy in a goat wether. Vet. Surg. July, 33(4): 382.
- Hafez, A.N. and El Khodery, S.A. (2001):* Ultrasonography of healthy and diseased sheep. Elmasoura Magazine, 3: 445-458.
- Hall, L.W. and Clarke, K.W. (1983):* Veterinary anesthesia. 8<sup>th</sup> ed., ELBS and Bailliere Tindall.
- Hofmeyr, C.F.B. (1987):* Ruminant urogenital surgery. Iowa state University press, A.M.E.S.
- Ismail, S.F. and Attia, M. (1991):* Conjunctivoralostomy and conjunctivorhinostomy for relief of epiphora in donkey. Assiut Vet. Med. J., 24(48): 217-229.
- Ludovic P.B.; Carolyn, L.K.; Simon, G.P.; John, R.; Jennifer, L. and Jeff, L.C. (2005):* Comparison of two laparoscopic suture patterns for repair of experimentally ruptured urinary bladders in normal neonatal calves. Vet. Surg, Jan, Vol. 34 Issue 1 Page 47.



- May, K.A.; Moll, H.D. and Duncan, R.B. (2002): Experimental evaluation of urinary bladder marsupialization in male goats. *Vet. Surg* 31: 251-258.
- May, K.A.; Moll, H.D. and Wallace, L.M. (1998): Urinary bladder marsupialization for treatment of obstructive urolithiasis in male goats. *Vet. Surg* 27: 583-588.
- McIlwraith, C.W. and Robertson, J.T. (1998): Equine surgery. Urethrostomy. Williams and Wilkins Awaverly Co.
- Misk, N.A. and Semieka, M.A. (2002): Clinical studies on obstructive urolithiasis in male cattle and buffaloes. *Assiut Vet. Med. J.*, Vol: 49, No.97, pp258-274.
- Nancy, W. (1995): Urolithiasis in Pygmy Goats. Reprinted by permission from Pygmy Goat WORLD magazine, Nov.
- Nolte, D.M.; Carberry, C.A.; Gannon, K.M. Boren, F.C. (2002): Retrospective study on temporary tube cystostomy as a treatment for urinary obstruction secondary to adrenal diseases in four ferrets. *J. Am. Anim. Hospt. Assoc.*, 38: 527-532.
- Nyland, T.G. and Mattoon, J.S. (1995): Veterinary diagnostic ultrasound. Chapter 8, Pp. 95-124, WB Saunders Co., Philadelphia.
- Oehme, F.W. and Tillmann, H. (1965): Diagnosis and treatment of ruminant urolithiasis. *JAVMA*, 147 (12) 1331-1339.
- Orsini, J.A. and Donawick, W.J. (1986): Surgical treatment of gastroduodenal obstruction in foals. *Vet. Surg*, 15: 205-213.
- Pearce, S.G.; Dearo, A.C.; Howard, B.E. and Brisson, B.A. (2003): Management of obstructive urolithiasis and concurrent urethral rupture in a goat. *Aust Vet. J.*, May; 81 (5): 268-270.
- Phil, R. (2001): Urinary Calculi in Lambs and Calves. Grange Research Centre, Dunsany, Co. Meath, Ireland 21-Mar
- Ragab, G.A. and Seif, M.M. (1997): Urolithiasis in bull and buffalo-bull calves in Beni-Suef governorate. Part I- surgical management. 4th Sci. cong, Egypt. Soci. for Cattle Dis, 7-9 Dec., Assiut, Egypt.
- Ragab, G.A. (1989): Some studies on the surgery of the urogenital system in small ruminants. PhD. thesis, Fac. Vet. Med, Cairo University, Egypt.
- Rakestraw, P.C.; Fubini, S.L.; Gilbert, R.O. and Ward, L.O. (1995): Tube cystostomy for treatment obstructive urolithiasis in small ruminants. *Vet. Surg. Nov. Dec.*; 24 (6): 498-505.

- Sadiek, A.II.; Sayed, A.S.; Eissa, N.A. and Osman, F. (1998):* Clinical and laboratory studies on ruptured urinary bladder and urethras a sequellae to obstructive urolithiasis in fattening calves. *Assiut Vet. Med. J.*, Vol. 39 No. 78, pp 26-41.
- Salinardi, B.J.; Marks, S.J.; Davidson, J.R. and Senior, D.F. (2003):* The use of a low- profile cystostomy tube to relieve urethral obstruction in a dog. *J. Am. Anim. Hosp. Assoc.*, Jul-Aug; 39 (4): 403-405.
- Skelcher, P.B. and Steele, R.B.T. (1978):* Use of a silicone shunt for the surgical relief of feline urethral obstruction. *Vet. Rec. Feb.*, 102: 98-99.
- Smith, J.D.; Stone, E.A. and Gilson, S.D. (1995):* Placement of a permanent cystostomy catheter to relieve urine outflow obstruction in dogs with transitional cell carcinoma. *JAVMA*, Feb., 15; 206 (4): 496-499.
- Spier, S.J.; Snyder, J.R. and Murray, M.J. (1996):* Fluid and electrolyte therapy for gastrointestinal disorders: In Bradford, P. S. (ed): *Large animal internal medicine*. Pp: 775-783, 2<sup>nd</sup> ed., copyright by Mosby Co.
- Streeter, R.N.; Washburn, K.E. and McCauly, C.T. (2002):* Percutaneous tube cystostomy and vesicular irrigation for treatment of obstructive urolithiasis in a goat. *JAVMA*, Aug., 15; 221(4): 546-549.
- Susan, E.A. and Asa, M. (2003):* Noninfectious Diseases of the Urinary System In Large Animals, Urolithiasis in Ruminants. *The merk veterinary manual*; 8th Edition
- Turner, A.S.; McIlwraith, C.W. and McCracken, T. (1982):* Techniques in large Animal Surgery. PP. 254, Lea and Febiger.
- Van Metre, D.C. (2005):* Urolithiasis in Small Ruminants: Surgical and Dietary Management. Hotopics, internet, Colorado State University.