

Dept. of Surgery,  
Fac. Vet. Med., South Valley University Qena.

## **A FIELD STUDY ON LUMPY SKIN DISEASE**

(With One Table and 13 Figures)

By

**A.A.A. ABD – EL – HADY**

(Received at 20/3/2006)

**دراسة حقليّة عن مرض الجلد العقدي**

**عبد الناصر عبد المنعم عزب عبد الهادي**

أجري هذا البحث في صيف ٢٠٠٥ بمحافظة دمياط أثناء انتشار وباء الالتهاب الجلدي العقدي، وقد تم فحص عدد ٨٥ رأس من الأبقار الخليطه من أعمار مختلفة من الذكور والإناث وكذا رأسين من العجول الجاموس، وقد سجلت الأعراض الإكلينيكية في كل حالة حيث أظهرت ارتفاع في درجة الحرارة (٤٠-٤١,٥) وفقدان الشهية وتوقف إدرار الحليب وإفرازات مخاطية من الأنف وتضخم الغدد الليمفاوية الظاهرية مع الضعف العام والهبوط وتورم في الأرجل مع عرج واضح وتبدأ العقد الجلدية في الظهور على شكل طفح جلدي في مناطق الجسم المختلفة ما يلبث أن يختفي أو يتحول ألي عقد تتركزيه قد تشمل الأنسجة تحت الجلد. ثم قسمت الحيوانات إلي ثلاثة مجموعات حسب شدة ظهور الأعراض عليها وقد تم العلاج في المجموعتين الأولى والثانية باستخدام مستحضر الاموكساسيلين ط . م كمضاد حيوي وديكلوفينات الصوديوم كمضاد للالتهاب وقد ثبت انه من الضروري التبرير بالعلاج المكثف في المجموعة الأولى ولمدة تتراوح بين ٧-١٠ أيام حتى لا تحدث المضاعفات التي تؤدي إلي السنفوق . أما المجموعة الثانية فيلزم العلاج فقط مرة واحدة بمضاد الالتهاب المذكور وأحياناً المضاد الحيوي ط . م أما المجموعة الأخيرة فلم تحتاج إلي علاج حيث تغلبت الحيوانات على المرض دون حدوث أية مضاعفات.

### **SUMMARY**

The study was carried out during an outbreak of LSD in the period from June to September 2005. The affected animals were kept in a small holder groups in different localities in Damietta Governorate. Clinical signs were described in detail. Fever, anorexia, depression, agalactia, multiple skin nodules are distributed anywhere all over the body, enlargement of superficial lymph nodes, odema of the dependent parts particularly the limbs were the most common signs in diseased cases. Based on the severity of the clinical signs, the diseased cases were classified into 3 groups. The first group was treated by antibiotic

(Amoxicillin L.A) and non-steroidal anti-inflammatory drug (Declophenac sodium) for 7-10 consecutive days. One shot treatment was found effective in the second group, while the third group (inapparently affected) can overcome the disease without treatment. Septic lesions met with in some cases were treated surgically. The main objective of this study is to find-out a guide line for management of LSD to prevent or minimize its complications and losses.

**Key words:** *Lumpy skin disease, cattle, buffalo.*

## INTRODUCTION

Lumpy skin disease (LSD) was firstly reported in Egypt in May 3, 1988 (Fayed, 1988 and Salem, 1989). It was appeared in Suez Governorate and the source of infection was the imported cattle from Somalia. The causative agent of LSD is a Neethling virus, genus capripox virus in the family Poxviridae (Murply *et al.*, 1999). There is only one report of the natural occurrence of LSD in a species other than cattle, in water buffalo (*Bubalis*), but no further such cases are recorded (House, 1989; Davies, 1991 and Radostits *et al.*, 1994). Clinical signs of LSD were varied according to severity of the disease. Fever (40-41.5 °C) may be transitory or last up to 4 weeks. Depression, anorexia, excessive salivation, oculo-nasal discharge, agalactia and emaciation are presented. Nodules 1-7 cm in diameter may occur any where on the body especially in the skin of the muzzle, nares, back, legs, scrotum, perineum, eyelids, ear, nasal and oral mucosa and tail. The hair stands erect over early skin lesions. The nodules are painful and involve the epidermis, dermis and subcutaneous tissue and may even involve the underling musculature. As the disease progresses, the nodules became necrotic with a deep scab (sitfast) forms (El - Kanawaty, 1989; Ismail 1989 and House 1998). Lesions on the udder and teats can result in mastitis, fistula or teat obstruction (Heidrich and Renk 1967; Ismail 1989 and House 1998).

Lameness due to tendosynovitis, laminitis and septic arthritis when secondary bacterial infection occurs. Severe odema in the brisket, ventral abdomen and legs may be evident (El-Kanawaty, 1989; Kenawy, 1991 and House 1998). No specific treatment for LSD and alleviated treatment of the severely affected animals is suggestive to decline the production losses induced by the disease and to prevent its complications associated with secondary invaders. The later was aimed in the present study.

## MATERIALS and METHODS

The present study was carried out during the period from June to September (2005). A total number of 85 crossbred cattle of different ages and sexes as well as two male buffalo calves were clinically examined. These animals were kept in a small group in different localities in Damietta Governorate, Egypt. Based on the severity of clinical signs, the examined animals were classified into the following :

Group I: Severely affected and comprise 46 animal, group II: moderately affected and comprise 15 animal and group III: inapparently affected and comprise 26 animals (Table 1). Clinical signs and line of treatment for each group was recorded. Treatment trials were performed using amoxicillin L. A (Trioxyl )<sup>(1)</sup> in a dose of 15 mg / kg B. Wt (1ml / 10kg B.Wt) deep intramuscular injection and declophenac sodium (Declophlame<sup>(1)</sup> 2.5%) in a dose rate 4 ml / 100 kg. B.Wt i / m. Local treatment was performed in cases of septic lesions, using H<sub>2</sub>O<sub>2</sub>, Zinc oxide 10% ointment with cod liver oil combined systemic antibiotic.

**Table 1:** The number and groups of affected animals with LSD.

Species	No. of cases	Group classification		
		Group I	Group II	Group III
Cattle	85	45	15	25
Buffalo	2	1	-	1
Total no	87	46	15	26

## RESULTS

The clinical signs were varied among animal groups. In severely affected (group I) fever (40.5 – 41.5 °C), loss of appetite, oculonasal discharge and remarkable lameness was detected in 13 cases. Enlargement of superficial lymph node(s), odema of dependent areas, particularly the limbs (Fig. 1 & 2), submandibular space, brisket and ventral abdomen. Later on , the animal become depressed and emaciated. The hair stands-erect over and around early skin lesion. Multiple skin


<sup>(1)</sup> UNIVET ltd . tullyvin , cavan, Ireland .

<sup>(1)</sup> EL-NASER Co for universal Industrial pharmaceutical co sole agent – EL ABRAR CO.

nodules were spreading over the body areas (Fig. 3&4). The nodules were painful, varied in size (from 1 – 7 cm in diameter) and may coalesce to form wide patches of skin necrosis (Fig. 5&6). The most common affected parts were skin of the muzzle, nares, back, legs, scrotum, udder, teats, eyelids, ears (Fig. 7 a&b) and tail. In group II the disease appears in a moderate form, anorexia, increase in body temperature up to 40.5 °C, skin nodules were fewer in number and scattered over the skin of the neck, back and abdomen (Fig. 8, 9 & 10). Signs of lameness may appeared in some cases. The animals in group III show inapparent or transient systemic disorders and one or more (1 – 5) nodule may appear anywhere on the body. A prolonged course of the disease with subsequent complications were seen in 10 cases, such as teat obstruction (2), mastitis (4), teat fistula (one case) (Fig. 11), septic arthritis (2) (Fig. 12&13) and blepharoconjunctivitis (1). Comprehensive treatment was found essential in severely affected group using amoxicillin L.A and declophenac sodium for at least 4 times which gave good results while in the second group one shot of injection was found effective.




**Fig. 1**



**Fig. 2**



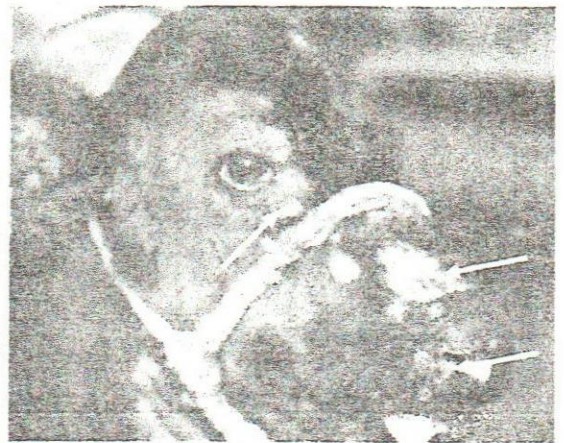**Fig. 3**



**Fig. 4**



**Fig. 5**



**Fig. 6**

## FIGURES DESCRIPTION

- Fig. 1&2:** Enlargement of prescapular lymph node, limb odema and nasal discharge in a male buffalo calf.
- Fig. 3&4:** Multiple skin nodules with the erected hair stands in a calf and later on in a cow
- Fig. 5, 6&7 (a&b):** Wide patches of denuded areas of skin after sloughing of nodules in a cow and calf (note: the perforated concha after sloughing).
- Fig. 8, 9&10:** Nodules in different stages in the neck, abdomen and back region.
- Fig. 11:** Sitfast on a teat, this lesion might result in a teat fistula /or mastitis.
- Fig. 12&13:** Septic arthritis of the carpal and phalangeal joints.

## DISCUSSION

In the present study, the clinical signs were markedly varied among the diseased animals; fever, skin nodules, depression, anorexia and lameness were the most common signs in severely affected animals. These are in agreement with (Fayed, 1988; Salem, 1989; Kenawy, 1991 & Murphy *et al.*, 1999).

Multiple skin nodules were painful, varied in size and involve the epidermis, dermis and subcutaneous tissue and even the musculature. The nodules become necrotic transformed into a hard dry scab (sitfast) for several weeks sloughing off leaving ulcers and severe necrosis of the exposed underling tissues. These findings are also recoded by (Kenawy, 1991 Radostits *et al.*, 1994 and House 1998).

Lameness was attributed to inflammation of the tendon, tendon sheaths, joints and laminae. Complicated cases of septic arthritis were ascribed to secondary bacterial infection of the necrotic nodules encroaching joints especially that of the lower extremities as they are covered by less musculature. Consequently the infection can easily penetrate and destroy the joint capsule leading to septic arthritis. Similar conclusions were reported by Ismail (1989), El- Kanawty (1989) and Kenawy (1991). In the present study, mastitis and / or teat obstructions are attributed to sloughed necrotic nodules from the udder parenchyma into teat cistern which may be complicated by secondary bacterial infection. Also, udder or teat fistula may result from such lesions when the skin of the udder and teat are involved. Similar finding was reported

by Heidrich and Renk (1967) and House (1998). It was noticed that, buffaloes may acquire natural infection and showing the signs of the disease with varying degrees particularly in young buffalo calves. A record which was reported the disease in water buffaloes (*Bubalis bubalis*) by House (1989), Radostits *et al.*, (1994) and House (1998), while buffaloes of (*Synercus Caffer*) have not been infected during epizootics (Davies, 1991). Treatment in all groups of animals is directed at: 1. alleviating acute symptoms. 2- controlling the secondary infection . Therefore, classification of the affected animals according to severity of the disease will provide the clinician how to manage the case so as to save cost of treatment and to fulfill a good results. A good recovery rate was obtained when timely and comprehensive treatment were performed in severely affected cases while delayed treatment or untreated cases result in a prolonged and complicated cases with eventual death.

## REFERENCES

- Davies, F.G. (1991):* Lumpy skin disease, an African capripox virus disease of cattle. *Br. Vet. J.*, 147, 6, 489-502.
- EL- kanawaty, Z.R.A (1989):* some studies on lumpy skin disease. Thesis M. V. SCI., Vet. Med., Zag. Univ., Benha, Egypt.
- Fayed, A.A. (1988):* Exotic Animal Diseases reported in Egypt. The 2<sup>nd</sup> Sci., cong., Egyptian society for cattle diseases, 5-7 Dec. 1993, Assiut, Egypt 249-256.
- Heidrich, H.J. and Renk, W. (1967):* Diseases of the mammary glands of domestic animals. 1-st edition - W.B. Saunders company, Philadelphia and London.
- House, J.A. (1989):* Lumpy skin disease. In proceeding of the 93<sup>rd</sup> Annual Meeting of the united states Animal Health Association, 305-314.
- House, J.A. (1998):* Foreign Animal Diseases. "The Gray book", lumpy skin Disease. WWW. Vet. Uga. edu / VPP / gray – book / FAD / LSD. htm.
- Ismail, S.F. (1989):* The clinical symptoms and complications of lumpy skin disease. The 4-th Sci. Cong., Fac. Vet. Med., Assiut Univ., 379-384.
- Kenawy, A.A. (1991):* Surgical Handling of lumpy skin disease in cows . *Assiut Vet. Med. J.*, Vol. 26, No. 51, 253-240.
- Murphy, F.A.; Gibbs, E.P.J.; Horzinek, M.C. and Studdert, M.J. (1999):* Veterinary Virology. 3<sup>rd</sup> Edition, Family poxviridae, 277-291. Academic press: San Diego, California – London. Library of Congress Catalog Card Number: 0-12-51134-4.
- Radostits, O.M.; Blood, D.C. and Gay C.C. (1994):* Veterinary Medicine, A text book of Diseases of cattle, sheep, pigs, goats and horses. Eighth Edition – Bailliere Tindall.
- Salem, A.S. (1989):* Lumpy skin disease in Egypt. In O. I. E. Disease Information. Vol. 2. No. 2.