

EFFECT OF LOW LEVEL OF LASER THERAPY ON WOUND HEALING IN NUBIAN GOATS

OSMAN MARIA, E. *; OSMAN HIND, E. ** and MOHAMED O.S.A. ***

* Department. of Surgery, Faculty of Veterinary Medicine, Sudan University of Science and Technology.

** Department of Pathology, Faculty of Veterinary Medicine, Sudan University of Science and Technology.

*** Department. of Toxicology, Faculty of Veterinary Medicine, Sudan University of Science and Technology.

Email: hmmhmm12345@yahoo.com

ABSTRACT

Received at: 17/9/2013

Accepted: 14/11/2013

The aim of this study was to assess the pathological effects of different doses of Low-Level Laser Therapy (LLLT) on the healing of full-thickness skin wounds in goats. Full-thickness skin wounds were surgically created on the lateral aspect of the thigh of 24 Nubian goats. Those goats were divided randomly into four equal groups according to the time of scanning with continuous waves of He-Ne laser. Scanning with 0.00J/cm², 0.640J/cm², 1.28J/cm² and 2.00J/cm² was applied for 0, 200, 400 and 600 seconds daily for twenty one days to group I, II, III and IV respectively. LLLT treated wounds showed contraction and regression in size, enhanced reepithilization and acceleration in maturation phase. LLLT irradiation affects relief of pain positively. Each LLLT dose was found to affect the above parameters of wound healing differently but in conclusion the lower dose (0.640J/cm²) was found to be the most suitable dose to be used in wound healing in goatskin.

Key words: *Laser therapy, Wound healing, Nubian goats, goat skin.*

INTRODUCTION and LITERATURE REVIEW

Wounds are one of the main problems in animal health, whether surgical or nonsurgical. They are a major source of morbidity leading to considerable disability.

Many studies investigated the enhancement of the healing in animals using different methods (Scardino *et al.*, 1998; Gillette *et al.*, 2001), one of which is the LLLT (Hawkins *et al.*, 2005; Hawkins and Abrahamse, 2005). LLLT is a form of phototherapy involving application of low power monochromatic and coherent light to injuries and lesions. It has been used successfully to induce wound healing in nonhealing defects (Hawkins and Abrahamse, 2005 and Kara *et al.*, 2013) and to relief acute and chronic pain (Ladalaro *et al.*, 2005).

He-Ne laser irradiation stimulated the transition of the inflammatory phase of the wound healing into the reparative (proliferative) and scarring phases sequentially (Klebanov *et al.*, 2005). That was accomplished through earlier regress of the inflammatory phase, faster finishing of re-

epithelialization and acceleration in maturation phase (Vidinsky *et al.*, 2005).

Laser irradiation could accelerate capillary growth and germinal layer regeneration and when it is used, the production of fibroblasts and collagen increase; there is more granulation tissue formed; and the completion of epimerization is occurred three to four days earlier than in the control group (Wei and Li, 1996).

LLLT resulted in enhanced healing as measured by wound contraction (Hopkins, *et al.*, 2004) and atrophic scars (Brain *et al.*, 2005).

Few studies are done to know the effect of low level laser therapy on wound healing in animals (Mckibben, 1983; Mester and Mester, 1989; Bromiley, 1991).

There is no study in skin wound healing in Nubian goats in the Sudan. The objectives of this research work is to obtain wound care for healing promotion and to decrease the hazards of various skin wounds through identification of LLLT effect on healing of experimental full thickness skin wounds models in Nubian goats.

MATERIALS and METHODS

Experimental animals

Apparently healthy 24 females Nubian goats of 9-12 months of age and 35- 40 kg body weight were housed in cages in Sudan University Farm, at Helat Kuku, in Eastern Nile province. They were subjected to an adaptation period of seven days during which they were each given single s/c dose of Ivermectin (Kepromec 1%, Kepro B.W. Holland.) at a rate of 1mg/kg bw as anthelmintic. Those goats were given water and green fodder -alfalfa (*Medicago sativa*) - *ad libitum* for the whole experimental period which was 21 days. Animal grouping and dosing was done as in table (1).

Materials and methods for surgical procedure

Preparations

As described by Theresa *et al.* (2002) an area of 20x20 cm was clipped, scrubbed with a germicidal soap (Dettol antibacterial soap, Reckitt and Colman {overseas} Ltd. Hull, UK), shaved with sterile razor, cleaned and scrubbed with mild detergent containing tincture of iodine (povidone-iodine 10% USP Yamani Medical Products, Sudan, Khartoum). The prepared area was then allowed to dry. After that Alcohol (70% ethyl alcohol, Balsam Company for Chemicals Sudan, Khartoum) was applied to produce a fast kill of bacteria and acts as a defatting.

Anesthesia

Local infiltration analgesia- line block was achieved by subcutaneous injection at the surgical site (Thurmon *et al.*, 1996) using 2 ml of lidocaine (2% lignocaine hydrochloride 50 mg/ ml. P.P.L, Malta).

Surgery

An area of 1.5 x2 cm, in the lateral aspect of the right thigh over the biceps muscles was measured using a flexible measuring tape. An incision was made to perform an open wound involving all the layers of the skin (dermis and epidermis) using a sterile scalpel and tissue forceps. The bleeding from the superficial capillaries was controlled by direct pressure with sterile gauze. The wound was kept without dressing, cleaning or antibiotic.

Laser scanning and dosing

Five minutes post wounding, manual scanning with continuous waves (cw) was applied to the wound from a pointer of He-Ne laser probe (wavelength 630-680nm, max. output 1mw, China) to groups II, III, IV. The dose was calculated as: joule = "power (mw). Time (s)/ centimeter" of laser irradiation (Baxter *et al.*, 1994) in a wound surface area of $1.5 \times 2 \text{ cm}^2 = 3 \text{ cm}^2$ (Table-1).

Dosing was done and repeated once daily for 21 days in all experimental animals. Group I was the control group and received no LLLT dose.

Perfection

Batteries of the pointer were changed daily to insure the same dose of LLLT is given. The wound surface area was uniformly irradiated. The LLLT source was used as close as possible to the wound surface (0.5cm) to avoid scattered radiation. The low level laser therapy dose was given in the same time daily to all treated groups.

Gross appearance was recorded by standard digital photos using a digital camera (AIPTEK, China). Digital images were then recorded under the same conditions (distance, lighting, settings) as the original images.

Methods for detection of the Clinical manifestations

The animals were examined grossly for pain- using withdrawal reflex (Hellebrekers and Sap, 1997), bleeding, swelling, wound infection (Rochkind *et al.*, 1989), scab thickness, contraction and wound size (Braverman *et al.*, 1989) and scar size (Rochkind *et al.*, 1989). Photographic assessment of wound size and scab thickness and scar size were also done as described by Braverman *et al.* (1989)

Sampling and histopathological methods

Tissue sections of less than 0.2x0.5 cm were cut from the edges of the wound at different site at 18, 42, 66, 114 and 336 hours post wounding).

In accordance to the methods described by Bancroft and Gamble (1990), tissue sections were processed and stained with haematoxylin and eosin stain. The sections were examined microscopically to detect the inflammatory cells, edema, hyperemia, sebaceous gland necrosis, keratinosis, acanthosis, epithelial thickness, epithelial pseudopodes, papillary density, granulation tissue and melanin deposition.

RESULTS

Clinical manifestations

Pain

The relief of pain was improved in all laser treated groups compared with the control group. Desensitization was noticed in animals around the wounds after laser irradiation since the third hour post wounding.

Bleeding

The cutaneous bleeding was observed in all goats post wounding and it appeared again and continued for a short period after the first exposure to LLLT. Bleeding was found to be of small amount in group III and IV compared to group II.

Swelling

The effect of LLLT on the swelling was obvious in its level, spread into the adjacent areas around the

wound and the time taken to diminish. The swelling was less in all LLLT treated groups compared to the control group. The swelled area in LLLT treated animals was confined to 0.2 cm maximum around the wound boundaries in all treated groups while it was extended to about 1.5 cm in the control group (Figure1).

Infection

The control group showed wound infection with purulent exudate at 66 hours post wounding leading to the sloughing of the scabs formed at day 7 and day 17 post wounding. Apparently noninfected wounds (early healing) with no obvious pus are seen in the treated groups.

Scab thickness

In the control group the scab was either very thick, covering only part of the wound, or sloughed due to reinfection by day 7 and day 17 post wounding (Figure 2). In group II very thin or no scab formation was noticed. Thick scab was formed at the edges of the wound in group III, and in the middle of the wound in group IV. In all treated groups, whenever there was a scab formed, it was sloughed by day thirteen post wounding leaving a scar in the underneath tissues.

Contraction and wound size

Compared with the control group, decrease in wound size was obvious 66 hours post wounding in the LLLT treated groups and continued in all treated animals throughout the following 18 days of the experiment. The LLLT dose given to group II induced much wound contraction.

Scar

None of the animals in the control group showed complete healing or scar formation during the 21 days of the experiment. Small scar was observed grossly in all LLLT treated groups. Group II showed complete healing and very small size of scar by day 15 post wounding. Whitish granulation tissue was observed in the center of the wounds in group III by that time. Very small scar was formed by day 21 in group III and IV. The skin resemble the normal skin with hair growth in all LLLT treated groups.

Histopathological results

The effect of LLLT on inflammatory cells, eodema, hyperaemia, sebaceous gland necrosis, acanthosis, epithelialization, keratinosis, papillary density, granulation and melanin deposition in the healing of experimentally induced full-thickness skin wounds in Nubian goats is shown in table (2).

Inflammatory cells

Inflammatory cells, including macrophages, were observed in all the tissue samples taken 18 hours

post wounding from all experimental animals (Figure 3. A), and disappeared after 66 hours in group II, III and IV. In the control group the inflammatory cells were detected in all sections taken during the 336 hours of sampling.

Oedema

Oedema was detected in all the tissue sections of all experimental groups after 18 hours post wounding. It was very sever in the control group, sever in group II and was moderate in group III and IV. It continued to increase in the first 42 hours and disappeared at 66 hours post wounding in the tissue sections of group II and III.

Hyperaemia

Hyperemia of the epidermis was observed in the tissue sections of taken at 18 hours post wounding from all animals including the control group. (Figure 3. B). It was sever in group I and II, moderate in group III and group IV. Hyperemia increased in group I and II at 42 hours post wounding became very sever and was stable in the other two groups. 66 hours post wounding hyperaemia decreased in the three LLLT groups with more decreased level in group III and IV and disappeared in the control group. Hyperemia is also observed in the papillary dermis after the first 18 hour of wounding.

Necrosis of sebaceous glands

Sebacious gland necrosis was not detected in the tissue sections of the control group after 18 hours post wounding. Moderate necrosis was detected in the tissue sections of group II and slight necrosis was observed in group III and IV at 18 hours post wounding. An increase in sebaceous gland necrosis was seen in the tissue sections of group I and IV at 42 hours post wounding.

Acanthosis

Presence of thickened epidermis was observed in all tissue samples taken after 42 hours post wounding from all groups, with least acanthosis in group IV and the control group.

Epithelialization

Epithelial pseudopodes and delayed epithelialization were not detected in the control group. Epithelialization started in the LLLT treated animals by 42 hours post wounding, and continued to increase as epithelial pseudopodes (Figure 3. C) bridging the wounded area and leveling it (Figure 3. D). After 114 hours post wounding there were no epithelial pseudopodes in the tissue sections and pseudohyperplasia in the surface of the epithelium was detected in group II and III (Figure 3. F). Pseudohyperplasia in group IV was detected in the tissue sections taken at 336 hours and was of the same intensity as that of group III.

Keratinosis

Keratinosis was observed in group II and III after 42 hours (Figure 3. E) while in group IV it was observed at 66 hours post wounding. At 114 hours post wounding it increased in group II, III and group IV.

Papillary density

Density of the papillary dermis in the tissue sections of the control group and group II was found to be more or less the same while denser ones were detected in the tissue sections of group III and IV at 42 hours post wounding.

Granulation

The granulation tissue and the newly formed collagen were observed in group II, III and IV at 66 hours post wounding and continued to increase and to be more regular (Figure. 3. G) in the following sampling times-114 and 336 hours post wounding. In the latter sampling time the granulation tissue density became almost the same in the three LLLT treated groups. Little granulation tissue was detected in the control group at 114 hours post wounding.

Melanin deposition

In the tissue sections taken after 114 hours melanin deposition was observed only in group II and III. It was observed in all LLLT groups at 336 hours post wounding.

Table 1: Low level laser therapy (LLLT) doses in Nubian goats.

Animal group	Group I	Group II	Group III	Group IV
Laser dose (Joule\ cm²)	0.000J\ cm ²	0.640J\cm ²	1.280J\cm ²	2.00J\cm ²
Time of scanning/sec	non	200	600	900
Type of scanning	non	C w	C w	C w
Type of laser	non	He-Ne	He-Ne	He-Ne
Frequency of doses	non	daily	Daily	daily
Total period of dosing	21 day	21 day	21 day	21 day
Number of goats	6	6	6	6
Power Density	Zero w	1w	1w	1w
Wave length	Zero nm	630-680 nm	630-680 nm	630-680 nm

C w: continuous wave; He-Ne: Helium-Neon.

Table 2: The effect of LLLT on histological parameters of induced full-thickness skin wounds in Nubian goats.

Hours	Histological parameters	Group 1	Group 11	Group 111	Group V1
18 hours	Inflammatory cells (macrophages)	++++	++++	+++	+++
	Oedema	++++	++++	++	++
	Hyperemia	+++	+++	++	++
	Sebaceous gland necrosis	-	++	+	+
42 hours	Inflammatory cells	++++	+++	+++	++
	Oedema	++++	++++	++++	++
	Hyperemia	++++	++++	++	++
	Sebaceous gland necrosis	+	++	+	++
	Keratinosis	-	++	+++	-----
	Acanthosis	++	+++	++++	++
	Epithelial pseudopodes	-	++	+	+
	Papillary density	+	+	+++	+++
66 hours	Inflammatory cells	+	-	-	-
	Oedema	++++	-	-	+
	Hyperemia	-----	++	+	+
	Keratinosis	-----	++	+++	+
	Acanthosis	++	++	+++	+
	Epithelial pseudopodes	-	++	++	++
	Granulation tissue	-	+	+	+
114 hours	Inflammatory cells	+	-	-	-
	Keratinosis	-	+++	++++	++
	Acanthosis	+	++	+++	+
	Granulation tissue	+	++	+++	+++
	Pseudo hyperplasia and epithlization	-	+	+	-----
	Melanin deposition	-----	+++	+++	-----
336 hours	Inflammatory cells	+	-	-	-
	Melanin deposition	+	+++	+++	+++
	Granulation tissue	++	++++	++++	++++
	Pseudohyperplasia and epithlization	-----	++	+++	+++
	Melanin deposition	-	+++	+++	+++z

(- = negative reading; + = mild ; ++ = moderate; +++ = severe; ++++ = very severe)
 ----- = no reading (not found due to the small size of the tissue sample)

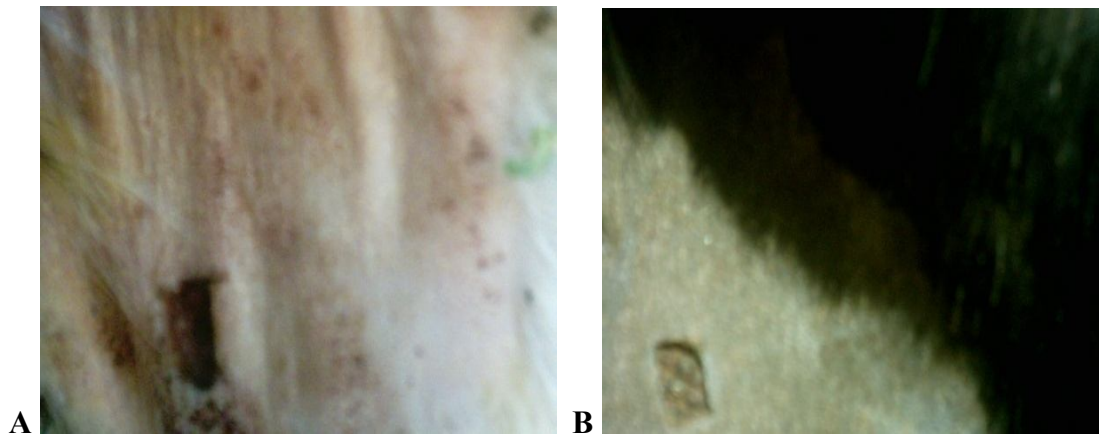


Figure 1: Swelling (arrows) in Nubian goatskin A. LLLT nontreated wound and B. and LLLT treated wound at a dose of 0.640 J/cm^2 .

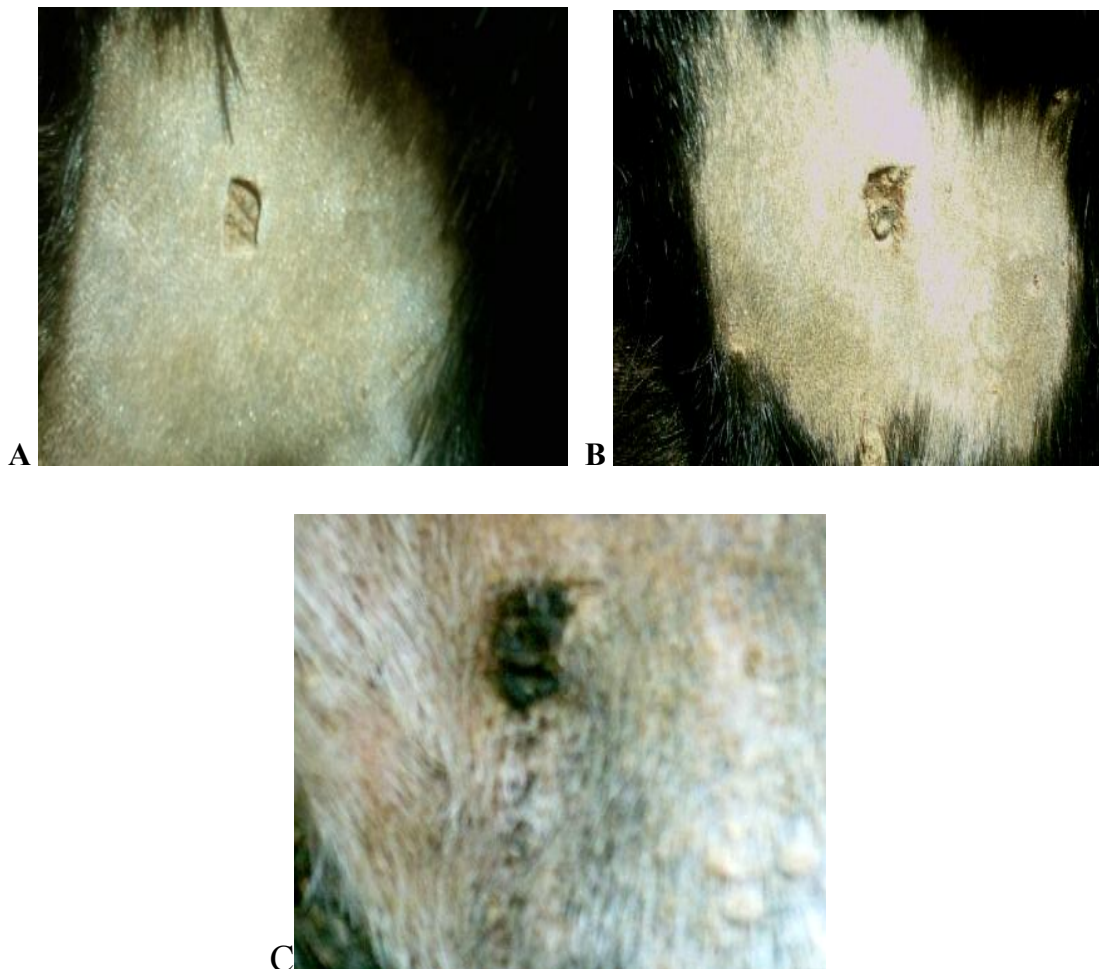


Figure 2: Absence of scab in a low-level laser therapy treated full-thickness skin wound in a Nubian goat four days post wounding (LLLT dose A. = 0.640 J/cm^2 , B. = 1.28 J/cm^2 , C. = 0.000 J/cm^2 B).

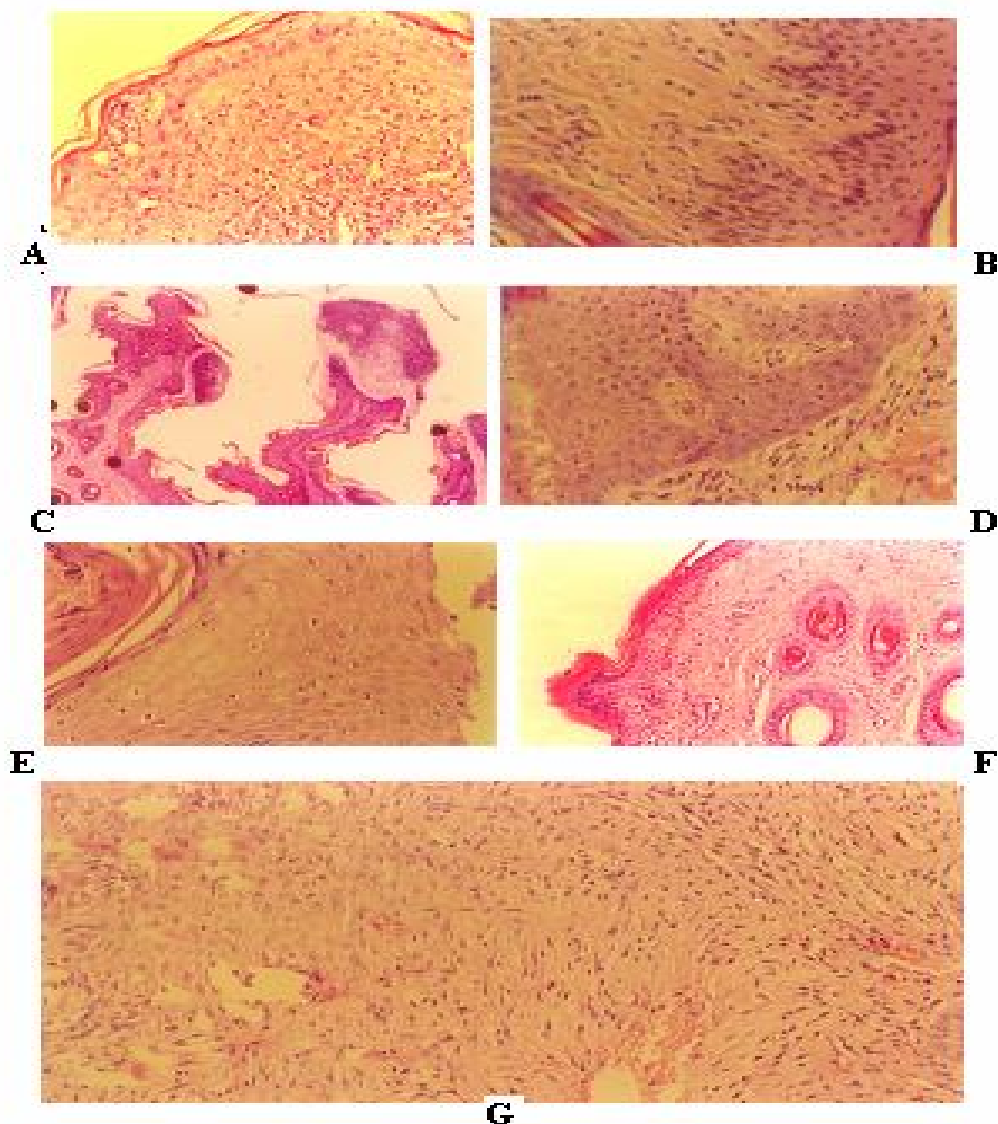


Figure 3: In low level laser therapy (LLLTT dose 1.28 J/cm²) treated full-thickness skin wounds in Nubian goat **A.** Inflammatory cells 42 hours post wounding (H&E 40x). **B.** Papillary vascularization after 18 hours post wounding (H&E 40x). **C.** Bridging by epithelial pseudopodes after 42 hours post wounding (H&E 10x). **D.** Healing by regeneration. Increase in mitotic figures and hyperaemia of the epithelial layer after 42 hour post wounding (H&E. 40x). **E.** Absence of nuclei in many cells in the stratum granulosum and prickle cells layer 336 hours post wounding (H&E 100x). **F.** Keratinization of a healed wound after 336 hours post wounding (H&E 40x). **G.** Arrangement of granulation tissue 336 hours post wounding (H&E 100x).

DISCUSSION

The aim of this study was to assess the pathological effects of different doses of (LLLTT) on the healing process of full-thickness skin wounds in goats. One of the main indications of the LLLTT is the relief of pain (Mckibben, 1983; Bromiley, 1991). It is described by Baxter *et al.* (1991) to be rated over all as effective method of pain relief for postoperative pain and considered as an important treatment objective in physio-therapist's use of low power laser.

The present study showed an effect on pain relief when LLLTT was used, it was detected since the third hour of wounding in the LLLTT treated animals. This result correlates with that of Li (1990) who demonstrates relief of pain by He- Ne laser irradiation. Pain relief in the LLLTT treated groups may be due to the altered (Walker, 1983) or decreased metabolism of serotonin induced by the laser irradiation (ZarKovic *et al.*, 1989). The suspected role of laser on the synthesis, release and metabolism of a range of neuro-chemicals has been suggested by many other authors (Iversen and

Iversen 1981; Amemiya *et al.*, 1990; Lombard *et al.*, 1990).

The occurrence for a short period of time post application of laser therapy in the treated groups in the present study is not surprising. Previous clinical studies and research reports have noted apparent increase in cutaneous and deep blood flow as a result of laser irradiation (Martine *et al.*, 1991; Singer *et al.*, 2005).

The swelling was greater in the control group which suggests the effectiveness of LLLT in reducing edema. These results agree with Zhukov *et al.* (1979) Zhou (1988) and Christensen (1989). Decreases of histamine levels and mast cell numbers after a course of irradiation with He – Ne unite were detected by Trelles *et al.* (1989).

In the present study the scab size was increased with the increase of the laser dose. The thickest scab is seen in the control group. It also sloughed leaving scar in the LLLT groups before those of the control group. The same results are described by Han and Kim (1997).

Complete wound healing, closure and contraction were seen in all LLLT treated wounds and the results of the present study were in agreement with the results of Jann *et al.* (2012). Healing was more rapid in group II which given the least LLLT dose while the slowest wound healing and closure and the minimum wound contraction is seen in the control group. It was obvious the LLLT enhanced wound healing and wound contraction that is shown in the time taken by the wounds to heal and their size. This result agrees with that observed by Hans and Kim. (1997).

The exact mechanism by which LLLT facilitates wound healing is largely unknown. However, several theories may help explain the enhanced wound contraction observed here. The studies have shown an increase in fibroblast proliferation after irradiation; Hawkins and Abrahamse (2006). Also Dyson and Young (1986) found an increase in wound contraction in irradiated ones. These data indicate that LLLT is an effective model to facilitate wound contraction of full-thickness skin wounds. The present data support this suggestion.

Epithelialization started in all LLLT treated animals earlier than in the untreated animals and continued to increase as epithelial pseudopodes (Fig 3. D) that bridging the wound area and this result is agree with that obtained by Kara *et al.* (2013). Epithelialization is found to be more rapid in group II where the pseudopodes appear and disappear earlier than in the other groups. This indicates faster leveling of the epidermis. Although epithelialization is more rapid

in group II formation of the granulation tissue and its organization is more enhanced by the highest LLLT dose tested. This indicates the difference in the effect- positive and negative- of LLLT doses in the different wound healing parameters.

The scar is observed to be of small size in the three treated groups. The small size of scar and the great resemblance of the healed skin with the normal nonwounded adjacent skin in the LLLT treated groups suggest that laser enhance healing by regeneration. This suggestion is supported by the histological results that showed greater and earlier epithelialization in group II; it is also supported by the results of wound gross examination in which the earliest healing and the smallest scar in the LLLT treated groups is seen in the same group.

Compared with the control group the granulation tissue and the newly formed collagen were denser in LLLT treated groups. These findings were also recorded by Mester and Jaszszagi-Nagy, (1973) Abergel *et al.* (1984) and Lam *et al.* (1986) Lyons *et al.* (1987) found that laser irradiation by He-Ne and Gallium Aluminum Arsenide GaAlAs laser stimulates the production of collagen by fibroblasts and this collagen producing may occur by collagen gene expression reflecting alterations in transcriptional or transitional levels. Tocco *et al.* (1985) found an increase in fibroblast proliferation using He-Ne and infrared laser, also observed an increase rough endoplasmic reticulum, suggesting stimulation of protein metabolism correlated with an increase in number and size of mitochondria in irradiated cells.

The results of this study suggested that LLLT provides better and faster wound healing. However, the dose given to group II (0.640J/cm²) can be considered as the most suitable as healing by epithelialization is better than that in the other two LLLT treated groups in which granulation tissue is formed.

The effect of LLLT on wound healing is controversial. Some researches and clinical reports indicated that LLLT had no effect on wound healing (Jongsma *et al.*, 1983; Hunter *et al.*, 1984; Kaneps *et al.*, 1984; Basford 1986; McCaughan *et al.*, 1989; Zhu and Li, 1990; Fretz and Li, 1992; Petersen *et al.*, 1999; Lucas *et al.*, 2000; Hopkins *et al.* 2004 and Kopera *et al.*, 2005) attributed the results of no effect of LLLT on wound healing to the lack of control, poor experimental designs, and inadequate specification of treatment settings or, as suggested by Calin *et al.* (2010), they may be due to different laser systems, parameters and irradiation conditions, and a great variety of treatment protocols.

The present study concluded that LLLT had a beneficial effect on healing of wounds and

recommends the use of the low LLLT dose for promotion of epithelialization.

Further studies are needed to investigate the different laser systems on wound healing.

REFERENCES

- Abergel, R.P.; Dwyer, R.M.; Meeker, C.A.; Lask, G.; Kelly, A.P. and Uitto, J. (1984):* Laser treatment of keloids a clinical trial and an *in vitro* fibroblast study with ND-YAG laser. *American Society for Laser in Medicine and Surgery*. 4:(3), 291-295.
- Amemiya, R.; Hasegawa, H. and Takeda, H. (1990):* Effects of low level laser irradiation on thermal nociception-induced amine dynamics changes in rat brain regions. *Laser Therapy*. 2:45.
- Bancroft, J.D. and Gambel, M. (1990):* Theory and Practice of Histopathology Techniques. 5th ed. Churchill Livingstone. Aninprint of Elserver Limited: China. PAgges
- Basford, J.R. (1986).* Low-energy laser treatment of pain and wounds: hype, hope or hokum?. *Myo Clinic Proceedings*. 61: (8)671-675.
- Baxter, G.D.; Bell, A.J. and Allen, J. M. (1991).* Low level laser therapy: Current clinical practice in northern Ireland. *Physiotherapy*. 77:171-178.
- Baxter, G.D.; Diamantopoulos, C.; O'kane, S.; Shields, T.D. and Allen, J. (1994):* "Therapeutic Lasers Theory and Practice" Edinburgh, 1st ed. Churchill. Livingstone.
- Braverman, B.; McCarthy, R.J.; Ivankovich, A.D.; Forded, D.E.; Overfield, M. and Bapna, M.S. (1989):* Effect of helium-neon and infrared laser irradiation on wound healing in rabbits. *Laser Surgery Medicine*. 9: 50-58.
- Brain, B.; Adriana, M.V. and Claudia, C.R. (2005):* Novel opportunites in the treatment and prevention of scarring. *Journal of Cutaneous Medicine and Surgery*, 1615.
- Bromiley, M.W. (1991):* "Physiotherapy in Veterinary Medicine". Blackwell Scientific, London.
- Calin, M.A.; Coman, T.; Calin, M.R. (2010):* The effect of low level laser therapy on surgical wound healing Romanian Reports in Physics. 2010, 62(3): 617-627.
- Christensen, P. (1989):* Clinical laser treatment of odontological Conditions. In: Kert J. Rose, L. (1989). "Clinical Laser Therapy: low level laser therapy". Scandanavian Medical Laser Technology. Copenhagen.
- Dyson, M. and Young, S. (1986):* Effect of laser therapy on wound contraction and cellularity in mice. *Laser in Medical Science* 1: 126-130.
- Fretz, P. and Li, Z. (1992):* Low energy laser irradiation treatment for second intentioned wound healing in horses. *Canadian Veterinary Journal*. 33:(10), 650-653.
- Gillette, R.L.; Swaim, A.U.; S, A.E. and Bradley, D.M. (2001):* Wound healing reconstructive surgery program. *American Journal of Veterinary Research*. 62: (7), 1149-1153.
- Han, C. and Kim, M. (1997):* The effect of low energy laser on wound healing. *Korean Journal of Veterinary Research*. 37: (3), 629-637.
- Hawkins, D. and Abrahamse, H. (2005):* Biological effect of helium-neon laser irradiation on normal and wounded human skin fibroblasts. *Photomod Laser Surgery*. 23:(3), 251-259.
- Hawkins, D. and Abrahamse, H. (2006):* Effect of multiple exposures of low-level laser therapy on the cellular responses of wounded human skin fibroblasts. *Photomod Laser Surgery*. 24:(6), 705-714.
- Hawkins, D.; Houeeld, N. and Abrahamse, H. (2005):* Low level laser therapy (LLLT) as an effective therapeutic modality for delayed wound healing. *Ann Acad Sci*. 1056: 488-493.
- Hellebrekers, L.J. and Sap, R. (1997):* Edetomidine as a premedicant for kitamine, propofal or fetanyl anaesthesia in dogs. *Veterinary Record*. 140: 545-548.
- Hopkins, T.J.; Todd, A.M.; Seegmiller, J.G. and Baxter, G.D. (2004):* Low-level laser therapy facilitates superficial wound healing in humans: A triple-blind, Sham-controlled study. *Journal Athl Train*. 39: (3), 223-229.
- Hunter, J.G.; Leonard, L.G.; Wilson, R.; Snider, G. and Dixon, J. (1984):* Effects of low-energy laser on wound healing in a porcine model. *Laser in Surgery and Medicine*. 3: 328.
- Iversen, S.D. and Iversen, L.L. (1981):* "Behavioral Pharmacology". 2nd ed. Oxford. University Press, New York.
- Jann, H.W.; Bartels, K.; Ritchy, J.W.; Payton, M. and Bennett, J.M. (2012):* Equine wound healing: influence of low level laser therapy on an equine metacarpal wound healing model. *Photon Lasers Med*. 1: 117-122.
- Jongsma, F.H.; vd Bogaard, A.E.; van Gemert, M.J. and Hulsbergen, H.J. (1983):* Is closure of open skin wounds in rats accelerated by argon laser exposure? *Laser in Surgery and Medicine*. 3: 75-80.
- Kaneps, A.; Hultgren, B.; Riebold, T. and Shires, G. (1984):* Laser therapy in the horses: Histopathologic response. *American. Journal of Veterinary Research*. 45: 3,581-582.
- Kara, C.; Demir, T. and Ozbek, E. (2013):* Evaluation of low-level laser therapy in rabbit oral mucosa after soft tissue graft application: A pilot study. *J Cosmet Laser Ther*. 2013, 5 (E pub ahead of print). www.HealingLightSeminars.com.

- Klebanov, G.I.; Shuraeva, N.; Chichuk, T.; Osipov, A.; Rundenko, T.; Shekter, A. and Vladimiro, L.U. (2005):* A comparative study of the effect of laser and light-emitting diode irradiation on the wound healing and functional activity of wound exudates leukocytes. *Biofizica*. 50: (6), 1137-1144.
- Kopera, D.; Kokol, R.; Berger, C. and Haas, J. (2005):* Does the use of low-level laser influence wound healing in chronic venous leg ulcers?. *J. Wound Care*. 14: 478-479.
- Ladalaro, T.C.; Pinheiro, A.; Campos, R.A.; Brugnera Junior, A.; Zanin, F.; Albemaz, P.L. and Weckx, L.L. (2005):* Laser therapy in the treatment of dentine hypersensitivity. *Braz Dent J*. 15: (2), 144-150.
- Lam, T.; Abergel, P. and Meeker, C. (1986):* Low-energy lasers selectivity enhance collagen synthesis. *Laser in the Life Science*. 1: 61-77.
- Li, X.H. (1990):* Laser in the department of traumatology with a report of 60 cases of soft tissue injury. *Laser Therapy*. 2: 119-122.
- Lombard, A.; Rossetti, V. and Casson, M.G. (1990):* Neurotransmitter content and enzyme activity variations in rat brain following *in vivo* He-Ne laser irradiation. *Proceedings, Round Table on Basic and Applied Research in Photobiology and Photomedicine, Bari, Italy, 10th-11th November*.
- Lucas, A.I.; Stanborough, R.W.; Freeman, C.L. and Haan, R.J. (2000):* Efficacy of low-level laser therapy on wound healing in human subjects: A Systematic Review *Lasers in Medical Science*. 15: (2), 84-93.
- Lyons, R.F.; Abergel, R.P.; White, R.A.; Dwyer, R.M.; Castel, J.C. and Uitto, J. (1987):* Biostimulation of wound healing *in vivo* by a helium neon laser. *Annals of Aplastic Surgery*. 18: (1), 47-50.
- Martin, D.M.; Baxter, G.D. and Allen, J.M. (1991):* Effect of laser pulse repetition rate upon peripheral blood flow in human volunteers. *Laser Surgery and Medicine*. 13: 83.
- McCaughan, J.S.; Bethel, B.H.; Johnston, T. and Janssen, W. (1989):* Effect of low-dose argon irradiation on rats of wound closer. *Laser in Surgery and Medicine*. 5: (6), 607-614.
- Mckibben, L.S. (1983):* An evaluation of the effects of the low-energy laser on soft tissue in horses. In: Atsumi K. (1983). *New Frontiers in Laser Medicine in Surgery*. Excerpta Medica, Amsterdam.
- Mester, E. and Jaszszagi-Nagy, E. (1973):* The effect of laser irradiation on wound healing and collagen synthesis. *Studia Biophysica*. 35: 227-230.
- Mester, A.F. and Mester, A. (1989):* Wound healing. *Laser Therapy* 1:7-15.
- Petersen, S.L.; Botes, C.; Olivier, A. and Guthrie, A. (1999):* Effect of low level laser therapy on wound healing in horses. *Equine Veterinary Journal*. 31: (3), 228-231.
- Rochkind, S.; Rousso, M.; Nissan, M.; Villarreal, M.; Barr-Near, L. and Rees, D.G. (1989):* Systemic effects of low power laser irradiation on the peripheral and central nervous system, cutaneous wounds and burns. *Laser in Surgery and Medicine*. 9: (2), 174-182.
- Scardino, M.; Swain, A.E.; Steiss, J.; Spano, J.; Hoffman, C.; Coolman, S.L. and Peppen, B. (1998):* Evaluation of treatment with a pulsed electromagnetic field on wound healing, clinicopathologic variables, and nervous system activity of dog. *American Journal of Veterinary Research*. 59: 9, 1177-1181.
- Singer, D.; Singer, A.; McClain S. and Tortora, G. (2005):* Histologic effect of laser-assisted topical anaesthesia in porcine model. *Acad Emerg. Med*. 12: 1148-1152.
- Theresa, W.F.; Cheryl, S.H.; Donald, A.H.; Ann, L.J.; Howard, B.S.; Michael, D.W. and Gwendolyn, L.C. (2002):* "Small Animal Surgery" 2nd ed. Mosby.
- Thurmon, J.C.; Tranquilli, W.J. and Benson, G.J. (1996):* "Lumb and Jones' Veterenary Anesthesia" 3rd ed. Williams and Wilkins.
- Trelles, M.A.; Mayayo, E. and Miro, L. (1989):* Bone fracture consolidates faster with low-power laser. *Lasers Surgery and Medicine*. 7: (1), 36-45.
- Vidinsky, B.; Gal, P.; Toporcer, T.; Balogacova, M.; Hutnanova, Z.; Kilik, R.; Bober, J.; Sabo, J. and Longauer, F. (2005):* Effect of laser irradiation of diode laser on healing of surgical wound in rats. *Rozhl Chir*. (2005) 84: 417-421.
- Walker, J.B. (1983):* Relief from chronic pain by low-power laser irradiation. *Neuroscience Letters*. 43: 339-344.
- Wei, Sc. and Li, Z. (1996):* Study of laser effects on wound healing pathology. *Chinese Journal of Veterinary Medicine*. 22: 4, 9-11.
- Zarkovic, N.; Maney, H.; Pericic, D.; Skala, K.; Jurin, M.; Persin, A. and Kubovic, M. (1989):* Effect of semiconductor GaAs laser irradiation on pain perception in mice. *Laser in Surgery and Medicine*. 9 (1): 63-66.
- Zhou, Y.C. (1988):* Laser acupuncture anaesthesia. Cited by Ohshiro, t.; calderhead, R.G. (1988) "Low Level Laser Therapy: A Practical Introduction" .Wiley, Chichester.
- Zhu, L. and Li, C.J. (1990):* The effect of laser irradiation on arthritis in rats. *Pain Supp*. 5: 53-85.
- Zhukov, B.N.; Zolotariova, A.I. and Musienko, S.M. (1979):* Use of laser therapy in some forms of post- thrombophleptic disease of the lower extremities. *Klinicheskaia khiurgiiia*. 7: 46- 47.

**اثر خفض النشاط الاشعاعى العلاجى (الليزر) على عملية التداوى للجروح الجلدية
فى المعز النوبية**

ماريا الريح عثمان موسى ، هند الريح عثمان موسى ، عثمان سعد على محمد

Email: hmmhmm12345@yahoo.com

هدفت هذه الدراسة إلى تقييم الآثار الأكلنيكية المرضية للجرعات المختلفة لخفض النشاط الاشعاعى العلاجى (بالليزر) على عملية التداوى للجروح الجلدية. عملت جروح الجلد الكثيف على جانب الفخذ لأثنى عشر من المعاز النوبية وقد قسّمت هذه العينة عشوائيا إلى أربع مجموعات متساوية حسب زمن المسح بالموجات المستمرة لأشعة ليزر الهليوم-النيون. وقد تم تطبيقه لفترة 0.000 جول/سم² و 0.640 جول/سم² و 1.280 جول/سم² و ٢.٠٠٠ جول/سم² لفترة ٠ و ٢٠٠ و ٤٠٠ و ٦٠٠ ثانية في اليوم ولمدة ٢١ يوم متتالية على المجموعات I و II و III و IV على التوالي. وقد أظهر مسح الأنسجة الانتهاء السريع في القطع الدقيق الأنجاذى للغشاء الظهارى والتسارع في مرحلة النضج وكذلك في حجم تقلص الجرح. كذلك توضح النتائج أن استعمال هذا النوع من الليزر قد ساعد بشكل ايجابي على إزالة الألم. وقد اتضح أن كل جرعة لخفض النشاط الاشعاعى العلاجى (بالليزر)، تؤثر على المعاملات المذكورة أعلاه لشفاء الجرح بشكل مختلف.