

DIFFERENTIAL IDENTIFICATION OF GASTEROPHILUS LARVAL SPP. IN DONKEYS BY ELECTRON MICROSCOPE

KAREMA M. EL-BAKRY and REDA S. FADLY

Animal Health Research Institute, Alexandria and Damnhour branches, Department of Parasitology.

Email: karembakry@yahoo.com , dr_redafadly@yahoo.com

ABSTRACT

Received at: 30/6/2014

Accepted: 21/8/2014

Larval-stage of the bot-fly *Gasterophilus* obtained from the stomach of Egyptian donkeys (stomach of the newly dead donkeys in Alexandria Governorate) were studied. Comparison of cuticular features, including spine distribution and shape, structure of maxillae and mandibles, cephalic sensillae and terminal abdominal segments of third instar of *Gasterophilus intestinalis*, *Gasterophilus haemorrhoidalis*, *Gasterophilus nasalis* and *Gasterophilus pecorum*. This study also focused on clarifying the fundamental differences between the second and third instars of *G. haemorrhoidalis* using scanning electron microscopy. One or more features distinguished among the species for the first time in Egypt. *Gasterophiline* larvae are of veterinary and medical importance with some human creeping cutaneous myiasis, ophthalmomyiasis and one recent record of intestinal myiasis.

Key words: Donkeys, larvae, morphology, stomach bots.

INTRODUCTION

Larvae of flies belonging to the genus *Gasterophilus* (Diptera:Oestridae) are parasites of equids (including horses, donkeys and zebras) throughout the world. Their impact on the host is generally limited, although large numbers are associated with carelessness and the majority of working and pleasure horses in north America and northern Europe are treated regularly as part of parasite control programmes (Lloyd *et al.*, 2000 and Klei *et al.*, 2001). Third instar *Gasterophilus* spp. attach to the mucosa of various regions of the equid gastro-intestinal tract. Species-specific sites are well established (Zumt, 1965; Coles and Pearson 2000; Smith *et al.*, 2005). Larvae use the robust mouth hooks (maxillae) for attachment and apparently use the flat mandibles to abrade host tissues as sources of nutrient. The robust spines that are distributed on the thoracic and anterior abdominal segments also aid the larvae in maintaining their position within the gut. Morphologic variations associated with different sites of attachment have not been noted despite differences in mucosal architecture and in the features of lesions *Gasterophilus* larvae may induce (Principato, 1988).

The common host of this particular species of bot fly is the horse. Other equid species, including mules and

donkeys, can also serve as hosts. Although accidental, the horse bot also has been reported in man causing either ocular (eye) or cutaneous (skin) myiasis.

As the second and third instar larvae inhabit the gastrointestinal tract and attach to the stomach and intestine, multiple complications may arise. Larvae present in large numbers in the stomach can cause blockages and lead to colic. Horses are capable of tolerating an infestation of 100 larvae. Large numbers of larvae impact the host by damaging the tissue of the stomach or the gut lining and consuming the nutrients that would otherwise be beneficial to the hosts' well-being. Other health issues that may develop due to a severe infestation of these larvae include: chronic gastritis, ulcerated stomach, esophageal paralysis, peritonitis, stomach rupture, squamous cell tumors, and anemia (Williams and Knapp 1999).

The horse bot fly occasionally can cause what is called ocular myiasis, or invasion of the eye by first stage larvae in human. Although these cases are rare, they often occur in individuals handling horses that have bot fly eggs on their hair. An additional rare form of horse bot myiasis is called cutaneous myiasis. In this case, hatching larvae enter the skin of humans and begin burrowing through the skin causing visible, sinuous, inflamed tracks accompanied by

considerable irritation and itching (Catts and Mullen 2002).

These larvae use their anterior spines and mouth hooks to attach to the wall of the gastrointestinal tract. Generally, gasterophilosis is characterized by difficulties in swallowing (throat localization of the immature stages), gastro and intestinal ulcerations, gut obstructions or volvulus, rectal prolapses, anaemia, diarrhoea and digestive disorders (Principato 1988 and Cogley, 1999). The clinical signs associated with the migration and maturation stages of the larvae are difficult to diagnose, but it has been shown that different species of *Gasterophilus* can cause severe damages during their life cycle (Shefstad, 1978 and Cogley, 1989). They also have some zoonotic potential as they are occasionally reported to affect humans, where they are found subcutaneously or in the digestive tract (Zumt, 1965; Royce *et al.*, 1999 and Anderson 2006). There is a paucity of reports on the biology, host – parasite interactions and morphology of the species in this genus, which is an intriguing model of biodiversity (Otranto *et al.*, 2005) and which may increase our understanding of adaptations to parasitism. Third instars are the life cycle stage most commonly retrieved by veterinary practitioners at necropsy or in the faeces of hosts. Previous studies have relied on light microscopy (Principato, 1986, 1987, 1989) or have used a comparative approach primarily limited to the most commonly recovered species (*G. intestinalis* De Geer, *G. nasalis* L.) (Erzinclioglu, 1990; Cogley, 1999 and Leite *et al.*, 1999). Moreover, serious ophthalmomyiasis caused by first instars *Gasterophilus* species was also recorded in a woman grooming horses and a farm manager Cogley (1999) described a previously unknown sensory array in the distal mouth hooks of *Gasterophilus* species by the use of scanning electron microscope (SEM) and considered the design of 3rd stage *Gasterophilus intestinalis* sensory array as a model for comparison to other species. This array was entirely overlooked by Erzinclioglu (1990) in his SEM studies on *Gasterophilus* larvae. All Egyptian studies were concerned with biological and morphological characters. According to the available literatures no electron microscopic studies have been done before on *Gasterophilus* larvae (horse bots) in Egypt.

So the aim of this work is focused on highlighting the role of the electron microscope and clarify the exact details of the four different spp. Of *Gasterophilus* larvae infesting equine, comparison of cuticular features, compared too their studies also height lighting on sensory array (especially sensory array on the mouth hooks and explain its function).

MATERIALS and METHODS

Study area:

This study was carried out in the period from October 2013 until April 2014 and relied on the examination of the stomach of the newly dead donkeys in Alexandria Governorate.

Parasite collection and preservation:

The stomach was opened along the greater curvature from the cardiac orifice to the pylorus. *Gasterophilus* spp. larvae were collected from different portion of the stomach. Stomach was examined in detail to determine the infected part with *Gasterophilus* larvae. Larvae recovered from host gastro-intestinal tracts (gastric region and curvature of the cardiac orifice to the pylorus) were rinsed in saline prior to preservation in 95% ethanol. Species identification was based on location within the gastro-intestinal tract and on morphological features as presented in Zumt (1965). Each specimen was cross-sectioned at the third abdominal segment and the internal organs removed. and fixed by immersing them immediately in formaline glutardhyde (4F 1G) in phosphate buffer solution (PH 7.2) at 4°C for 3 hours Specimens were then post fixed in 2% osmic acid (OsO₄) in the same buffer at 4°C for 2hours. Samples were washed in the buffer and dehydrated at 4°C in an ascending series of ethanol, transferred to acetone and critical point dried using liquid carbon paste on an Al-stub and coated with gold up to a thickness of 400 Å in a sputter – coating unit (JFC-1100 E). Images were acquired digitally using a Jeol JSM-5300 scanning electron microscope operated at 25-30KeV In Electron Microscope Unit, Faculty of Science, Alexandria University according to Rufz-Martinez *et al.* (1989).

RESULTS

Larval-stage of the bot-fly *Gasterophilus* obtained from the stomach of Egyptian donkeys were studied. Comparison of cuticular features, including spine distribution, shape, structure of maxillae, mandibles, cephalic sensillae and terminal abdominal segments of third instar of *Gasterophilus*, *intestinalis*, *Gasterophilus haemorrhoidalis*, *Gasterophilus nasalis* and *Gasterophilus pecorum* This study also focused on clarifying the fundamental differences between second and third instars of *G. haemorrhoidalis* using scanning electron microscopy. According to the available literatures one or more features distinguished among the species for the first time in Egypt. The results has been illustrated in figures and tables.

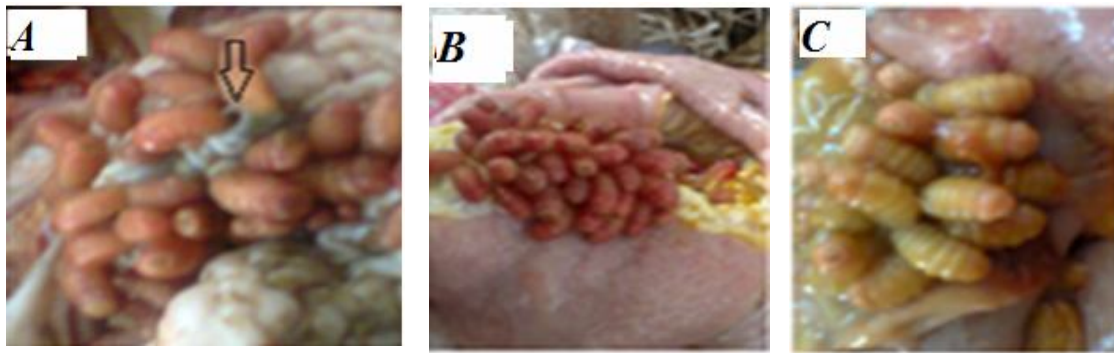

Fig. 1: *Gasterophilus* larvae (A) in the gastric region crater-like' lesions (A) (arrow). B&C in the curvature of the cardiac orifice to the pylorus

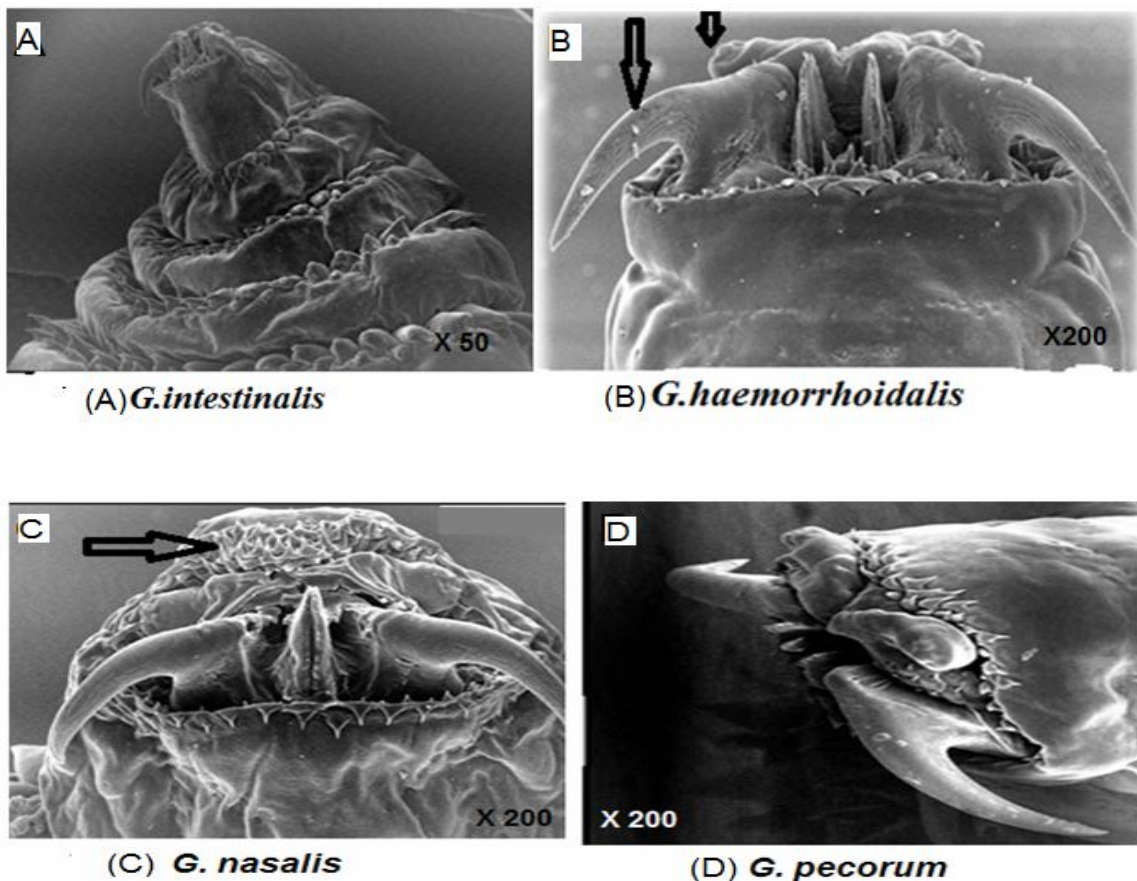


Fig. 2: Scanning electron micrographs of the cephalic segments of third instar *Gasterophilus* spp showing Cephalic segment of a third instar of *Gasterophilus larva* showing the maxilla relative to the larval body (*G.intestinalis*, *G.haemorrhoidalis*, *G. nasalis* and *G. pecorum*) laterally directed maxillae and medially approximated mandibles, also shows antennomaxillary complex formed of symmetrically similar comonents (arrows). Only *G.nasalis* have the first thoracic segment extended in a shelf like manner over the cephalic segment (arrow).

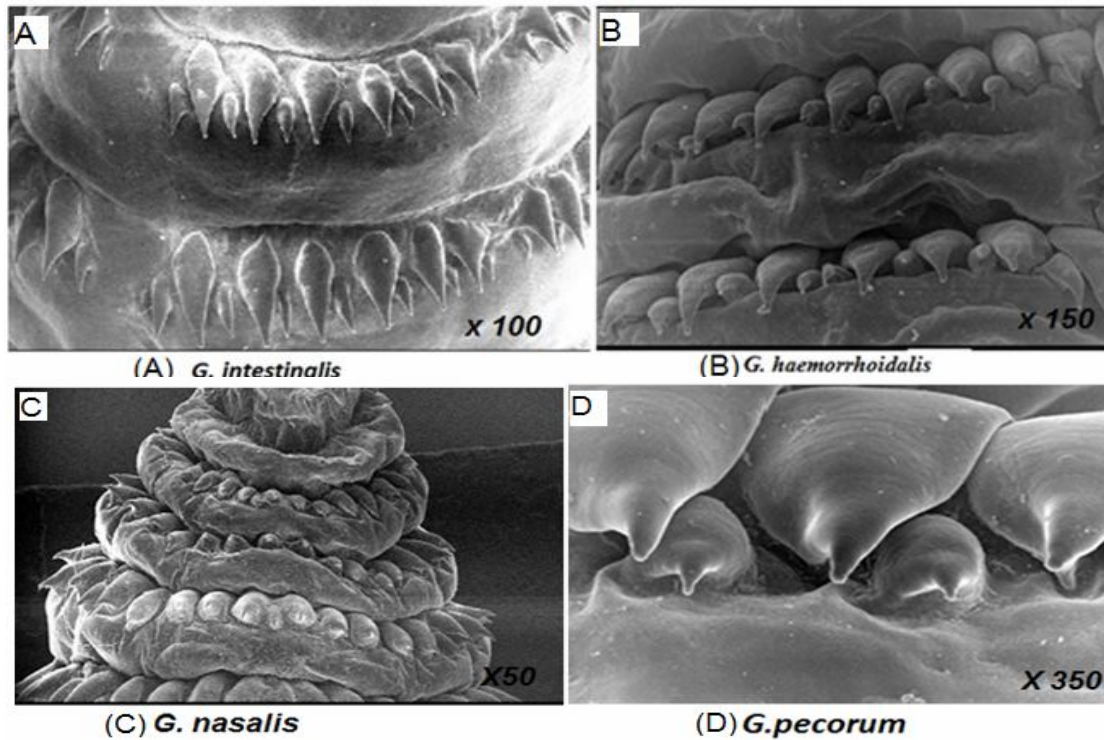


Fig. 3: Scanning electron micrographs of the dorsal surface of thoracic and abdominal segments. Illustrates the pattern of spination of the thoracic and anterior abdominal segments in between the segments, there are two rows of unequal spines with their sharp termination in (*G.intestinalis*, *G.haemorrhoidalis* and *G. pecorum*) Only *G.nasalis* have one rows of spines.

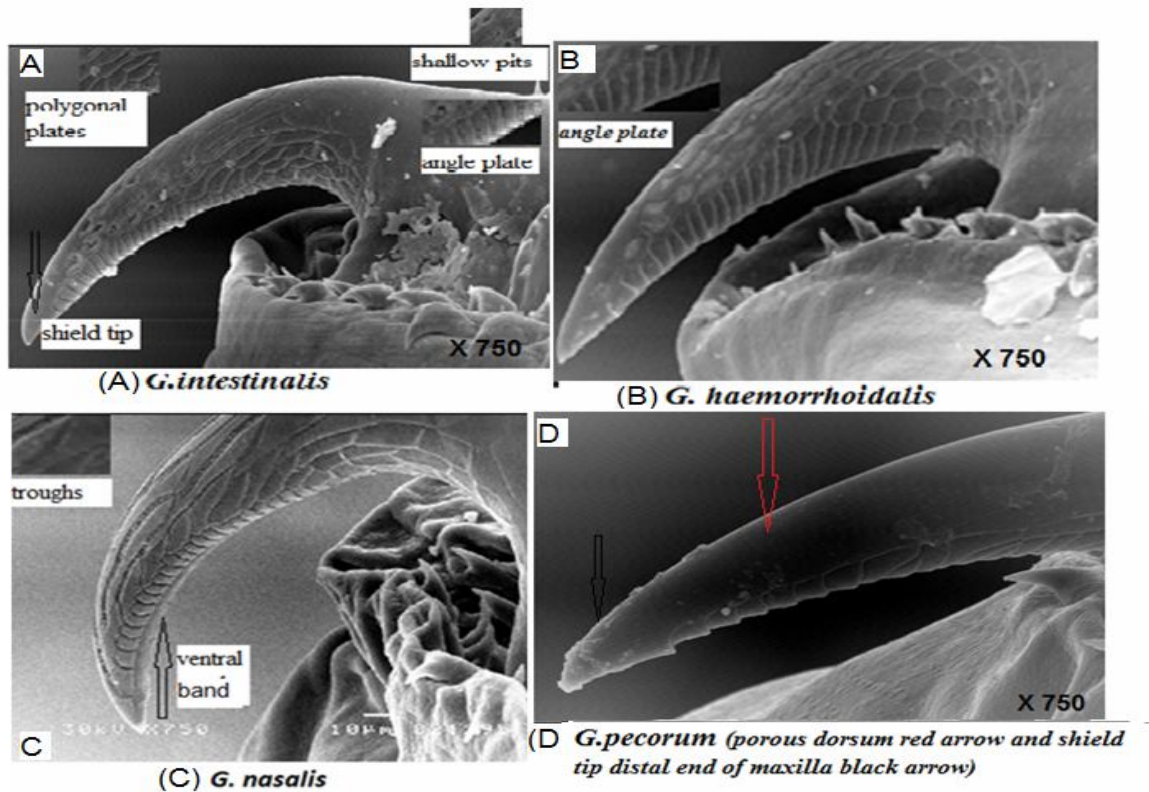


Fig. 4: Scanning electron micrographs of the maxillae (mouthhooks) of third instar *Gasterophilus* the mouth hook of 3rd stage *Gasterophilus* larvae *G.intestinalis* larvae showing polygonal plates, shallow pits, angled plates and shield tip also same character in *G. haemorrhoidalis* *G.nasalis* larvae illustrating troughs that contain sensilla and ventral band that separates the two rows of angled plates from each other. *G.pecorum* larvae illustrating porous dorsum and shield tip distal end of maxilla

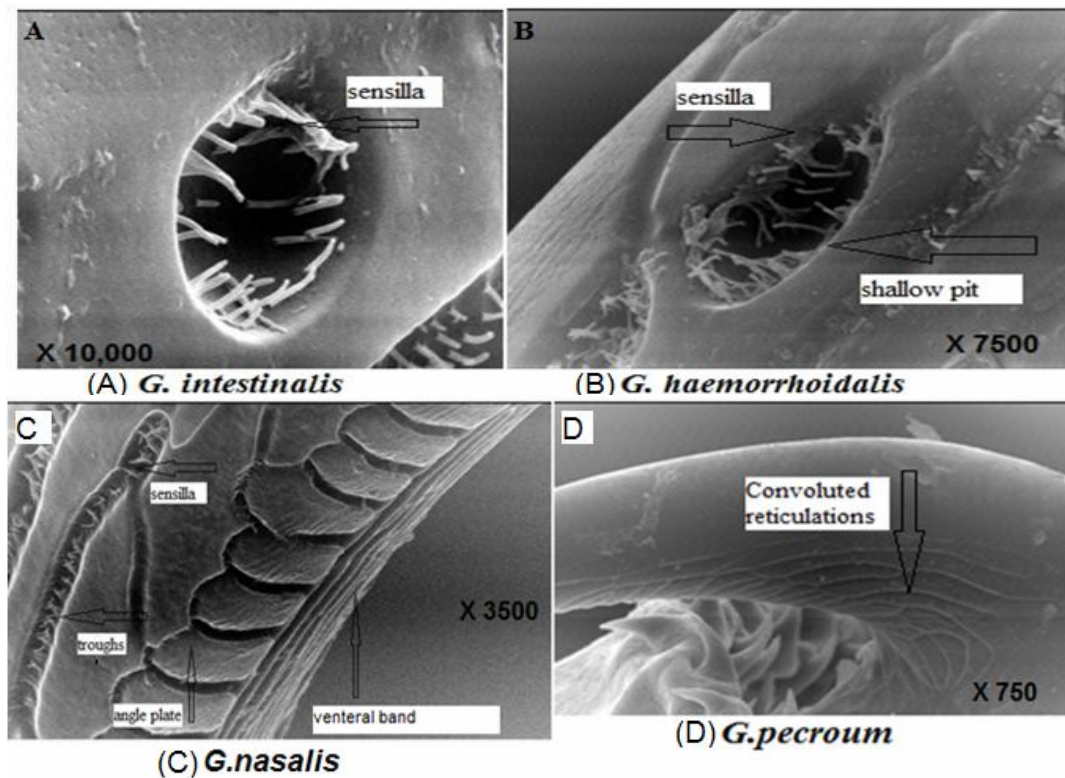


Fig. 5: Scanning electron micrographs of the maxillae ultrastructure of third instar *Gasterophilus* spp close- up view of shallow pit on 3rd stage *Gastrophilus intestinalis* demonstrating the peg –like sensilla close- up view of shallow pit on 3rd stage *Gastrophilus haemorrhoidalis* filled with sensilla, *G.nasalis* larvae illustrating troughs that contain sensilla also demonstrating ventral band that separates the two rows of angled plates from each other *G.pecorum* larvae illustrating Convoluted reticulations.

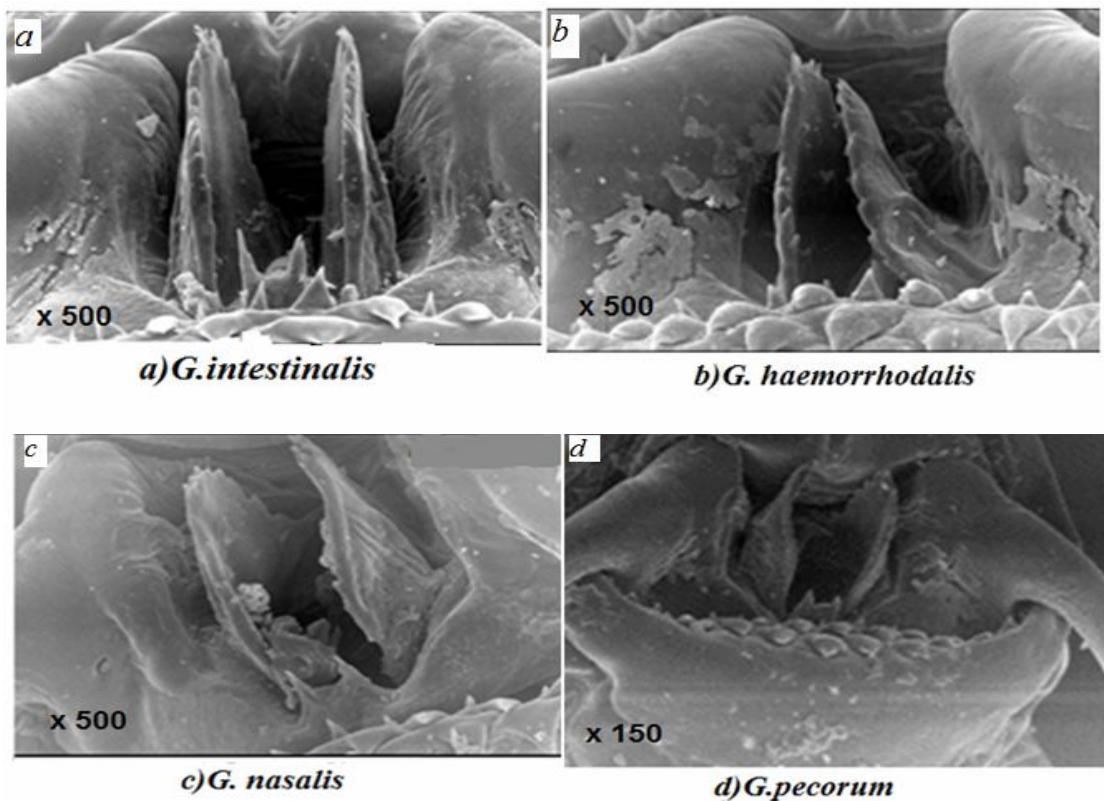


Fig. 6: Scanning electron micrographs of the mandibles of the third instar *Gasterophilus* spp. larva the dorsal portion of each mandible is extended into serrated lobe except in *G. pecorum* and *G.nasalis*.

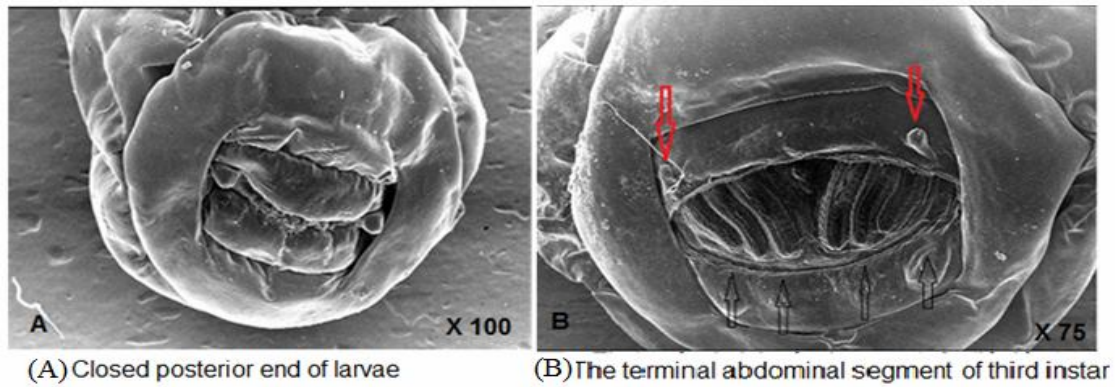


Fig. 7: Shows terminal abdominal segments of third instar *Gastrophilus* larva in **fig A** closed posterior end showing spiracular pouch in **fig B** opened terminal abdominal segment showing two lobes bearing sensilla (red arrows), four individual sensilla (black arrows) and three slit like openings.

Second-Instar Larva

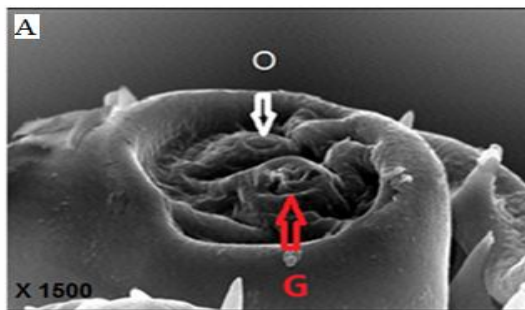
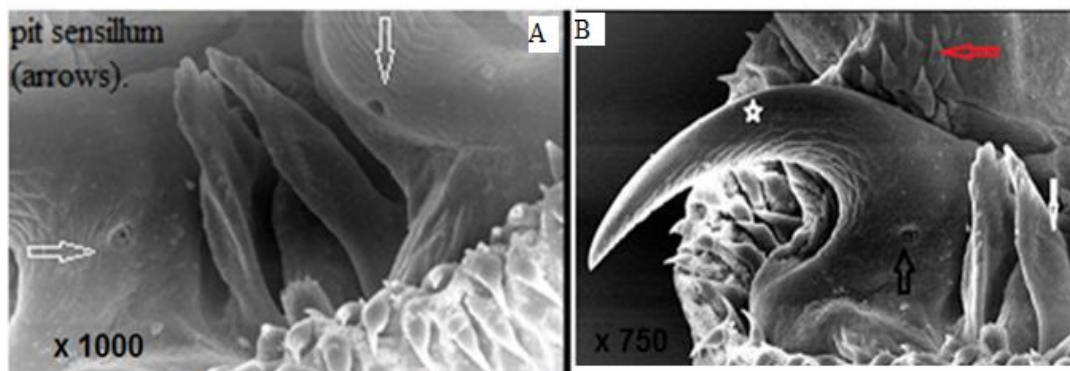


Fig (8) an antennal lobe on the cephalic segment of a third instar *G. intestinalis* showing the cuticular sensilla. G, gustatory sensory cluster; O, olfactory sensillum.

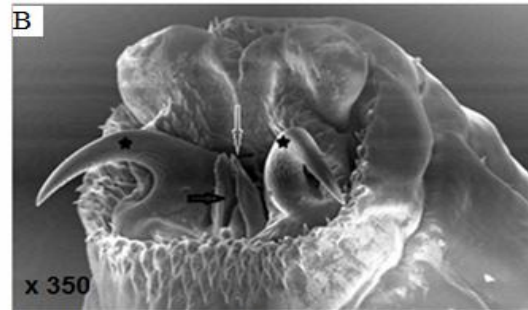

Fig (9) Frontal view showing -maxilla (star), oral opening (white arrow), mandible (black arrow) of *G. haemorrhoidalis* second-instar larva

Different structures in second-instar larva differ from the third-instar larva of *G. haemorrhoidalis*



Fig(10) (A) maxilla showing the pit sensillum (arrows). (B) Dorsal preoral spines (red arrow), maxilla (star), mandible (white arrow),

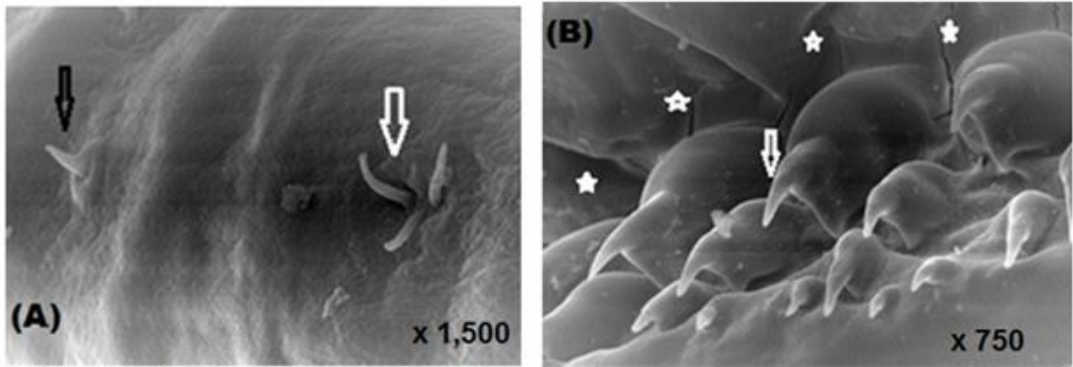


Fig (11) Trichoid sensilla with three (white arrow) and one (black arrow) setae of the first thoracic segment in ventral view.

(B) Ill developed anterior spines (arrow) and cuticular depressions in lateral view(stars).

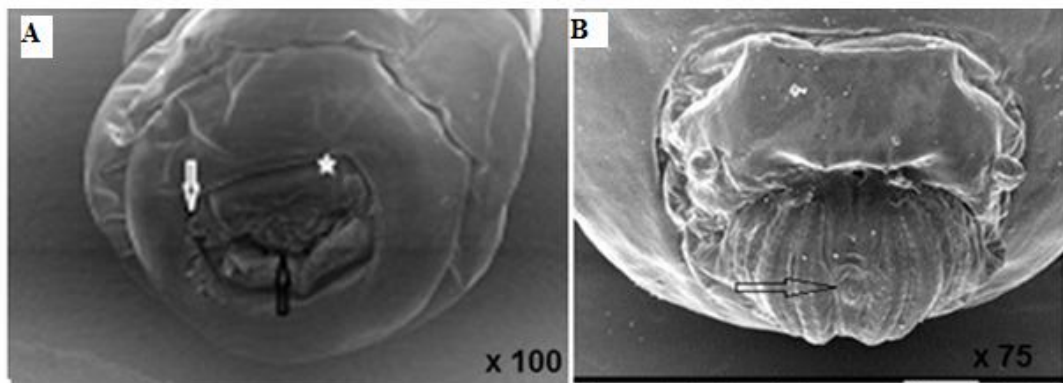


Fig (12) Terminal view of the abdominal segment showing the sensilla

(A) (white arrow), lateral tubercle (star) and spiracular cavity (black arrow)

The terminal abdominal segments of second instar

(B) probable. ecdysial scar arrow

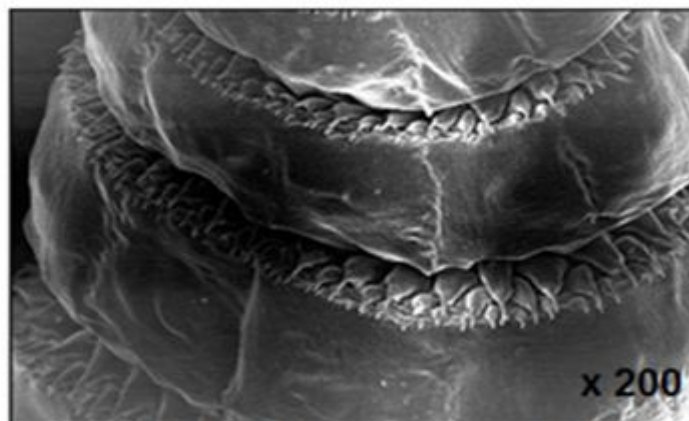

Fig (13) second-instar larva of *G. haemorrhoidalis* showing 3 rows of spines per segment

Table 1: Comparative summary of various features on third instars of *Gasterophilus spp.*

Species	Thoracic ‘ shelf	Dorsal spines		Terminal abdominal Sensillae Fig 7)
		Shape	Configuration	
<i>G. intestinalis</i>	Absent	Inverted drop with sharply pointed ends	Two rows	Present
<i>G. haemorrhoidalis</i>	Absent	Inverted drop with sharply pointed ends	Two rows	Present
<i>G. nasalis</i>	Present Fig (2)	Broad-based ended with sharp end	Single row Fig (3)	Present
<i>G. pecorum</i>	Absent	Broad-based, with shoulder and rapid taper to sharp terminus	Two rows	Present

Table 2: Comparison of the surface ultrastructure of third instar maxillae from four species of *Gasterophilus*

Species	shape	Maxillary surface		
		Anterior	Dorsal and ventral	Posterior
<i>G. intestinalis</i>	uniformly bent dorsally	Smooth	Ovoid pits lined with cuticular pile Fig (5)	Regularly spaced, linear ridges extending from near the base to a short distance from the tip
<i>G. haemorrhoidalis</i>	saddle like excision	Smooth	Ovoid pits lined with cuticular pile	Regularly spaced, linear ridges extending from near the base to a short distance from the tip
<i>G. nasalis</i>	sharply pointed and ventrally curved	Smooth	Few shallow reticulations and 1 – 2 deep longitudinal pits (troughs) lined with cuticular pile Fig (5)	Light, chevron-like ridges extending from dorsal to ventral surfaces
<i>G. pecorum</i>	Maxilla more laterally denticles on the Pseudocephalon between the mouth hooks and antennal lobes arranged in semi circular.	Smooth,	Convolute reticulations that extend onto the posterior surface	Distal portion with regularly spaced, linear ridges extending from dorsal to ventral surfaces

Table 3: Comparison between the ultrastructure of second and third instar of *Gasterophilus haemorrhoidalis*

	Second larvae	Third larvae
<u>Maxilla sensory array:</u>	Each maxilla is sharply pointed and ventrally curved	maxilla is sharply pointed and ventrally curved
Shallow pit	Absent	Present
Peg like sensilla	Absent	Present
Ventral band	Absent	Present
<u>Mandibles</u>	The mandibles have few projections on the stem and many apical sharpened projections (Fig10)	The dorsal portion of each mandible is extended into a serrated lobe (Fig 6)
<u>spines</u>	3 rows of spines per segment The spines of the first row are two times longer than those of the third. Fig (13)	2 rows of spines per segment Fig (3)
<u>spiracular plate</u>	spiracular plate has two slightly curved slits Fig(12)	spiracular plate has three slightly curved slits Fig(7 B)

DISCUSSION

Larval-stage of the bot-fly *Gasterophilus* obtained from the stomach of Egyptian equines were studied. The study included comparison of cuticular features, spine distribution and shape, structure of maxillae and mandibles, cephalic sensillae and terminal abdominal segments of third instar of *Gasterophilus*, *intestinalis*, *Gasterophilus haemorrhoidalis*, *Gasterophilus nasalis* and *Gasterophilu specorum*. This study also focused on clarifying the fundamental differences between the second and third instars of *G. haemorrhoidalis* was conducted using scanning electron microscopy. One or more features distinguished among the species for the first time in Egypt according to the available literatures. As in previous papers (Leite, 1988; Leite and Williams, 1989, 1997; Filippis and Leite 1997), this report showed the external morphology of larval bot fly of veterinary importance. Although nine adult species of the genus *Gasterophilus* are known (Zumt, 1965), few SEM studies have been made of the immature stages. The larvae use their anterior spines and mouth hooks to attach to the wall of the gastrointestinal tract and ultimately form ulcers but with rare reports of perforation (Principato, 1988). This study has demonstrated several surface ultra structural features on third instars of four species of *Gasterophilus* that allow separation of them. These are in addition to the features presented in Zumt (1965). However, the features presented by Zumt (1965) are in complete and rely primarily on the distribution of spines and locality within the host. The differences in structural features of these larvae are not clearly associated with

differences in the epithelial architecture at the site of attachment. Principato, (1988) described the gross features of gastric and intestinal lesions in horses. The lesion morphology is not strongly associated with the species of larva present, whereas the location of the larvae within the gastrointestinal tract tends to be more diagnostic. Fig (1) Revealed that both *G. intestinalis* and *G. pecorum* are found in the gastric region and produce very similar Crater-like ulcerative lesions on the donkey stomach mucosal membrane this result was in agreement with that reported by (Maria *et al.*, 2009) and Nalan *et al.* (2010). Fig (2) Concerning Cephalic segment Zumt (1965) described the presence of 'denticles' between the cephalic lobes and lateral to the maxillae as characteristic of *G. pecorum*. In the current study the spines ventral to the cephalic lobes appear to be those referred to by Zumt (1965) and shown in Smith *et al.*, (2005). Although they were present in all species. The presence of both central cluster between the cephalic lobes, and the two lateral clusters is diagnostic for *G. pecorum*. SEM revealed that The shelf-like protrusion of the first thoracic segment of *G. nasalis* unique among this group this result was in agreement with that reported by Colwell *et al.*, (2007) and this may represent an adaptation to the local environment (e.g. gut motility). Fig(3) Scanning electron micrographs of the dorsal surface of thoracic and abdominal segments illustrates the pattern of spination of the thoracic and anterior abdominal segments. in between the segments, there are two rows of unequal spines with their sharp termination in (*G.intestinalis*, *G.haemorrhoidalis* and *G. pecorum*) Only *G.nasalis* have one rows of spines these results in agreement with that reported by Colwell *et al.*

(2007) while Zumpt (1965) described the structure of spines, as diagnostic features, for only two of the four species under consideration in this study (However, he revealed the differences between *G. haemorrhoidalis* and *G. intestinalis*, which are not evident in this study. Unlike our study which focused on detailed surface features in the differentiation, Zumpt (1965) and Principato, (1987) show general differences in the curvature and base structure of the species examined in the current study, but had not detailed the surface features. Both authors showed differences among *G. haemorrhoidalis* and *G. intestinalis*, although the differences reported by Principato (1987) appear to be related primarily to larval size. Fig (4, 5) SEM concerning the maxillae (mouth hooks) the present study demonstrate that the morphological features of *G. haemorrhoidalis* and *G. intestinalis* don't show substantial differences except the shape of sensillum of sensory arrays which are peg like in *G. Intestinalis* while ostrich- neck and head-shaped in *G. haemorrhoidalis* this result was in agreement with that reported by Khalifa *et al.* (2005) as well as the number of angled plates which are 23 in *G. intestinalis* while nearly 21 in *G. haemorrhoidalis*, but using the number of the angled plates has limitations if the angled plates in one specimen are very different in width compared to another specimen, these results were in agreement with that reported by (cogley, 1999). Still there are some issues related to differences in the biology of these two species (Colwell, 2005). SEM can clearly differentiate *G. nasalis* from the other types through the ovoid shallow pits which are replaced by troughs on the mouth hook this result was similar to that reported by (cogley, 1999) and (Leite *et al.*, 1999). Finally SEM can differentiate *G. pecorum* through the convoluted reticulations that extend onto the posterior surface of the maxillae this result was in agreement with that reported by Colwell *et al.* (2007). However Leite *et al.*, (1993) stated that mouth hooks and mandibles of dipterous larvae were rather featureless. Fig (6) Concerning mandibles SEM described large, well developed mandibles the dorsal portion of each mandible is extend into serrated lobe as in *G. intestinalis* and *G. haemorrhoidalis* while *G. pecorum* and *G. nasalis* the lobe of the mandible is intermediate between the previous two species, variation in mandible shape reported in this study is similar to that shown by Principato (1986) and Colwell *et al.* (2007). This suggests that there may be greater structural variation within the same species, which requires further study. Zumpt (1965) described the presence of 'warts' on the terminal abdominal segment, near the respiratory cavity, of several species. Fig(7) SEM in Present study has clarified the nature of features such as the 'warts' on the rim of the respiratory cavity, which clearly bear groups of sensillae. This study illustrated several fine structures on the posterior spiracles that could be used to identify these obligatory dipterous bots. As reported

by Fahmy (1991), Principato (1988), Gannetto *et al.* (1999) and Guitton *et al.* (1996), the architecture of these posterior spiracles were morphologically similar to any other dipterous larvae. It located in a hallow depressed cuticle at the last posterior end of the larval body forming a dorsal and ventral lips jointed to each other enclosing a pair of spiracular plate inside. These cuticular lips were considered the first block barrier that prevented the adverse environmental condition such as inflammatory exudates in case of rhinitis or high flow of cold air during breathing especially in racing horses. These unfavorable condition lead the larvae to close the spiracles by the mobile lips. This adaptation of protection mechanism was similar to interpretation reported by Principato *et al.* (1988) for *Gasterophilus* larvae. Fig (8) an antenal lobe on a cephalic segment of a third instar *G.intestinalis* showing the cuticular sensilla olfactory and gustatory sensillae with in agreement with Cogley, (1999) who think that structural elements among the pile represent sensillae. These sensillae would supposedly convey in formation used in site selection. Additionally, the cephalic sensillae are probably pressed close to the host tissue, with both olfactory and gustatory sensillae they would convey much information to the larvae. Table(3) Explainingin Fig (9,10,11,12) Comparing between ultra structure of second and third instar of *Gasterophilus haemorrhoidalis*, our results showed that the mouth hooks of second stage of *Gasterophilus haemorrhoidalis* are strikingly absence of sensilla on polygonal plates. Close inspection by SEM revealed the absence of (shallow pit, peg like sensilla and ventral band) which are found in the third stage *Gasterophilus haemorrhoidalis* our results agreed with Cogley, (1999) who study sensory array on the mouth hooks of *Gasterophilus* larvae. Concerning the mandibles, the apical sharpened projections are more prominent in the second stage *Gasterophilus haemorrhoidalis* than the third stage (Leite and Scott 1999). Fig(13) Our results also revealed presence of three rows of spines per segment the first row of spines approximately twice as long as those of third row this results agreed with Zumpt (1965).

RECOMMENDATION

Anyone working with horses during bot fly season should be familiar with the risks and take appropriate precautions (do not rub eyes after combing or washing animals and wash hands when finished). **Mechanical control.** Feces should be cleaned and transported away since this is the area where the final development occurs before the fly emerges. **Chemical control.** An insecticide can also be applied weekly during the peak egg laying season to the areas of the body covered with bot eggs. Oral medications can be used to reduce the numbers of larvae inside of the stomach.

REFERENCES

- Anderson, J.R. (2006): Oestrid myiasis of humans. The *Oestrid* Flies: Biology, Host – Parasite Relationships, Impact and Management (ed. by D.D. Colwell, M.J.R. Hall & P.J. Scholl), pp. 201–209. CAB International, Oxford, U.K.
- Catts, E.P. and Mullen, G. (2002): Myiasis (Muscoidea, Oestroidea). 318–347 pp. In Mullen G, Durden L. (editors). Medical and Veterinary Entomology. San Diego, CA. Academic Press.
- Cogley, T.P. (1999): Morphology of a newly discovered sensory array on the mouth hooks of *Gasterophilus* larvae. *Medical and Veterinary Entomology*, 13, 439–446.
- Cogley, T.P. (1989): Effects of migrating *Gasterophilus intestinalis* larvae (Diptera: Gasterophilidae) on the mouth of the horse. *Vet. Parasitol.* 31: 317–331.
- Coles, G.C. and Pearson, G.R. (2000): *Gasterophilus nasalis* infection: prevalence and pathological changes in equids in south-west England. *Veterinary Record*, 146, 222–223.
- Colwell, D.D. (2005): Life cycle strategies. The *Oestrid* Flies: Biology, Host–Parasite Relationships, Impact and Management (ed. by D.D. Colwell, M.J.R. Hall & P.J. Scholl), pp. 67–77. CAB International, Oxford, U.K.
- Colwell, D.D.; Otranto, D. and Horak, I.G. (2007): Comparative scanning electron microscopy of *Gasterophilus* third instars. *Medical and Veterinary Entomology* 21: 255–264.
- Erzinclioglu, Y.Z. (1990): The means of attachment of the larvae of horse, zebra and rhinoceros bot-flies (Diptera: Gasterophilidae). *Medical and Veterinary Entomology*, 4, 57–59.
- Fahmy, M.M. (1991): Scanning electron microscopy on the third larval stage of *Cephalopinatitillator* fly (Diptera: Oestridae). *J. Drug Res. Egypt*, 20: 65–73.
- Filippis, T. and Leite, A.C.R. (1997): Scanning electron microscopy studies on the first-instar larva of *Dermatobia hominis*. *Medical and Veterinary Entomology*, 11, 165–171.
- Gannetto, S. Santoro, V. and Pampiglione, S. (1999): Scanning electron microscopy of *Oestrus ovis* larvae (Diptera: Oestridae): Skin armour and posterior spiracles. *Parasite*, 6: 73–77.
- Guittou, C. Dorchie, P. and Morand, S. (1996): Scanning electron microscopy of larval instars and imago of *Rhinoestrus usbekistanicus* Gan. 1947 (Oestridae). *Parasite*, 3: 155–159.
- Hanson, P. (2001): Re-evaluation of ivermectin efficacy against equine gastrointestinal parasites. *Veterinary Parasitology*, 98, 315–320.
- Khalifa, R.M.; Manal, Z.M. Abdel Latif and Raafat T. Mohamed (2005): Scanning electron microscopical study of third instar of *Gasterophilus haemorrhoidalis* (Diptera: Gasterophilidae). *El-Minia Med., Bull.*, 16, (1)1–19.
- Klei, T.R.; Rehbein, S.; Visser, M.; Langhoff, W.K.; Chapman, M.R.; French, D.D. and Hanson, P. (2001): Re-evaluation of ivermectin efficacy against equine gastrointestinal parasites. *Veterinary Parasitology*, 98, 315–320.
- Leite, A.C.R. (1988): Scanning electron microscopy of the egg and the first instar larva of *Dermatobia hominis* (Diptera: Cuterebridae). *MemoÁrias do Instituto Oswaldo Cruz*, 83, 253–257.
- Leite, A.C.R.; Scott, F.B. and Evangelista, L.G. (1999): Scanning electron microscope observations on third instar *Gasterophilus nasalis* (Diptera: Oestridae). *Journal of Medical Entomology*, 36, 643–648.
- Leite, A.C.R. and Scott, F.B. (1999): Scanning electron microscope observations on second-instar *Gasterophilus nasalis*. *Journal of Medical Entomology*, 13, 288–294.
- Leite, A.C.R. and Williams, P. (1989): Morphological observations on the egg and first instar larva of *Metacuterebraapicalis* (Diptera: Cuterebridae). *MemoÁrias do Instituto Oswaldo Cruz*, 84, 123–130.
- Leite, A.C.R. and Williams, P. (1997): External morphology of the immature stages of *Metacuterebraapicalis*. *MemoÁrias do Instituto Oswaldo Cruz*, 92, 775–783.
- Lloyd, S.; Smith, J.; Connan, R.M.; Hatcher, M.A.; Hedges, T.R.; Humphrey, D.J. and Jones, A.C. (2000): Parasite control methods used by horse owners: factors predisposing to the development of anthelmintic resistance in nematodes. *Veterinary Record*, 146, 487–492.
- Maria, B. and Katarzyna, W. (2009): *Gasterophilus* SP. bot fly larvae in horses from the South-Eastern part of Poland *Bull Vet Inst Pulawy* 53, 651–655.
- Nalan, Ö.; Kamile, B.; Özlem, O. and Serdar, D. (2010): Presence of *Gasterophilus* Species in Horses in Van Region Veteriner Fakültesi Dergisi, 21 (2), 87–90.
- Otranto, D.; Milillo, P.; Capelli, G. and Colwell, D.D. (2005): Species composition of *Gasterophilus* spp. (Diptera, Oestridae) causing equine gastric myiasis in southern Italy: parasite biodiversity and risks for extinction. *Veterinary Parasitology*, 133, 111–118.
- Principato, M. (1986): A study on the maxillae of third instar larvae of the six Italian *Gasterophilus* species (Diptera: Gasterophilidae): observations on their taxonomic significance in the identification to the species. *Bulletin de la Societe Francaise de Parasitologie*, 1, 121–130.

- Principato, M. (1987):* Etude comparative de l'armature cephalo-pharyngee des troisiemesstadeslarvaires des especesitaliennes de *Gasterophilus* (Diptera: *Gasterophilidae*). Techniques de preparation et observationssurleur role morpho-fonctionnel enpathologie. Bulletin de la Societefrancaise de parasitology, 5. 261-267.
- Principato, M. (1988):* Classification of the main macroscopic lesions produced by larvae of *Gasterophilus* spp. (Diptera: *Gasterophilidae*) in free-ranging horses in Umbria. Cornell. Veterinarian, 78, 43-52.
- Principato, M. (1989):* Observations on the morphological variability of the third instar larvae of *Gasterophilus nasalis* (Diptera: *Gasterophilidae*). Bulletin de la Societe Francaise de Parasitologie, 7, 93-97.
- Principato, M. and Tosti, M. (1988):* Scanning electron microscope observation on the anterior thoracic and post -abdominal spiracles of *Gasterophilus* larvae (Diptera *Gastrophilidae*). Int J. Parasitol., 18: 191-196.
- Royce, L.A.; Rossignol, P.A.; Kubitz, M.L. and Burton, F.R. (1999):* Recovery of a second instar *Gasterophilus* larva in a human infant: a case report. American Journal of Tropical Medicine and Hygiene, 60, 403-404.
- Rufz Martinez, I.; Soler-Cruz, M.D.I.; Bentiz-Rodriguez, R. and Perez, J.M. (1989):* Preparation of dipteran larvae for scanning electron microscopy. Scan. Microsc., 3(1): 287-390.
- Shelfstad, D.K. (1978):* Scanning electron microscopy of *Gasterophilus intestinalis* lesions of the equine stomach. J. Am. Vet. Med. Assoc. 172: 310-313.
- Smith, M.A.; McGarry, J.W.; Kelly, D.F. and Proudman, C.J. (2005):* *Gasterophilus pecorum* in the soft palate of a British pony. *Veterinary Record*, 156, 283-284.
- Williams, R.E. and Knapp, F.W. (1999):* Flies and external parasites of horses. Horse Industry Handbook: 415.5-415.6.
- Zumpt, F. (1965):* Myiasis of Man and Animals in the Old World, Butterworths, London.

تحديد الفرق بين انواع يرقات الجاستروفيليس في الحمير باستخدام الميكروسكوب الالكتروني

كريمة محمد البكري ، رضا سمير فضلي

Email: karembakry@yahoo.com , dr_redafadly@yahoo.com

في هذه الدراسة تم توضيح بعض الفروق التشريحية بين اربعة انواع من يرقات الجاستروفيليس (جاستروفيليس انتستيناليس وجاستروفيليس هيموريد اليس وجاستروفيليس نيزاليس وجاستروفيليس بيكروم) والتي تم الحصول عليها من معدة الحمير النافقة حديثا بمصر (محافظة الاسكندرية) وتم فحص هذه الانواع الاربعة لأول مرة في مصر حسب المراجع المتاحة بواسطة الميكروسكوب الالكتروني الماسح والتفريق بين قطاع رأسي والفك العلوي والاشواك الصدرية والبطنية والفك السفلي وشرائح البطن الطرفية ووجدت فروق واضحة بين الأنواع الاربعة خاصة في شكل الشعيرات الحساسة (السنسلا). هذه الصفات ممكن أن تساعد في التمييز بين أنواع يرقات الجاستروفيليس الأخرى. ركزت هذه الدراسة أيضا على توضيح الاختلافات بين الطور اليرقي الثاني والثالث من جاستروفيليس هيموريداليس وهذه الصفات قد تكون لها أهمية تقسيمية ومن المعروف أن يرقات جاستروفيليدي لها أهمية بيطرية وطبية، حيث وجدت البرقة في العديد من حالات التدويد الجلدي والعيني في الإنسان كما وجدت أيضا في حالة تدويد معوى. تم وضع بعض الارشادات الصحية للسادة مرببين الخيول والمتعاملين مع الفصائل الخيلية للحد من الاصابة بهذه اليرقات.