

Dept. of Vet. Sciences,
Fac. of Agronomic and Vet. Sciences,
Ibri Khaldoun University, Tiaret, Algeria.

**SOME MORPHOLOGIC INVESTIGATIONS
ON FEMALE GENITAL SYSTEM
(OVARY AND UTERUS) OF ALGERIAN GOATS**
(With 5 Tables and 3 Figures)

By

FATIMA BENCHAIIB and A. BENALLOU

(Received at 3/6/2007)

بعض الفحوص المورفولوجية على الجهاز التناسلي الأنثى (المبيض والرحم)
في الماعز الجزائرى

فاطيمة بن شعيب ، ابو عبد الله بن علو

تم فحص 117 جهاز تناسلى أنثى (المبيض والرحم) فى الماعز التى تتراوح اعمارها ما بين عام وثلاثة اعوام فى الفترة (2005- 2006) وقد تم جمع هذه العينات من المجازر الحكومية بولاية تيارت (الجزائر) وذلك لاستكشاف نسبة حركة المبيضين واهم التشوهات المرضية التى تصيبهما وكذلك مدى تأثيرها على خصوبة هذا النوع من الحيوانات. اظهرت الدراسة ان نشاط المبيضين يكاد يكون متقارب فى المبيض الايسر (49,60%) مقارنة بالمبيض الايمن (50,40%) وقدرت نسبة التشوهات الظاهرة فى المبيضين بحوالى 37,60% من مجموع العينات التى تم فحصها وكان اهمها الحويصلات الملتصقة بالمبيض (14,52%) وكذلك ضمور المبيض (10,26%). اما عن نسبة الحمل فكانت (20,51%) من مجموع العينات التى تم فحصها. وأشارت الدراسة إلى خصوبة هذا النوع من اناث الماعز الذى يجب ان نهتم بالتوسع فى تربيته لسد حاجيات الجزائر من اللحوم الحمراء والحليب ومشتقاته.

SUMMARY

In this survey one hundred seventeen female genital system (ovary & uterus) of goats ageing from one to three years old were collected from Tiaret abattoirs in the period of (2005-2006). The results showed that the left ovary was active as the right one and the percentages of follicles in both ovaries were 49.60% in the left and 50.40% in the right ovary. 37.60% of the examined specimens showed ovarian lesions on both ovaries. Para ovarian cyst was the most observed lesion (14.52%) followed by ovarian hypoplasia (10.26%) and follicular cyst (10.26%). The percentage of pregnancy was 20.51% from the total examined

specimens, 83.33% of them were single and 16.67% were twin pregnancies. These results, also gave some information on the fertility of Algerian goats. So, Algerian goat's raising can resolve the problem of milk and meat productions which are deficient in our country.

Key words: *Ovarian activity, ovarian lesions, pregnancy, Algerian goats*

INTRODUCTION

Goat's raising in Algeria is estimated to 3,5 millions which mainly used for the production of meat and milk in the Algerian Sahara only (Fida, 1993), because they are highly resistant to the climatic conditions and very fertile. Unfortunately, little information is available on the reproductive disorders especially in goat more than sheep or cattle. To increase goat's productivity, the improvement of the reproduction performances and the knowledge of their ovarian activity as well as genital lesions and the suitable treatments should put in our consideration (Thimonier, Chemineau and Gauthier, 1984). Therefore, this survey was undertaken for observing the ovarian activity and pregnancy in goat and detecting the ovarian lesions in case of gravid and non gravid uteri.

MATERIALS and METHODS

The material presented in this study consisted of one hundred seventeen genital organs (ovary and uterus) of Algerian slaughtered goats ageing from one to three years old. These organs were collected from Tiaret abattoirs during two years (2005-2006) and examined fresh within few hours after slaughtering at the laboratory. The ovaries were examined for their activities (number of follicles and corpora lutea). The lesions in each ovary were also observed. The distribution of Corpora lutea on the ovaries and presence of fetuses in the horns of the gravid uteri were recorded.

RESULTS

The results are presented in Tables 1-5 for the examined genital system (ovary and uterus). The ovarian activity was observed in both ovaries. The number of follicles in each ovary was 50.40% in the right and 49.60% in the left ovary which indicate that the ovarian activity was nearly similar in both ovaries (Table 1 & Fig.1). 20.52% were gravid with no genital lesions observed in these samples (Table 2).

Table 1: Ovarian activity

| | Distribution of the C.L | | Distribution of follicles | |
|-------------|-------------------------|----|---------------------------|-------|
| | No. /22 | % | No. /123 | % |
| Right ovary | 11 | 50 | 62 | 50.40 |
| Left ovary | 11 | 50 | 61 | 49.60 |

Table 2: Percentage of gravidity in the examined samples.

| | No. /117 | percentage |
|-------------------|----------|------------|
| Gravid uterus | 24 | 20.52 |
| Non gravid uterus | 93 | 79.48 |

The ovaries were examined macroscopically for detecting the follicular cysts and other lesions. This investigation showed that 37.60% of the total examined organs were represented by different macroscopic ovarian lesions (Table 3). Paraovarian cysts (14.52%), ovarian hypoplasia (10.26%) and follicular cysts (10.26%) were the most frequent ovarian lesions in the examined samples.

Table 3: Different ovarian lesions and their incidence.

| Lesions | Unilateral | | Bilateral | Total | N =117 % |
|--------------------|-------------|------------|-----------|-------|-------------|
| | Right No | Left No | | | |
| Para ovarian cyst | 04 | 05 | 08 | 17 | 14.52 |
| Ovarian hypoplasia | 07 | 03 | 02 | 12 | 10.26 |
| Follicular cyst | 00 | 03 | 09 | 12 | 10.26 |
| Ovarian adhesions | 00 | 03 | 00 | 03 | 02.56 |
| Total | 11 | 14 | 19 | 44 | 37.60 |

The paraovarian cysts were located in the mesovarium close to the ovary and they were very small in size (less than one cm in diameter). While, partial hypoplasia which the incidence in the present survey was (10.26%) affected the right and the left ovary in all examined cases.

The percentage of ovarian cysts was looked like ovarian hypoplasia (10.26%) and they were observed in both ovaries. Ovarian cysts were mostly single in both right & left ovaries. However, a multiple form could be demonstrated only in the left ovary in two cases. The cysts were about two cm in diameter, had a thicker wall and are pressured.

Regarding to the gravid uteri, 83.33% had a single fetus and 16.67% had twin fetuses. (Table 4 & Fig. 2).

Table 4: Incidence of pregnancy and occurrence of fetuses within the examined uteri.

| Pregnancies | No. of gravid uteri | | occurrence fetu | | Total |
|-------------|---------------------|---------|-----------------|-----------|-------|
| | No. / 24 | % | Right horn | Left horn | |
| Single | 20 | 83.33 % | 14 | 06 | 20 |
| Twin | 04 | 16.67 % | 04 | 04 | 08 |

In this survey, a total of thirty six corpora lutea (C.L) were noted in the ovaries of twenty four gravid uteri. Nineteen (52.77%) corpora lutea were in the right ovary and seventeen (47.22%) in the left ovary. While eighteen (64.29%) fetuses were located in the right horn and ten (35.71%) were in the left horn (Table 5 & Fig. 3).

Table 5: Distribution of the Corpora lutea (in the right or left ovary) according to the occurrence of fetuses within the examined uterus.

| | Fetuses | | Distribution of the C.L | | Total |
|------------|---------|-------|-------------------------|------------|-------|
| | No. | % | Right ovary | Left ovary | |
| Right horn | 18 | 64.29 | 14 | 07 | 21 |
| Left horn | 10 | 35.71 | 05 | 10 | 15 |
| Total | 28 | 100 | 19 | 17 | 36 |
| | | | 52,77% | 47,22 % | |

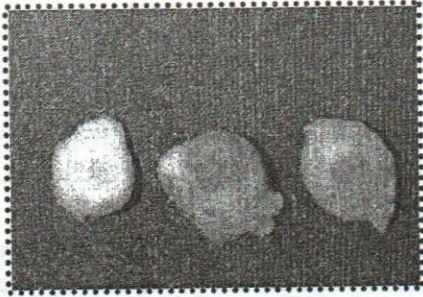


Fig. 1: Ovaries of goat. from the left to the right (corpus albicans, corpus luteum mature follicle).



Fig. 2: Gravid uterus.



Fig. 3: Incised uterus from a pregnant goat (Fetus located in the right horn)

DISCUSSION

The ovarian activity was observed in both ovaries. The number of follicles in each ovary was 50.40% in the right and 49.60% in the left ovary which indicate that the ovarian activity was nearly similar in both ovaries. 20.52% were gravid with no genital lesions observed in these samples. This result is in agreement with that of (Lyngset, 1968; Smith, 1980; Camp, Wildt, Howards, Stuartand and Chakraboty, 1983).

The paraovarian cysts were located in the mesovarium close to the ovary and they were very small in size (less than one cm in diameter). They may reach several centimetres in diameter and can be confused with the true ovarian cysts (Mc Entee and Kenneth, 1990). Such cysts may originate from remnants of either mesonephric or paramesonephric tubules or ducts (Jubb, 1990).

Many authors have reported different incidences of paraovarian cyst in cattle, sheep and goats and noted that this type of cysts around the ovary and in the mesosalpinx did not interfere with gravidity in these species, (Al dahash and Alwan, 1989; Hatipuglu, Kiran, Ortatatli, Erer and Ciftci, 2002).

While, partial hypoplasia which the incidence in the present survey was (10.26%) affected the right and the left ovary in all examined cases. The ovarian hypoplasia was usually bilateral but varies considerably in its severity and symmetry. Therefore, severe hypoplasia or partial hypoplasia may be applicable to one or both ovaries (Jubb, 1990).

The ovarian stroma was deficient although a few primary follicles were observed. In association with ovarian hypoplasia, there was a relative hypoplasia of the remainder of the genital tract. Ovarian hypoplasia was seen only in spring season. It occurs sometimes after passing from wintry alimentation to pasture, (Hanzen, 2005).

Timurkaan and Karadas (2000) have reported 0.10% of ovarian hypoplasia in ordinary slaughtered Turkey goats. This incidence is lower than that reported in this study. Hypoplasia is due to cell germ deficiency in domestic mammals. It can be observed in different breeds but it is frequently observed in cattle, (Lagerlöf and Settergen, 1961; Settergen, 1964).

The percentage of ovarian cysts was looked like ovarian hypoplasia (10.26%) and they were observed in both ovaries. On the other hand, anovulatory ovarian cysts could apparently occur in all species although they are important cause of reproductive failure only in cattle and swine, (Jubb, 1990). Macroscopic findings of ovarian cysts in goats are similar to that reported by Grant (1934) in ewes and Lyngset (1968) in goats.

Regarding to the gravid uteri, 83.33% had a single fetus and 16.67% had twin fetuses. In this survey, a total of thirty six corpora lutea (C.L) were noted in the ovaries of twenty four gravid uteri. Nineteen (52.77%) corpora lutea were in the right ovary and seventeen (47.22%) in the left ovary. While eighteen (64.29%) fetuses were located in the right horn and ten (35.71%) were in the left horn.

In conclusion, the present study confirms the high fertility of Algerian goats. So goat's raising should be carried out in different areas in our country in order to increase the meat and milk productions which are deficient in Algéria.

REFERENCES

- Aldahash, S.Y. and Alwan, A.F. (1989):* Gross abnormalities affecting genital tracts of Iraqi ewes. Department of surgery and obstetrics, College of veterinary medicine, university of mosul, Iraq. (personal communication)

- Camp, J.C.; Wildt, D.E.; Howards, P.K.; Stuartand, L.D. and Chakraborty, P.K. (1983):* Ovarian activity during normal and abnormal length oestrous cycles in the goat. *Biol.Reprod*, 28:673-681.
- FAO/FIDA (1993):* Projet de développement des monts de Béni-Chougrane: Etude de diagnostic des systèmes. FAO, 96 p.
- Grant, F. (1934):* Studies on the physiology of reproduction in ewe. Part III. Gross changes in the ovaries. *Trans.R.Soc.Edinburgh* 58: 36-47.
- Hanzen, C.H. (2005):* Les kystes ovariens dans l'espèce bovine. Cours de 2ème Doctorat Faculté de Médecine Vétérinaire. Service d'obstétrique et de pathologie de la reproduction des ruminants, équidés et porcs. Université de Liège, Belgique.
- Hatipuglu, F.; Kiran, M.M.; Ortatatli, M.; Erer, H. and Ciftçi, M.K. (2002):* An abattoir study of genital pathology in cows: Ovary and oviduct. *Revue Méd. Vet.*, 153: 29-33.
- Jubb, K.V.F. (1990):* Pathology of domestic animals; 3rd Ed., Vol. 3, Academic Press Inc, New York.
- Lagerlöf, N. and Settergren, I. (1961):* Gonadenhypoplasia beim Rind der schwe-dischen Gebirgsrasse: Zuchthygiene 5: 141-158.
- Lyngset, O. (1968):* Studies on reproduction in the goat. III. The functional activity of the ovaries of the goat. *Acta Vet. Scand.*, 9: 268-276.
- Mc Entee and Kenneth (1990):* Reproductive pathology of domestic mammals. Academic press, INC, San Diego-California 92101.
- Settergren, I. (1964):* The ovarian morphology in clinical bovine gonadal hypoplasia with some aspects of its endocrine relations *Acta. Vet. Scand.*, 5:1-108.
- Smith, M.C. (1980):* Caprine reproduction. In "current therapy in theriogenology" (Morrow, D.A. Ed.), pp.982-983. Saunders, Philadelphia.
- Thimonier, J.; Chemineau, P. and Gauthier, D. (1984):* Increase fertility of ruminants in tropical areas: A reality. In: Chemineau, P.; Gauthier, D. and Thimonier, J. (Ed), *Reproduction des ruminants en zone tropicale*, 399-418. INRA. Paris.
- Timurkaan, N. and Karadas, E. (2000):* Morphologic investigations on pathological changes of the female reproductive organs in goats: I .Ovarium and oviduct. *F.Ü.Sag. Bil. Derg.* 14.